

Use of a slow-release GnRH implant in an adult billy goat

Einsatz eines slow-release GnRH-Implantates bei einem adulten Ziegenbock



Authors

Lukas Demattio¹, Daniela Fietz², Gerhard Schuler¹, Axel Wehrend¹

Affiliations

- 1 Veterinary Clinic for Reproductive Medicine and Neonatology, Justus-Liebig-University Giessen, Germany
- 2 Institute of Veterinary Anatomy, Histology and Embryology, Justus Liebig University Giessen, Germany

Keywords

Billy goat, contraception, deslorelin, sexual behavior

Schlüsselwörter

Ziegenbock, Kontrazeption, Deslorelin, Sexualverhalten

received 06.08.2023

accepted 01.11.2023

Bibliography

Tierarztl Prax Ausg G Grosstiere Nutztiere 2024; 52: 235–238

DOI 10.1055/a-2289-5640

ISSN 1434-1220

© 2024. The Author(s).

This is an open access article published by Thieme under the terms of the Creative Commons Attribution-NonDerivative-NonCommercial-License, permitting copying and reproduction so long as the original work is given appropriate credit. Contents may not be used for commercial purposes, or adapted, remixed, transformed or built upon. (<https://creativecommons.org/licenses/by-nc-nd/4.0/>).

Georg Thieme Verlag KG, Rüdigerstraße 14,
70469 Stuttgart, Germany

Correspondence

Lukas Demattio

Veterinary Clinic for Reproductive Medicine and Neonatology

Faculty of Veterinary Medicine

Justus Liebig University Giessen

35392 Giessen

Germany

lukas.s.demattio@vetmed.uni-giessen.de

ABSTRACT

A 9.4 mg deslorelin slow-release implant was inserted into an adult, healthy billy goat to achieve temporary infertility and a reduction in sexual behavior. The implant was inserted in late autumn. No significant change in testis size was observed over the following 6 weeks. The endocrine function of the testis, which was examined by stimulation with human chorionic gonadotropin, was also unchanged after 6 weeks compared to the initial examination. Histological examination revealed a preserved spermatogenesis.

In conclusion, the application of a GnRH analogue implant in the adult male goat has no influence on the investigated parameters – and thus probably also on its fertility.

ZUSAMMENFASSUNG

Ein 9,4 mg slow-release Deslorelin-Implantat wurde einem adulten, gesunden Ziegenbock eingesetzt, um eine vorübergehende Unfruchtbarkeit und eine Verringerung des Sexualverhaltens zu erreichen. Das Implantat wurde im Spätherbst eingesetzt. In den folgenden 6 Wochen wurde keine signifikante Veränderung der Hodengröße beobachtet. Auch die endokrine Funktion des Hodens, die durch Stimulation mit humanem Choriongonadotropin untersucht wurde, war nach 6 Wochen im Vergleich zur Ausgangsuntersuchung unverändert. Die histologische Untersuchung ergab eine erhaltene Spermatogenese.

Zusammenfassend lässt sich sagen, dass die Anwendung eines GnRH-Analagon-Implantats beim erwachsenen Ziegenbock keinen Einfluss auf die untersuchten Parameter – und damit wahrscheinlich auch nicht auf seine Fruchtbarkeit – hat.

Introduction

There are virtually no alternatives to surgical castration for the adult goat and therefore no approved drugs suitable for reversible suppression of reproduction. Nevertheless, this is often requested, especially in the hobby husbandry of these animals. A possible approach to close this therapy gap is the use of a vaccine against GnRH. However, this must be administered at least twice to have a sufficient effect and it remains uncertain how long the effect will last. In rams, it is known that strong local reactions and irritations can occur after the application of a vaccine against GnRH [1]. This is considerable deficit under an animal welfare point of view.

Another possibility is the application of a GnRH implant.

These are slow-release implants, which, after being implanted subcutaneously, release their active substance into the organism for a longer period of time. In particular, they are used in small animals and pets [2, 3].

The effect of the implant is based on an intervention in the neuroendocrine control of reproductive function. The release of GnRH analogues leads to desensitization and downregulation of GnRH receptors on the pituitary gland after initial stimulation of FSH and LH release. Synthetic GnRH analogues have a significantly longer half-life and up to 7 times higher receptor affinity compared to natural GnRH [3].

In EU, the preparation Suprelorin (Virbac AG) is available. Suprelorin contains the active ingredient deslorelin-acetate and is available in 2 different dosages: 4.7 mg and 9.4 mg. This preparation is approved for the achievement of temporary infertility in non-castrated, sexually mature male dogs and ferrets [4].

Suprelorin is also used in other animal species, apart from dogs and ferrets, with the same indication. Studies on efficacy and inefficiency are available for example for the male rabbit [5], the male and female cats [3, 6] and the boar [7]. The effect of GnRH analogue implants has also been investigated for ruminants. Data are already available for the use of GnRH implants in juvenile rams [8]. It was possible to show that onset of puberty is postponed in treated animals, and also growth is retarded compared to untreated animals in the same environment. For adult male goats, there have been no studies with corresponding implants so far.

This case report deals with the effect of deslorelin used as a slow-release-implant in an adult, healthy, male goat, which was treated with such an implant. After working up this case it was the aim to answer the following question: Does the implantation of a suprelorin implant in the adult male goat have an effect on endocrine testicular function (production of testosterone), on the size of the testis or on spermatogenesis at the histological level?

Case presentation

A 3-year-old, clinically healthy goat of the breed Weiße Deutsche Edelziege was implanted with a Suprelorin chip (9.4 mg) in late autumn subcutaneously on the lateral chest wall. The examined buck was previously kept together with another uncastrated buck. While one of the animals should be used as a breeding buck, the other had to be castrated in order to be kept together with his conspecific. The second buck was used as a control reference to exclude environmental influences. Therefore, he was clinically examined and observed with special regard to his sexual behavior. To check the

effect of the implant, a stimulation test with 600 IU human chorionic gonadotropin (hCG), administered intravenously, was performed before implantation, as well as 6 weeks afterwards. Samples were taken at 30, 60 and 90 minutes after the hCG injection [9]. The samples were measured by radioimmunoassay [10]. In addition, both testicles of the buck were measured weekly in 3 spatial directions using a testimeter. As there was still no perceptible effect after 6 weeks, the buck was surgically castrated. A sample from the testicles was examined histologically for changes in spermiogenesis. For this purpose, the tissue was fixed with 10% formalin and embedded in paraffin wax. Subsequently, 5 µm thick paraffin sections were cut and stained using hematoxylin and eosin. Histological analysis was performed at a primary magnification of x40 by counting approx. 400 tubular cross-sections according to França et al. [11]. Implantation, stimulation tests and measurement of the testes took place in spring. All samples were taken for routine diagnostic procedures, to check the effect of the implant and conform to animal welfare regulations according to the file number KTV/8-2017 given by the Regierungspräsidium Gießen (regional council of Giessen), Germany.

Physical and Laboratory evaluation

Results of the testicular measurements and hCG stimulation tests

Measurement of the testes (► **Table 1**) showed no change in testis size.

No differences were found in the hCG stimulation tests (► **Fig. 1**).

Histological evaluation of the testis

Spermatogenesis in the buck can be subdivided into 8 spermatogenic stages [11]. 451 randomly chosen seminiferous tubules sections were examined regarding their spermatogenic stage. 10.4% of tubules showed stage VIII with elongated spermatids at the verge of sperm release (► **Fig. 2**). Compared to the percentage of stage VIII shown by França et al. [11] ($11.7 \pm 0.6\%$), kinetics of spermatogenesis is preserved in this subject. A complete distribution of spermatogenic stages can be taken from ► **Table 2**. An example for testicular histology can be taken from ► **Fig. 2**.

Further observations

No behavioral changes were detected in the buck. The billy goat still exhibited sexual behaviors such as urine drinking, flehming, masturbating, and jumping up on the companion animal stalled with it.

The control-buck did also show no behavioral or clinical changes during the investigated period. There was no irritation or inflammation at implantation-side.

Diagnosis

None of the tested parameters was affected by the administered slow-release deslorelin.

Treatment

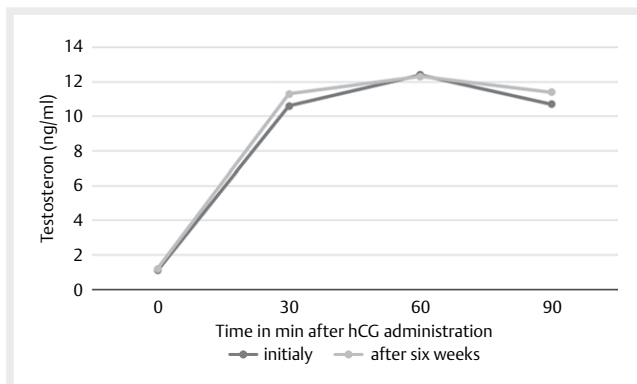
After the medical therapy was not successful, a surgical castration was performed. Thus, the goal of suppression of reproduction was achieved.

► **Table 1** Measurements of the testicles in centimeter.

► **Tab. 1** Maße der Hoden in Zentimetern.

Time Point	Left testicle			Right testicle		
	Length	Width	Height	Length	Width	Height
Initially	14.4	6.5	4.4	15.1	6.3	4.1
After 1 week	14.5	6.6	4.3	15.2	6.5	4.1
After 2 weeks	14.6	6.7	4.4	15.4	6.5	4.4
After 3 weeks	13.8	6.3	4.3	15.1	6.4	4.3
After 4 weeks	14.1	6.4	4.2	15.0	6.4	4.3
After 5 weeks	14.0	6.3	4.3	14.9	6.5	4.2
After 6 weeks	13.8	6.4	4.2	15.0	6.6	4.1

[Tabellenfußzeile – bitte überschreiben]



► **Fig. 1** Results of the hCG stimulation test, before and 6 weeks after the implantation of Suprelorin implant, following administration of 600 IU of hCG. Source: L. Demattio.

► **Abb. 1** Ergebnisse der hCG-Stimulationstest, vor und 6 Wochen nach dem Einsetzen eines Suprelorin-Implantates, nach Verabreichung von 600 IE hCG. Quelle: L. Demattio.

Follow up

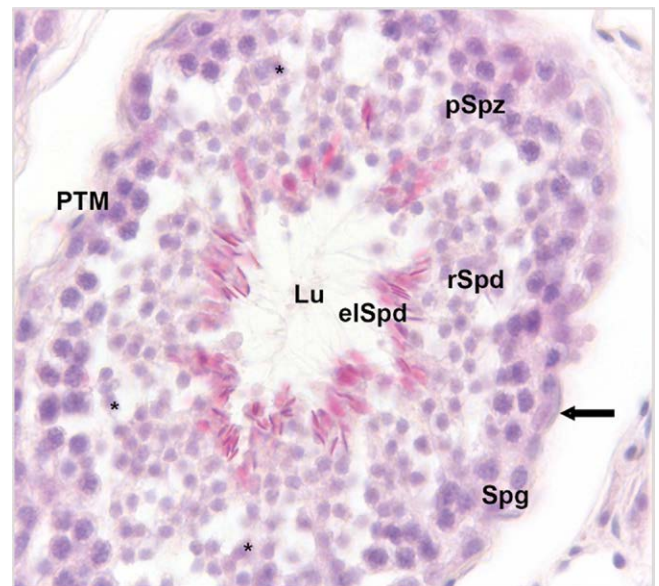
The operation was performed successfully, the billy goat showed a positive development and was successfully kept together with female conspecifics after the wound had healed and after a waiting period of 6 weeks after surgery.

Discussion

A reversible method of reproductive suppression for billy goats would be desirable to avoid surgery and improve breeding planning without having to isolate mature bucks.

In contrast to what is described for immature rams [8], it was not possible to detect any effect of the deslorelin implant.

To check the endocrine testicular function, an hCG stimulation test was carried out at the beginning and at the end of the investi-



► **Fig. 2** Histological evaluation of testis morphology (HE staining, primary magnification x40). As an example, spermatogenic stage VIII [11] is shown here; in this stage, A and B spermatogonia (Spg), pachytene spermatocytes (pSpz), round spermatids (rSpd) and elongated spermatids (elSpd) shortly before sperm release are present. Seminiferous tubules are lined by the tubular wall (arrow) which contain peritubular myoid cells (PTM). Lu = Lumen; somatic Sertoli cells (*). Source: D. Fietz.

► **Abb. 2** Histologische Beurteilung der Hodenmorphologie (HE-Färbung, primäre Vergrößerung x40). Als Beispiel wird hier das spermatogene Stadium VIII [11] gezeigt; in diesem Stadium sind A- und B-Spermatogonien (Spg), pachytene Spermatozyten (pSpz), runde Spermatiden (rSpd) und elongierte Spermatiden (elSpd) kurz vor der Spermienfreigabe vorhanden. Die Tubuli seminiferi sind von der Tubuluswand (Pfeil) ausgekleidet, die peritubuläre Myoizellen (PTM) enthält. Lu = Lumen; somatische Sertoli-Zellen (*). Quelle: D. Fietz.

► **Table 2** Proportional distribution of spermatogenic stages.► **Tab. 2** Anteilige Verteilung der Spermatogenesestadien.

Spermato-genic stage	No. seminifer-ous tubules (out of 451)	Percent-age	Normal distribution of stages (França et al. 1999 [11])
I	123	27.2%	15.8±1.0%
II	43	9.5%	12.8±0.5%
III	106	23.5%	20.5±0.9%
IV	13	2.9%	10.7±0.7%
V	40	8.9%	11.6±0.6%
VI	30	6.7%	9.3±1.1%
VII	49	10.9%	7.6±0.4%
VIII	47	10.4%	11.7±0.6%

gated period. Studies in dogs showed that if the implant is fully effective, the production of testosterone ceases [12]. As the testosterone concentrations measured in connection with the hCG stimulation test before and after the implantation phase did not differ, a suppressive effect of the deslorelin preparation on testicular steroidogenesis could not be demonstrated.

The measurement of the testicles showed no statistically significant reduction in the size of both testicles, as it is shown for example in the dog and tom cat [3, 13].

The histological examination of the testicular tissue showed that spermatogenesis does not seem to be affected by the implantation of a slow-release deslorelin implant as it was shown for the dog [14]. By means of the methods performed, it was found that the implantation of a suprelorin implant in the adult goat had no effect on fertility.

What are possible reasons, that caused the chip not to work? An error during implantation can be ruled out, the correct seating of the implant could be traced during the entire period examined.

There were no indications of encapsulation of the implant. The implant was felt in the same way during the entire period, no thickening around it could be detected.

It is possible that the selected dose is too low. The preparation with the highest commercially available dosage was chosen. Targeted studies would be necessary to verify the effect of a higher dosage. Perhaps the active ingredient does not interact sufficiently with the goat GnRH receptor and another GnRH analogue would have a better effect.

Another potential reason for the lack of effect is a too rapid metabolization; no robust data are available on this for the goat to date. The lack of effect of a slow-release deslorelin implant is also known for other animal species such as the rabbit or the guinea pig; the reason has not been clearly proven.

The limitations of this study are mainly the small number of animals examined ($n = 1$), an individual therapy failure cannot be excluded, further investigations are necessary to make a reliable statement.

CONCLUSION FOR PRACTICE

The evaluation of our case report shows that the implant had no effect on the sexual behavior or spermatogenesis of an adult billy goat. Although it would be a welcome alternative to surgical castration, due to the probable lack of effect, its use under the conditions mentioned must be critically questioned and, if a decision is made to use it, the success of the treatment must be critically reviewed.

Conflict of interest

The authors declare no conflict of interest.

Dedication

We dedicate this article to Prof. Karl Nuss on the occasion of his retirement from university activities.

References

- [1] Meeusen E, Walker J, Peters A et al. Current Status of Veterinary Vaccines. *ASM*. 2012; 20: 489–510
- [2] Lucas X. Clinical Use of Deslorelin (GnRH agonist) in Companion Animals: A Review. *Reprod Domest Anim* 2014; 49: 64–71
- [3] Goericke-Pesch S. Reproduction Control in Cats new developments in non-surgical methods. *J Feline Med Surg* 2010; 12: 539–546
- [4] Stempel S, Goericke-Pesch S. GnRH agonist implants in small animal practice - what do we know 13 years following EU registration? *Tierärztl Prax K/H* 2020; 6: 420–432
- [5] Goericke-Pesch S, Groeger G, Wehrend A. The effects of a slow-release GnRH agonist implant on male rabbits. *Anim Reprod Sci* 2015; 152: 83–89
- [6] Fontaine C. Long-term contraception in a small implant: A review of Suprelorin (deslorelin) studies in cats. *J Feline Med Surg* 2015; 17: 766–771
- [7] Kauffold J, Rohrmann H, Boehm J et al. Effects of long-term treatment with the GnRH agonist deslorelin (Suprelorin®) on sexual function in boars. *Theriogenology* 2010; 74: 733–740
- [8] Tilbrook J, Galloway D, Williams A et al. Treatment of young rams with an agonist of GnRH delays reproductive development. *Horm Behav* 1993; 27: 5–28
- [9] Bader H. Diagnostik endokriner Fertilitätsstörungen. In: Busch W und Holzmann A, Hrsg. *Veterinärmedizinische Andrologie: Physiologie und Pathologie der Fortpflanzung bei männlichen Tieren*. 1. Auflage. Stuttgart: 2001: 396–398
- [10] Hoffmann B, Landeck A. Testicular endocrine function, seasonality and semen quality of the stallion. *Anim Reprod Sci* 1999; 57: 89–98
- [11] França L, Becker-Silva S, Chiarini-Garcia H. The length of the cycle of seminiferous epithelium in goats (*Capra hircus*). *Tissue & Cell* 1999; 3: 274–280
- [12] Driancourt M, Briggs J, Briggs J. Gonadotropin-Releasing Hormone (GnRH) Agonist Implants for Male Dog Fertility Suppression: A Review of Mode of Action, Efficacy, Safety, and Uses. *Front Vet Sci* 2020; 7: 1–11
- [13] Junaidi A, Williamson P, Trigg T et al. Morphological Study of the Effects of the GnRH Superagonist Deslorelin on the Canine Testis and Prostate Gland. *Reprod Domest Anim* 2009; 763: 757–763
- [14] Goericke-Pesch S, Spang A, Schulz M et al. Recrudescence of Spermatogenesis in the Dog Following Downregulation Using a Slow-Release GnRH Agonist Implant. *Reprod Domest Anim* 2009; 44: 302–308