Accepted Manuscript online: 2024-04-02 Article published online: 2024-04-23

Minimally-Invasive Approach in the Setting of a Malignant Primary Cardiac Tumor

Emre Polat[1] Sina Stock[1] Tamer Owais[1] Evaldas Girdauskas[1]

[1] Department of Cardiothoracic Surgery, University Hospital Augsburg, Augsburg, Bayern, Germany

Thorac Cardiovasc Surg Rep 2024;13:e16–e19.

Address for correspondence Emre Polat, MD, Department of Cardiothoracic Surgery, University Hospital Augsburg, Stenglin Street 2, 86156 Augsburg, Bayern, Germany (e-mail: emre.polat@uk-augsburg.de).

Abstract

A 71-year-old man with dilated cardiomyopathy without clinical complaints revealed a suspicious finding in checkup. After a multimodality cardiac imaging, the suspicion of a malignant primary cardiac tumor in the left ventricle was substantiated and the patient underwent minimally-invasive cardiac surgery for tumor resection. Postoperative chemotherapy with multiple cycles of liposomal doxorubicin was established and supported by proton beam radiotherapy. Two-year follow-up revealed no disease recurrence.

Keywords
- minimally-invasive surgery
- mini-thoracotomy
- sarcoma
- cardiovascular surgery

Introduction

Undifferentiated high-grade pleomorphic cardiac sarcomas (also named as malignant fibrous histiocytomas) are the second most common type of primary malignant cardiac sarcomas and in general widely known to be associated with a poor prognosis owing to rapidly size progression, aggressive invasion, and high recurrence rate after surgical resection.[1] The early detection of the sarcoma mass is critical for planning the best surgical approach, and thus the proposal to combine surgery and histologic evaluation is a relevant strategy for planning the best treatment of undifferentiated pleomorphic cardiac sarcoma (UPSC).

Case Description

A 71-year-old man with known dilated cardiomyopathy and left ventricular ejection fraction of 40% without any clinical complaints (New York Heart Association I [NYHA I]) revealed an incidentally suspicious finding in annual cardiovascular checkup. At current state on physical examination, he was afebrile, blood pressure was 117/79 mm Hg, heart rate was 81 beats/min, respiratory rate was 13 breaths/min with oxygen saturation 97% without the need for additional oxygen supplementation. Chest radiograph did not show pulmonary venous congestion or infiltrates. An electrocardiogram showed sinus rhythm without higher-degree blockages. Transthoracic echocardiography showed a 2.8 × 3cm discrete echo dense mass in the moderately dilated left ventricle with defined margins that are distinct from the endocardium. Due to clinical suspicion of an apical left ventricular thrombus, an oral anticoagulation therapy with edoxaban was initiated and a follow-up echocardiography after 3 months was rescheduled.

Investigations

After 3 months, the patient developed progressive dyspnea on exertion with NYHA class III and presented to our emergency department. At follow-up echocardiography, serious progression of the left ventricle mass was revealed (5.9 × 4.5cm) despite anticoagulation therapy (►**Fig. 1A**). Computed tomographic angiography revealed a sessile mass with deep invasion of the myocardium and ruled out extracardiac tumors (►**Fig. 2B**).

received
January 3, 2024
accepted after revision
March 4, 2024
accepted manuscript online
April 2, 2024

DOI https://doi.org/10.1055/a-2298-0497.
ISSN 2194-7635.

© 2024. The Author(s).
This is an open access article published by Thieme under the terms of the Creative Commons Attribution-NonDerivative-NonCommercial-License, permitting copying and reproduction so long as the original work is given appropriate credit. Contents may not be used for commercial purposes, or adapted, remixed, transformed or built upon. (https://creativecommons.org/licenses/by-nc-nd/4.0/)
Georg Thieme Verlag KG, Rüdigerstraße 14, 70469 Stuttgart, Germany

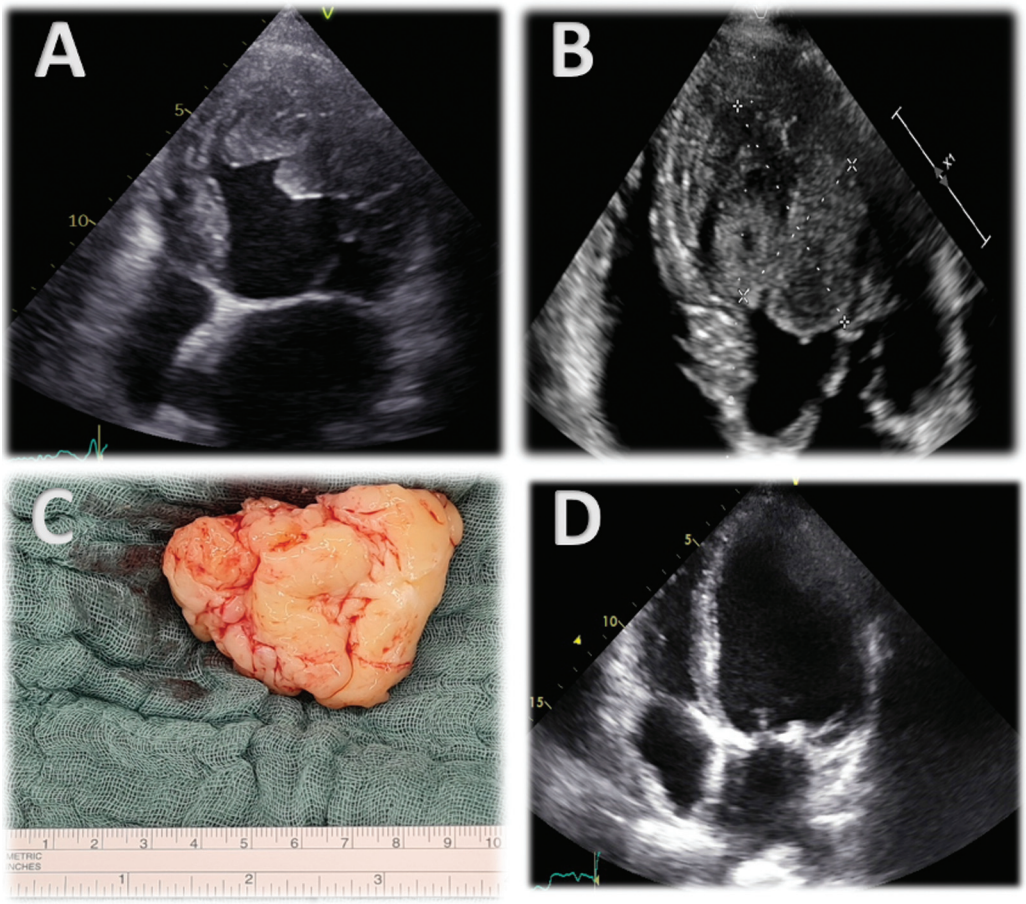

Fig. 1 (A) Apical three-chamber view of transthoracic echocardiography at initial cardiovascular checkup with a suspicious 28 × 30mm echo dense mass in the left ventricle. (B) Cropped apical four-chamber view of transthoracic echocardiography 3 months later, showing inhomogeneous left ventricular apical mass (59 × 45 mm diameter), almost adherent to the mitral ring and irregular borders, occupying most of the ventricular cavity. (C) Intraoperative photograph after en-bloc resection of a huge whitish yellow tumor mass out of the left ventricle. (D) Apical four-chamber view of transthoracic echocardiography 2 years after minimally-invasive extraction of the sarcoma showing no recurrence or rather progression.

Abnormal vascularization of the tumor mass in the left ventricle could be ruled out by contrast echocardiography and diagnostic coronary angiography. The positron emission tomography scan detected elevated fluorodeoxyglucose uptake of the tumor mass, which is strongly suspicious for malignancy. Cardiac magnetic resonance imaging demonstrated irregular borders of the tumor without infiltration of the adjacent myocardial wall (►**Fig. 2A** and **C**).

After a multimodality cardiac imaging, the suspicion of a primary cardiac tumor in the left ventricle was substantiated and the patient was prepared for minimally-invasive cardiac surgery for tumor resection.

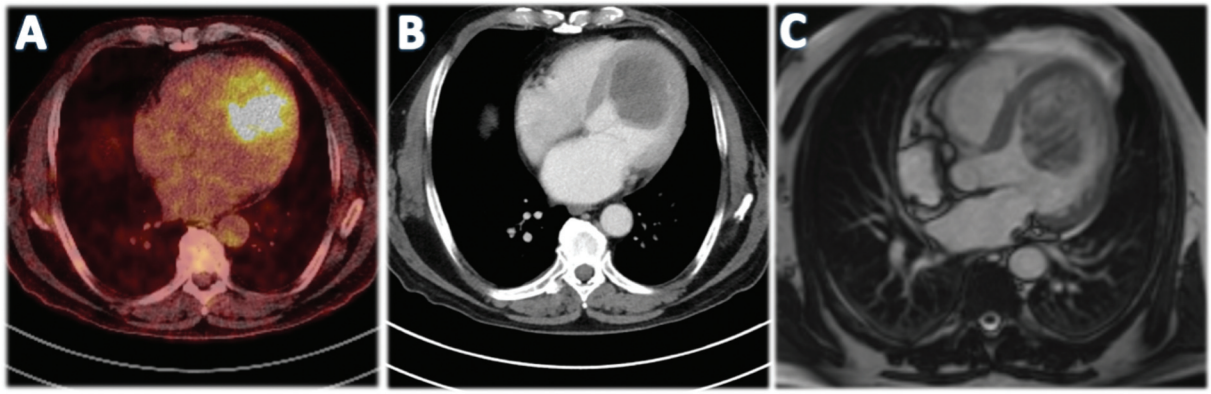

Fig. 2 (A) Giant left ventricular mass on fluorodeoxyglucose positron emission tomography. (B) Cardiac computed tomography, axial reconstruction of the sarcoma in the left ventricular apex through the mitral valve. (C) Cardiac magnetic resonance imaging demonstrated irregular borders of the tumor mass.

Operative Management

The patient was positioned supine with the right hemithorax tilted up to 30 degrees. A right anterolateral mini-thoracotomy was performed through a 4 to 5 cm periareolar incision. Another port in the fourth intercostal space midaxillary line was used for the insertion of three-dimensional (3D) endoscope. Percutaneous femoral cannulation for extracorporeal circulation was performed by transesophageal guidance. Body temperature was maintained at around 34°C. A third port in the second right intercostal space in the anterior axillary line was used for cross-clamping the ascending aorta and antegrade del Nido cardioplegia was delivered directly into the aortic root.

After a left atrial incision, the inspection of left ventricular cavity revealed a huge whitish yellow tumor mass with nearly occluding the entire cavum and affecting the papillary muscles that made a mitral valve replacement mandatory. After resection of the anterior mitral leaflet and both papillary muscles, the broad base tumor was peeled off en-bloc thoroughly from the anteroapical wall and placed safely in a bag to prevent the seeding of highly malignant cells into the thoracic cavity, as best as possible (►**Fig. 1B**). Because intraoperatively frozen section analyses revealed undifferentiated pleomorphic cardiac sarcoma, we strived copiously for achieving a R0-resection. Then, a straightforward, biological mitral valve replacement was performed. Additionally, we implemented a spine plane block to provide effective pain relief while minimizing opioid use during the perioperative period.

In accordance with our enhanced recovery after surgery program, the hemodynamically stable patient was then extubated in the operating room and transferred to intensive care unit for one night and discharge at home after 5 days without any perioperative events. Postoperative chemotherapy by multiple cycles of liposomal doxorubicin was established and further supported by protracted proton beam radiotherapy. At 2-year follow-up, no tumor recurrence could be revealed at multimodal imaging studies (►**Fig. 1C**).

Discussion

Primary cardiac neoplasms, especially undifferentiated high-grade pleomorphic cardiac sarcomas, are extremely rare and accompanied with an unfavorable prognosis owing to their aggressive biological behavior and poor overall survival.[1,2] An early diagnosis and a definition of individualized treatment concept are required to improve the prognosis of patients with primary cardiac tumors. Furthermore, histological differentiation is the key to provide insights into prognosis and survival of these patients. Characteristically, the cytology reveals heterogeneous neoplasms with various plump spindle lesions and giant features, which make the definite diagnosis difficult.[3]

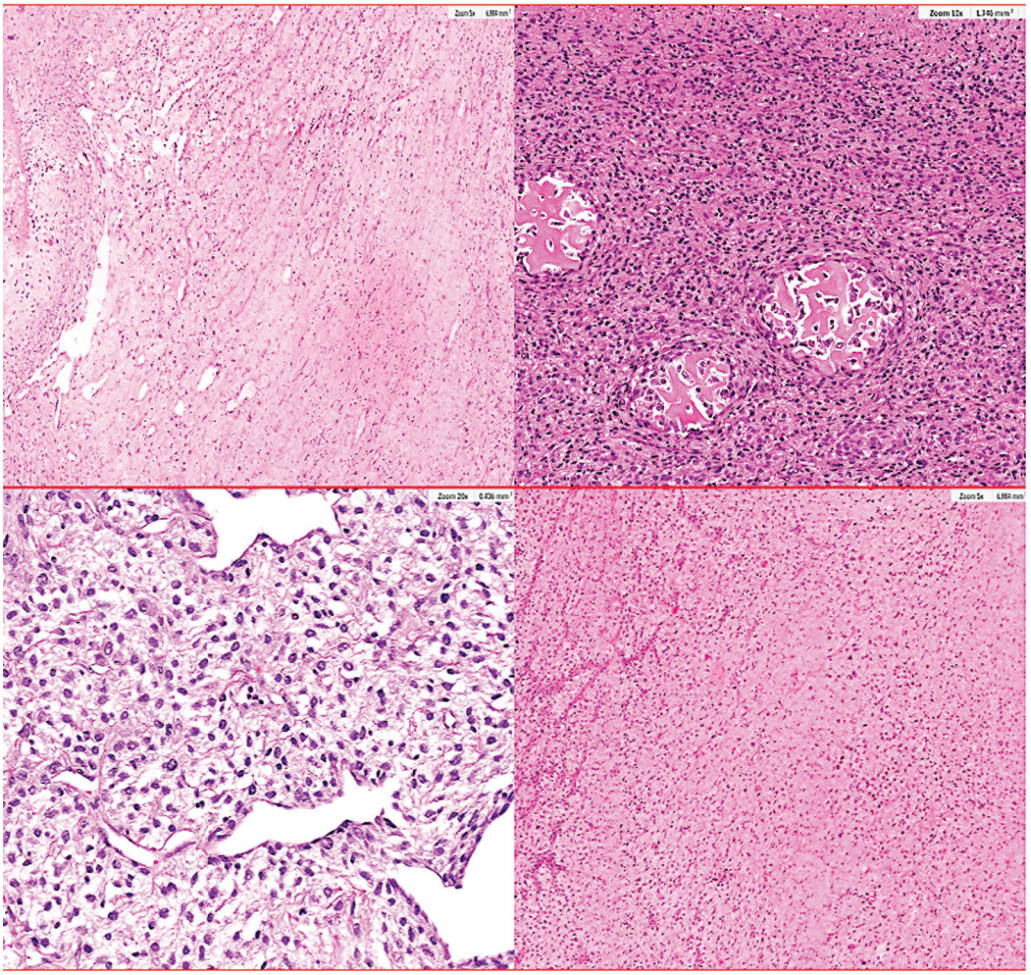

Fig. 3 Hematoxylin and eosin staining displayed atypical spindle shaped tumor cells with cartilage formation and ossification (x 5–x 20).

Such cells often display frequent mitotic activity and nuclear polymorphism, while others undergo late programmed cell death like apoptosis (►**Fig. 3**).[4]

Cardiac surgery aimed at radical resection is the cornerstone of the treatment.[5] Instead of the old-fashioned median sternotomy or ventriculotomy, the minimally-invasive surgery is increasingly moving to the fore in cardiac surgery and cardiac tumors are no exception, considering all the advantages like less trauma and pain, less blood loss, less wound infection, shorter rehabilitations, and especially way easier redo-surgeries in case of tumor recurrence. Furthermore, in terms of tumor clearance, minimally-invasive techniques with 3D endoscopes provide better visualization of the intracardiac structures that result in more specific excision, which in turn can be crucial for the life expectancy of the patient. If the tumor location is suitable for a minimally-invasive approach, it should be the preferred method of access. However, certain other locations might not allow for thorough removal of a ventricular lesion. For experienced minimal-invasive surgeons, the access and exposure of subvalvular apparatus in cardiac tumor surgeries is a straightforward procedure, despite the rarity of these tumors.[6]

Conclusion

Primary cardiac sarcomas are neoplasms with a dismal prognosis due to their aggressive biological nature, their primary localization, and the difficulty in achieving complete surgical and pharmacological eradication. Surgery remains the gold standard technique, above all when succeeding in removing cancer cells even from the margins of the lesion. In fact, despite innovative surgical techniques and achievements of modern chemo-/radiotherapies, the survival of these patients is still poor, for what reason minimally-invasive surgical techniques with reduced trauma and way easier redo-surgeries play an important role.

Ethical Approval

Approval of the study by the Ethics Committee of on July the 28th, 2023 (ID number 23–0656) and written patient informed consent were obtained.

Funding

None.

Conflict of Interest

None declared.

References

1 Rahouma M, Arisha MJ, Elmously A, et al. Cardiac tumors prevalence and mortality: a systematic review and meta-analysis. Int J Surg 2020;76:178–189
2 Rahouma M, Baudo M, Shmushkevich S, et al. Sex differences in primary malignant cardiac tumors: a multi-institutional cohort study from National Cancer Database. J Card Surg 2022;37(05): 1275–1286
3 Scicchitano P, Sergi MC, Cameli M, et al. Primary soft tissue sarcoma of the heart: an emerging chapter in cardio-oncology. Biomedicines 2021;9(07):774
4 Tyebally S, Chen D, Bhattacharyya S, et al. Cardiac tumors: *JACC CardioOncology* state-of-the-art review. JACC Cardiooncol 2020;2 (02):293–311
5 Krishnan T, Pettersson G, Mukherjee R, Singhal N. Cardiac angiosarcoma: a diagnostic and therapeutic challenge. J Cardiol Cases 2020;22(02):90–93
6 Zacharias J. Endoscopic Cardiac Surgery – Tips, Tricks and Traps. New York City, Springer; 2023:237–243