

Peroral endoscopic mediastinal tunneling myotomy for esophageal achalasia: the first case treated in mediastinal tunnel



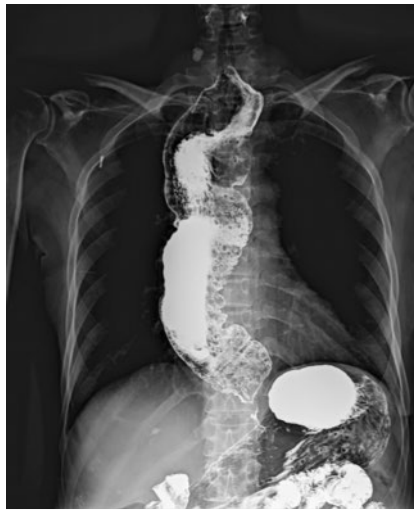Peroral endoscopic myotomy (POEM) has been accepted as an effective and safe therapeutic strategy for esophageal achalasia [1]. However, the submucosal tunnel cannot be established in some patients because of severe fibrosis caused by previous treatment [2].

A 68-year-old woman was admitted due to a 30-year history of progressive dysphagia and regurgitation. She was diagnosed with esophageal achalasia and had previously undergone two pneumatic balloon dilations, without significant improvement in symptoms. The esophagram revealed esophageal dilation and a “bird-beak” sign (► Fig. 1). Endoscopy revealed a massively dilated esophagus and narrow esophagogastric junction (EGJ) (► Fig. 2). POEM was planned.

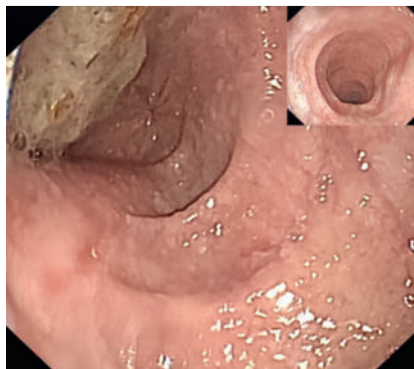Submucosal injections were administered 10 cm above the cardia, but resulted in no significant lift here or in other attempted injection sites. The submucosal adhesion in the esophagus was severe, making it impossible to establish a submucosal tunnel (► Fig. 3). A full-thickness incision of the esophageal wall was performed from the mucosal layer at 6 cm above the EGJ to create a mediastinal tunnel (► Video 1). Full-thickness myotomy started 5 cm above the EGJ and extended distally to 2 cm below the cardia in the mediastinal tunnel (► Fig. 4). The tunnel entrance was closed with six clips after hemostasis. A nasogastric tube was placed for decompression and monitoring.

The patient remained fasting and started a liquid diet after removing the nasogastric tube on postoperative day (POD) 3. She was able to take solid food on POD 5 and was discharged, uneventfully, on POD 7. A month later, endoscopy showed significant relaxation of the cardia (► Fig. 5).

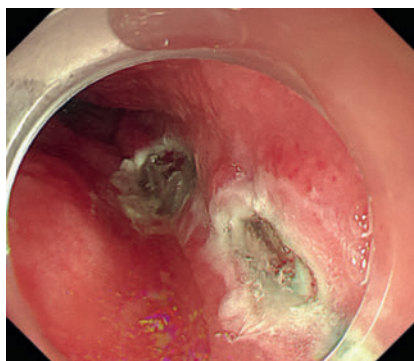
Peroral endoscopic mediastinal tunneling myotomy (POEMTM) is a novel technique combining POEM and laparoscopic Heller myotomy, using the mediastinum



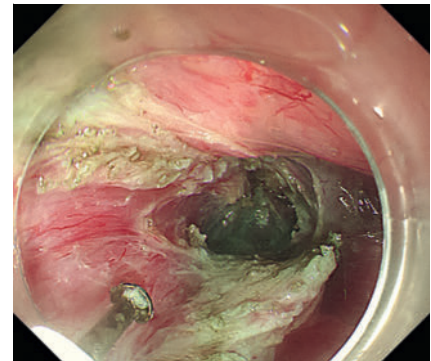
► Fig. 1 Barium esophagram before the procedure.



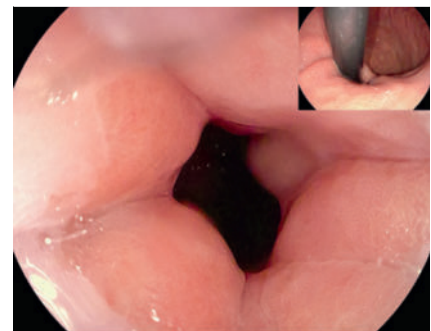
► Fig. 2 Endoscopy before the procedure.



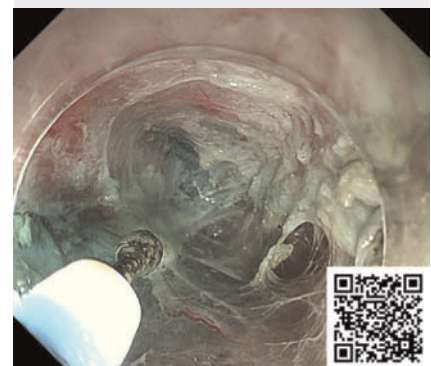
► Fig. 3 The submucosal tunnel could not be established due to severe submucosal fibrosis.



► Fig. 4 Full-thickness myotomy in the mediastinal tunnel.



► Fig. 5 Endoscopy after the procedure.



► Video 1 Mediastinal dissection and tunneling.

for operating entry. In this video, we report the first application of POEMTM for achalasia with difficult submucosal tunnel, which may indicate a minimally invasive, safe, and effective alternative.

Endoscopy_UCTN_Code_TTT_1AO_2AG

Conflict of Interest

The authors declare that they have no conflict of interest.

The authors

Lijun Song¹, Liyun Ma², Li Wang³, Guoliang Zhang¹, Ye Wang¹

- 1 Department of Gastroenterology, Tianjin First Central Hospital, Tianjin, China
- 2 Endoscopy Center and Endoscopy Research Institute, Zhongshan Hospital, Fudan University, Shanghai, China
- 3 Department of Cardiology, Tianjin First Central Hospital, Tianjin, China

Corresponding author

Ye Wang, MD, PhD

Department of Gastroenterology, Tianjin First Central Hospital, 24 Fukang Road, Tianjin 300192, China
464026116@qq.com

References

- [1] Ciomperlik H, Dhanani NH, Mohr C et al. Systematic review of treatment of patients with achalasia: Heller myotomy, pneumatic dilation, and peroral endoscopic myotomy. *J Am Coll Surg* 2023; 236: 523–532
- [2] Wu QN, Xu XY, Zhang XC et al. Submucosal fibrosis in achalasia patients is a rare cause of aborted peroral endoscopic myotomy procedures. *Endoscopy* 2017; 49: 736–744. doi:10.1055/s-0043-113440

Bibliography

Endoscopy 2024; 56: E400–E401
DOI 10.1055/a-2308-2823
ISSN 0013-726X
© 2024. The Author(s).

This is an open access article published by Thieme under the terms of the Creative Commons Attribution License, permitting unrestricted use, distribution, and reproduction so long as the original work is properly cited.

(<https://creativecommons.org/licenses/by/4.0/>)

Georg Thieme Verlag KG, Rüdigerstraße 14, 70469 Stuttgart, Germany



ENDOSCOPY E-VIDEOS

<https://eref.thieme.de/e-videos>



E-Videos is an open access online section of the journal *Endoscopy*, reporting on interesting cases and new techniques in gastroenterological endoscopy. All papers include a high-quality video and are published with a Creative Commons CC-BY license. *Endoscopy E-Videos* qualify for HINARI discounts and waivers and eligibility is automatically checked during the submission process. We grant 100% waivers to articles whose corresponding authors are based in Group A countries and 50% waivers to those who are based in Group B countries as classified by Research4Life (see: <https://www.research4life.org/access/eligibility/>).

This section has its own submission website at <https://mc.manuscriptcentral.com/e-videos>