

American Journal of Perinatology Reports

Abdominal Fibromyxoid Sarcoma in Pregnancy: An Unusual Cause of Preterm Labor and Sepsis

Abigail Barger, Maya Vishnia, Marie Hanna, Rebecca Horgan, Juliana Gevaerd Martins.

Affiliations below.

DOI: 10.1055/a-2332-6187

Please cite this article as: Barger A, Vishnia M, Hanna M et al. Abdominal Fibromyxoid Sarcoma in Pregnancy: An Unusual Cause of Preterm Labor and Sepsis. American Journal of Perinatology Reports 2024. doi: 10.1055/a-2332-6187

Conflict of Interest: The authors declare that they have no conflict of interest.

Abstract:

Cancer in pregnancy is rare with most common cancers being melanomas, breast and cervical. Fibromyxoid sarcoma is a soft tissue tumor involving deep soft tissues of the extremities and trunk, rarely located in the abdomen. A low-grade fibromyxoid sarcoma (LGFMS) falls in the family of fibrosarcoma. Only two cases of LGFMS in pregnancy have been reported.

We report a case of abdominal LGFMS in pregnancy leading to preterm labor, sepsis and an acute abdomen requiring surgery in the third trimester. 19-year-old woman, gravida 1 at 32 weeks and 5 days presented to an outside hospital with preterm contractions and cervical effacement. She had a known abdominal mass, suspected to be accessory liver lobe, measuring 9.0 x 6.4 x 7.7 cm in the right upper quadrant. At 33 weeks of gestation, she had developed fever and hypotension. MRI confirmed findings however visualized in the left side of the abdomen with suspected abscess. She underwent cesarean delivery, and complete surgical resection of the mass along with a small bowel resection. Final pathology of the mass revealed a LGFMS. This case also highlights the need for a multidisciplinary approach to manage a rare presentation of sepsis and preterm labor in pregnancy

Corresponding Author:

Assistant Professor Juliana Gevaerd Martins, Eastern Virginia Medical School, OBGYN, 825 Fairfax Avenue, 23501-1980 Norfolk, United States, juxande@gmail.com

Affiliations:

Abigail Barger, Eastern Virginia Medical School, OBGYN, Norfolk, United States

Maya Vishnia, Eastern Virginia Medical School, OBGYN, Norfolk, United States

Marie Hanna, Eastern Virginia Medical School, OBGYN, Norfolk, United States

Rebecca Horgan, Eastern Virginia Medical School, Maternal Fetal Medicine, Norfolk, United States

Juliana Gevaerd Martins, Eastern Virginia Medical School, OBGYN, Norfolk, United States

Abdominal Fibromyxoid Sarcoma in Pregnancy: An Unusual Cause of Preterm Labor and Sepsis

1. Abigail Barger, MD¹
2. Maya Vishnia, MS¹
3. Marie Hanna, MD¹
4. Rebecca Horgan, MD¹
5. Juliana Martins, MD¹

¹Eastern Virginia Medical School, Norfolk, VA; Department of Obstetrics and Gynecology

Corresponding author:

Juliana Gevaerd Martins, MD

825 Fairfax Avenue, Suite 310, Norfolk VA, 23507

Acknowledgements: The authors report no conflict of interest. No source of funding was provided.

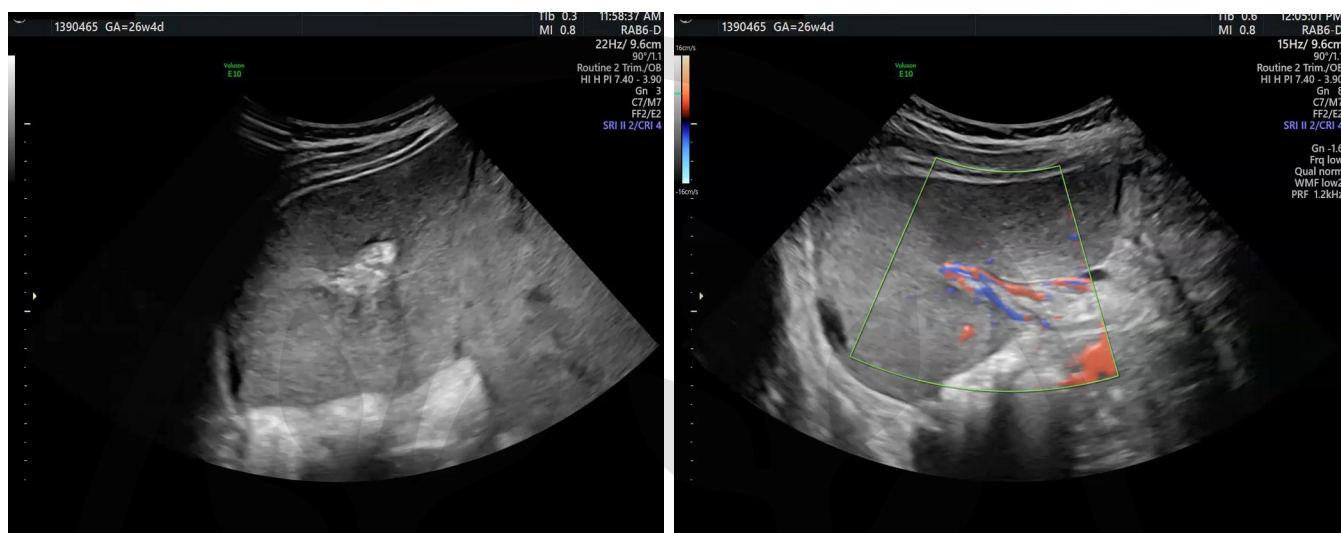


Figure 1: Outpatient ultrasound at 26 weeks gestation showing a solid mass, (A) about 10 cm, suspected to be in the right adnexa and (B) with a central vascular hyperechoic area seen with vessels tracing into mesentery.

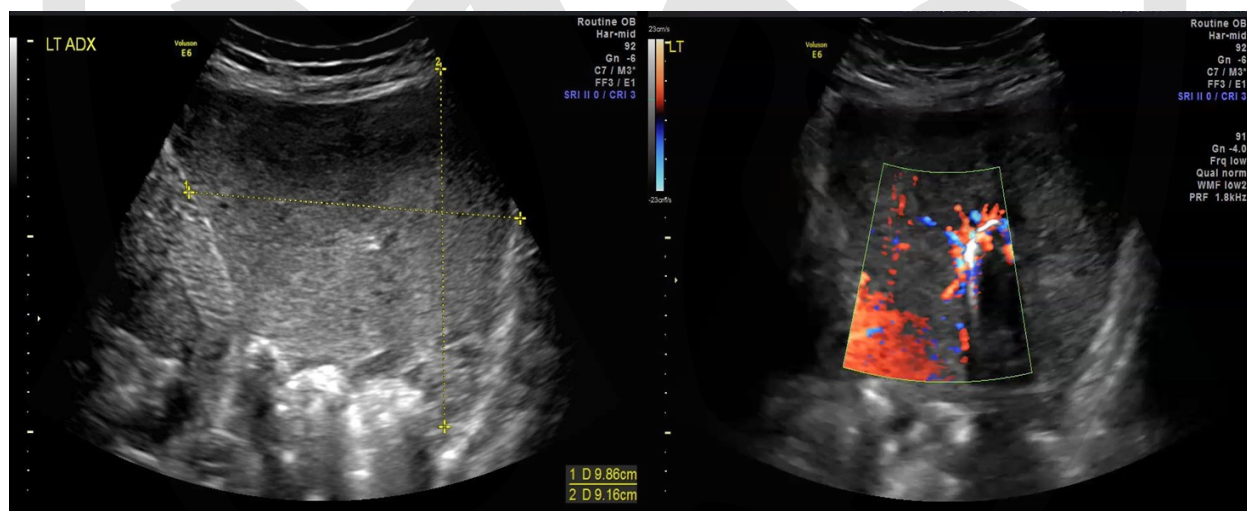


Figure 2: Inpatient ultrasound showing a previously identified right adnexal mass now on the left, with stable size and characteristics, including prominent vascularity.

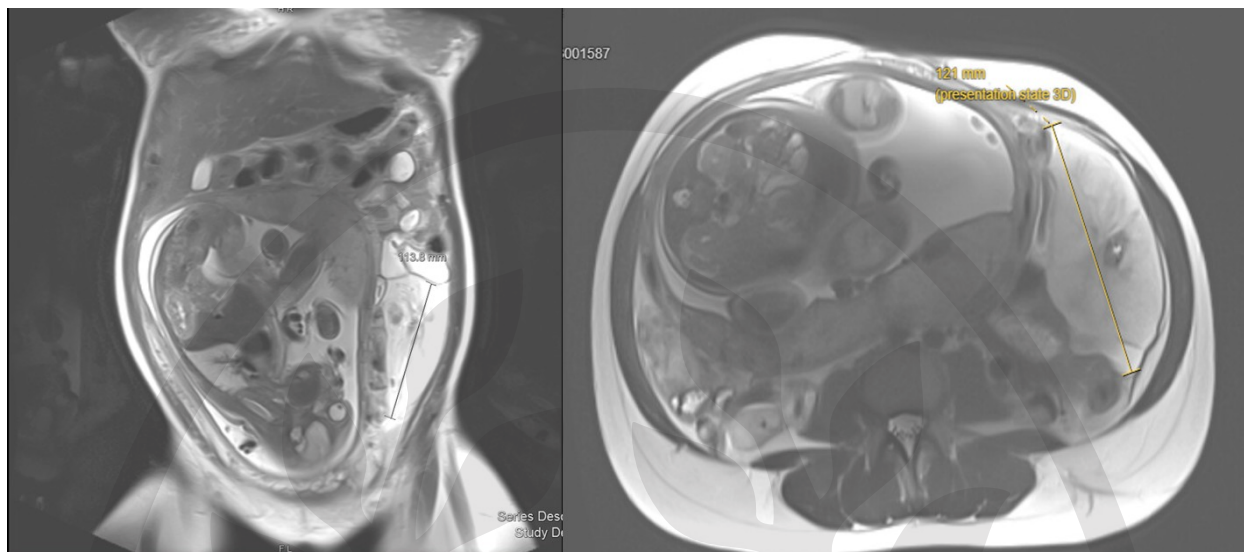


Figure 3: Inpatient magnetic resonance imaging (MRI) without contrast showing left-sided 12 cm abdominal mass.

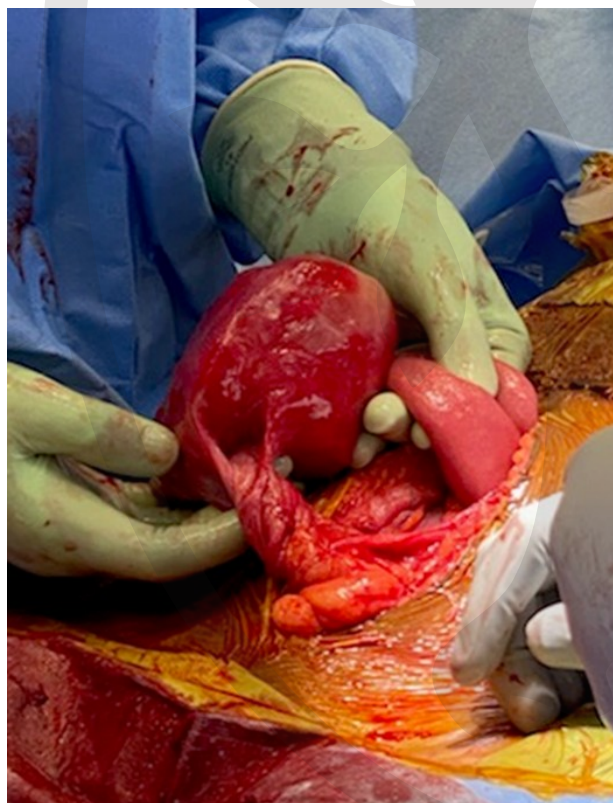

Figure 4: Intraoperative assessment of the mass, seen adhered to the small bowel

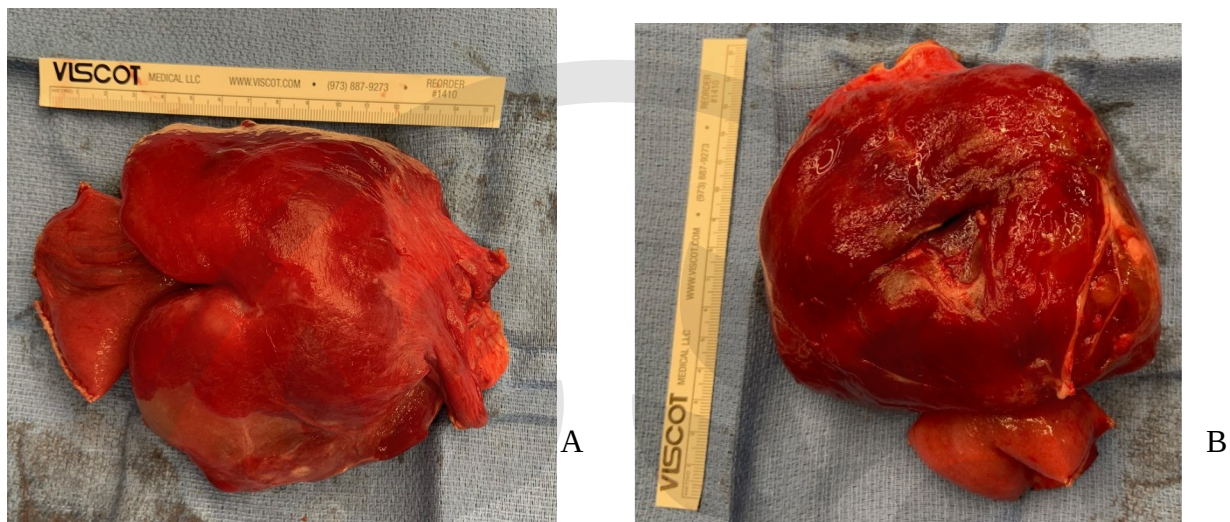


Figure 5: The intraoperative mass was resected with a portion of small bowel attached (A anterior, and B posterior, showing orifice draining pus)

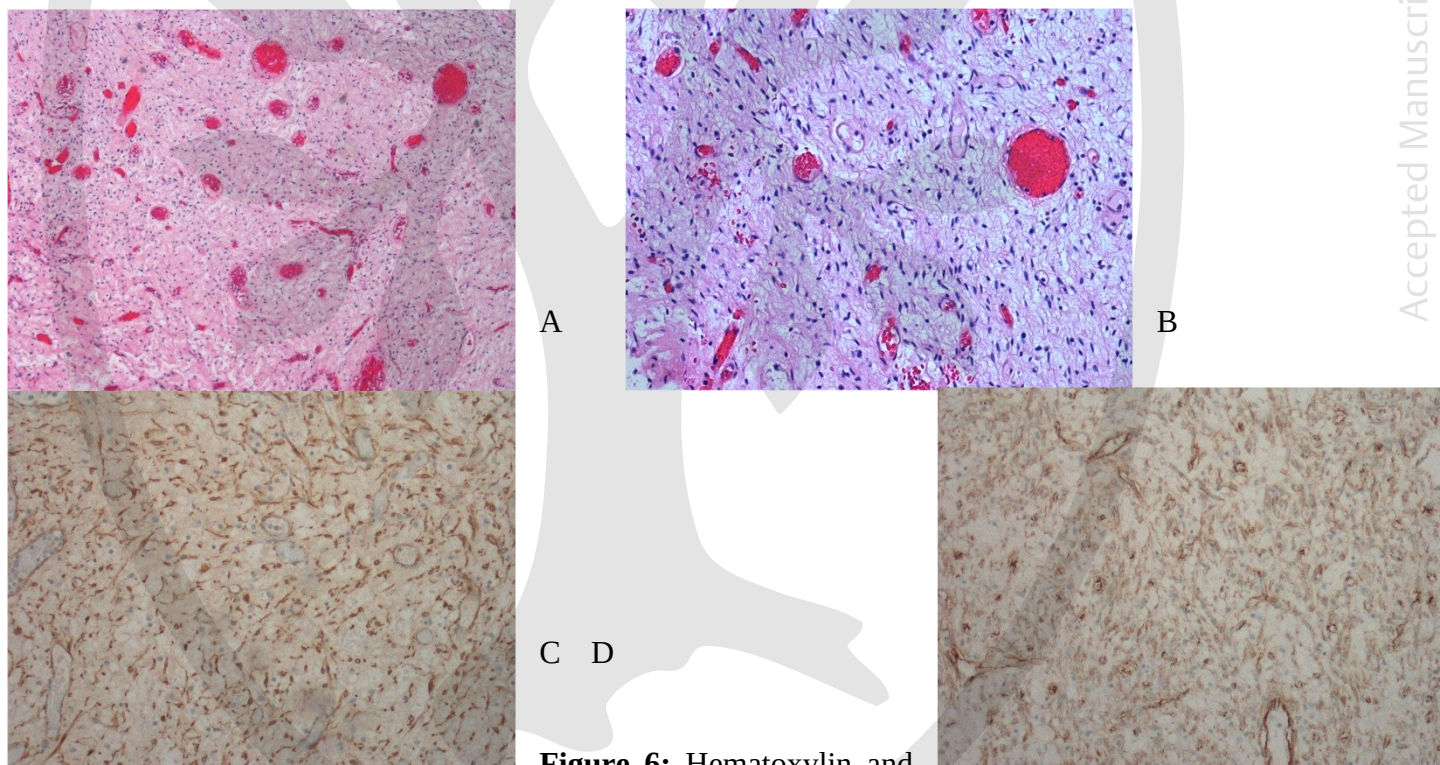


Figure 6: Hematoxylin and eosin stained at 40x (A) and 100x (B), smooth muscle actin immunostain (C) and beta catenin

immunostain (D) showing the characteristics of the low grade fibromyxoid spindle cell neoplasm.



Abdominal Fibromyxoid Sarcoma in Pregnancy: An Unusual Cause of Preterm Labor and Sepsis

Abstract

Cancer in pregnancy is rare, with incidence less than 1%, and most common cancers being melanomas, breast and cervical. Fibromyxoid sarcoma is a soft tissue tumor involving deep soft tissues of the extremities and trunk, rarely located in the abdomen. A low-grade fibromyxoid sarcoma (LGFMS) falls in the family of fibrosarcoma. Only two cases of LGFMS in pregnancy have been reported.

We report a case of abdominal LGFMS in pregnancy leading to preterm labor, sepsis and an acute abdomen requiring surgery in the third trimester. 19-year-old woman, gravida 1 at 32 weeks and 5 days presented to an outside hospital with preterm contractions and cervical effacement. She had a known abdominal mass, suspected to be accessory liver lobe, measuring 9.0 x 6.4 x 7.7 cm in the right upper quadrant. At 33 weeks of gestation, she developed fever and hypotension. MRI confirmed the presence of the mass, which was now on the left side of the abdomen and associated with a suspected abscess. She underwent cesarean delivery, and complete surgical resection of the mass along with a small bowel resection. Final pathology of the mass revealed a LGFMS. This case also highlights the need for a multidisciplinary approach to manage a rare presentation of sepsis and preterm labor in pregnancy.

Keywords: sarcoma, pregnancy, sepsis, preterm labor

Abdominal Fibromyxoid Sarcoma in Pregnancy: An Unusual Cause of Preterm Labor and Sepsis

Introduction

Cancer during pregnancy is rare, with an estimated incidence of 0.07 to 0.1%¹⁻³. An increasing incidence has been reported in several studies, likely related to advanced maternal age^{1,4}.

The most common cancer types during pregnancy are malignant melanomas, breast, and cervical cancer¹. Bone and soft tissue sarcomas have been reported in pregnancy with osteosarcoma, liposarcoma and Ewing's sarcoma being the most likely histological types, comprising over 50% of the cases². Fibromyxoid sarcoma in pregnancy has been reported in two studies: one in the left atrium and ventricle and the other in the gluteus^{5,6}.

A fibromyxoid sarcoma is a soft tissue tumor involving deep soft tissues of the extremities and trunk, rarely located in the abdomen, and often presenting as a painless mass. A low-grade fibromyxoid sarcoma (LGFMS) falls in the family of fibrosarcoma. First described in 1987, it is histologically benign appearing but with a known high metastatic potential^{7,8}. They are commonly found in young or middle-aged men⁸⁻¹¹. The incidence is estimated at 0.18 per million, accounting for 0.6% of all soft tissue sarcomas¹². However, the true incidence is unknown, as the World Health Organization characterizes it as an "uncommon tumor"¹².

We report a case of a symptomatic abdominal fibromyxoid sarcoma in the third trimester of pregnancy, presenting initially with signs and symptoms of preterm labor, and then evolving into an acute abdomen and sepsis.

Case

A 19 year-old woman, gravida 1 at 32 weeks and 5 days gestation presented to an outside hospital with regular contractions and cervical effacement. For concerns for preterm labor (PTL), she was given betamethasone for fetal lung maturity, nifedipine for tocolysis, and intravenous fluids. She was then transferred to our tertiary care hospital for further care due to fetal prematurity. Upon arrival, her cervical exam was unchanged and her contractions had partially improved.

Her past medical history was remarkable for a known right adnexal mass measuring 9.0 x 6.4 x 7.7 cm, documented on her 26-week ultrasound (Figure 1). At that time, the etiology was unknown. The mass was described as solid with homogenous echotexture and prominent vasculature, adjacent to the liver, suspicious for being an accessory liver lobe. An MRI was recommended to further elucidate the characteristics and location of the mass. However, imaging was not performed before her presentation for PTL.

On hospital day 3 (33 weeks and 1 day gestation), the patient reported worsening abdominal pain, now in her left flank. A repeat ultrasound was immediately performed at bedside considering the new location of her pain. The mass which was previously described in the patient's right adnexa was now demonstrated in the left adnexa, with stable size and characteristics. This new finding was suspicious for a torsion of the mass, most likely resulting from the increased pressure of the growing uterus (Figure 2). An MRI was performed to better characterize the mass (Figure 3). Findings were consistent with ultrasound, reporting a large, soft tissue, vascular mass now visualized in the left side of the abdomen. There was also a suspicion for an abscess collection adjacent to the mass.

Her condition worsened as she developed a new onset of fever with a maximum temperature of 103 F (39.4 C), tachycardia to the 120s, and hypotension (blood pressure in the

90s/50s). She had severe lower abdominal tenderness on the left lower abdominal quadrant with guarding. Findings were suggestive of an acute abdomen and sepsis, and the patient was taken to the operating room along with general surgery and started on broad spectrum antibiotics due to concerns of intraabdominal infection with an unknown source.

A cesarean was followed by an exploratory laparotomy, via a low midline vertical skin incision and low transverse hysterotomy. During the cesarean the patient had significant uterine atony requiring several uterotonics, followed by blood transfusion of 2 units. Purulent peritoneal fluid from the left lower quadrant was sent for cytology. The mass was continuous with the peritoneum and resected along with a portion of the small bowel due to adhesions (Figure 4 and 5). A small bowel side-to-side anastomosis was completed.

The patient was discharged on postoperative day 7; afebrile, tolerating regular diet and with adequate pain control. The intraoperative fluid sample grew pan-sensitive *Klebsiella pneumoniae* for which she completed the antibiotics course. The infant did well and was discharged home on day 11 of life.

Final pathology of the mass revealed a low grade fibromyxoid spindle cell neoplasm. Pathology reported the tumor to be composed of spindle cells arranged in short fascicles in a fibromyxoid matrix. The cells had pale eosinophilic cytoplasm and oval nuclei with coarse speckled chromatin (Figure 6). The mitotic rate was less than 1 mitosis per 10 high power fields. Proximal, distal and radial margins appeared clear of neoplasm but the tumor extended to the visceral peritoneum.

Patient was referred to the Oncology service and is currently under surveillance every 6 months with imaging, to assess for risk of recurrence. To date, patient has been stable with no reported recurrence.

Discussion

Fibromyxoid sarcomas are soft tissue tumors involving deep soft tissues rarely found in the abdomen as described in the non-pregnant population¹³. They affect patients of all ages, with peak incidence in young adults, with an equal male to female ratio^{13,14}. In a large series of pregnancies complicated by bone and soft tissue tumors, the most common affected locations were the pelvis, abdomen and extremities². Very few case reports have been published about intraabdominal fibromyxoid sarcoma^{9,10,15}

LGFMS has a histologically benign appearance however it is a malignant and late metastasizing tumor¹³. Rates of recurrence are difficult to assess due to low incidence of these tumors, and difficult follow up with long intervals from primary diagnosis to recurrence⁷. In a series of 33 LGFMS cases, patients with negative margins at diagnosis had better survival⁷. Smaller tumors (<3.5cm) were associated with decreased recurrence. Local recurrence was demonstrated in 63% of the cases, metastasis in 46% with site of metastasis in lung, pleura and chest wall.

The management of pregnancies complicated by cancer remains challenging due to late diagnosis in most of the cases resulting from overlap between pregnancy physiological changes and cancer symptoms as well as delayed treatment due to potential maternal and fetal risks^{1,2}.

The best treatment approach of sarcomas in pregnancy remains debatable. Overall, pregnant women are candidates for standard surgical management in pregnancy². The decision for chemotherapy or radiation should be evaluated on an individual basis². Multidisciplinary approach between obstetricians, oncologists and neonatologists is essential to improve outcomes². Due to its low nuclear grade and infrequent mitotic activity, LGFMSs are not

sensitive to chemotherapy or radiation¹³. Surgical excision with clear resection margins remains the first line treatment option^{13,14}.

In the largest systematic review of the literature currently available on 40 pregnancies complicated by sarcomas (including uterine, vaginal, vulvar and retroperitoneal), the mean age of patients was 27.8 ± 7.0 , onset of symptoms was described in the third trimester in 50% of the cases, 42% did not have initial suspicion for malignancy, 82% had live-born infants with premature deliveries in almost 50% of the cases³. In all cases, the primary tumor was treated with excision, 5 cases used neoadjuvant radiation, and in 1 case, chemotherapy was used⁷. Our case is the first one in the literature to report an abdominal fibromyxoid sarcoma in pregnancy. As evidenced by intraoperative finding, the sarcoma was thought to have torsed to include a part of the small bowel causing an intra-abdominal infection leading to sepsis and preterm labor. Additionally, a common gut flora, *Klebsiella pneumonia*, was cultured from the intraabdominal fluid collection, which is indicative of a possible bowel perforation¹⁶. This case not only demonstrates that our patient's characteristics and outcomes are similar to what has been previously reported³ but also highlights the importance of keeping a broad differential when evaluating preterm labor, including causes of acute abdomen and sepsis as well as understanding how the anatomical changes in pregnancy need to be taken into consideration when making diagnosis of a surgical abdomen such as in cases of appendicitis or this specific case. This case also highlights the need for a multidisciplinary approach to safely evaluate and manage a rare presentation of sepsis and preterm labor in pregnancy.

References

1. Lundberg F, Stensheim H, Ullenhag G, Sahlgren H, Lindemann K, Fredriksson I, Johansson A. Risk factors for the increasing incidence of pregnancy associated cancer in Sweden – a population based study. *Acta Obstet Gynecol Scand* 2023;00:1-15
2. Figueiro-Filho E, Al-Sum H, Parrish J, Wunder J, Maxwell C. Maternal and fetal outcomes in pregnancies affected by bone and soft tissue tumors. *Am J Perinatol Rep* 2018;8:e343-e348
3. Matsuo K, Eno M, Im D, Rosenshein N. Pregnancy and genital sarcoma: a systematic review of the literature. *Am J Perinatol* 2009;26:507-518
4. Zarkavelis G, Petrakis D, Fotopoulos G, Miltrou S, Pavlidis N. Bone and soft tissue sarcomas during pregnancy: a narrative review of the literature. *Journal of Advanced Research* 2016; 581-587
5. Buchanan TR, Kim SH, Pereira N. Infiltrating gluteal fibrosarcoma presenting as back pain in pregnancy. *Int J Gynaecol Obstet* 2013; 123 (02): 163-164
6. Zhang W, Zheng X, Ni B, Gu W, Sun H, Shao Y, Zhang S. Myxoid fibrosarcoma of the left atrium and ventricle in pregnancy. *Ann Thorac Surg* 2014;98(05)1818-1819
7. Evans, H. L. (2011). Low-Grade Fibromyxoid Sarcoma. *The American Journal of Surgical Pathology*, 35 (10), 1450-1462. doi: 10.1097/PAS.0b013e31822b3687.
8. Arnaoutoglou, C., Lykissas, M.G., Gelalis, I.D. et al. Low grade fibromyxoid sarcoma: a case report and review of the literature. *J Orthop Surg Res* 5, 49 (2010). <https://doi.org/10.1186/1749-799X-5-49>
9. Konecna J, Liberale G, Haddad J, de Saint-Aubain N, El Nakadi I. Diffuse intra-

abdominal low grade fibromyxoid sarcoma with hepatic metastases: Case report and review of the literature. *International journal of surgery case reports*. 2015;14:40-43.

10. Geramizadeh B, Zare Z, Dehghanian AR, Bolandparvaz S, Marzban M. Huge mesenteric low-grade fibromyxoid sarcoma: A case report and review of the literature. *Rare tumors*. 2018;10:2036361318777031.
11. Dugalic V, Ignjatovic, II, Kovac JD, et al. Low-grade fibromyxoid sarcoma of the liver: A case report. *World journal of clinical cases*. 2021;9(1):175-182.
12. Maretty-Nielsen K, Baerentzen S, Keller J, Dyrop HB, Safwat A. Low-Grade Fibromyxoid Sarcoma: Incidence, Treatment Strategy of Metastases, and Clinical Significance of the FUS Gene. *Sarcoma*. 2013;2013:256280. doi: 10.1155/2013/256280. Epub 2013 May 30. PMID: 23818812; PMCID: PMC3683502.
13. Mohamed M, Fisher C, Thway K. Low-grade fibromyxoid sarcoma: clinical, morphologic and genetic features. *Annals of Diagnostic Pathology* 28 (2017) 60-67.
14. Chamberlain F, Engelmann B, Al-Muderis O, Messiou C, Thway K, Miah A, Zaidi S, Constantinidou A, Benson C, Gennatas S, Jones R. Low-grade fibromyxoid sarcoma: treatment outcomes and efficacy of chemotherapy. *In Vivo* 2020; 34:239-245
15. Singh K, Singh S, Pal N, Sampley SK, Chhabra K. Low-grade fibromyxoid sarcoma of anterior abdominal wall. *The Indian journal of surgery*. 2012;74(4):351-353.
16. Brown D, Vashisht R, Caballero Alvarado JA. Septic Peritonitis. 2022 Sep 19. In: StatPearls [Internet]. Treasure Island (FL): StatPearls Publishing; 2023 Jan-. PMID: 30252385.