

47–50

# Kyphoplasty: Traditional imaging compared with computer-guided intervention—time to rethink technique?

Authors Michael P Silverstein<sup>1</sup>, Michael Mac Millan<sup>2</sup>, Isador H Lieberman<sup>3</sup>

Institutions <sup>1</sup> Florida State University, College of Medicine, Tallahassee, FL, USA

<sup>2</sup> Department of Orthopaedic Surgery, University of Florida College of Medicine, Gainesville, FL, USA

<sup>3</sup> Medical Interventional & Surgical Spine Center, Department of Orthopaedic Surgery, Cleveland Clinic Hospital, Weston, FL, USA

## ABSTRACT

**Study design:** Equivalence trial (IRB not required for cadaveric studies).

**Objective:** To compare computer-guided and fluoroscopic kyphoplasty. Factors of interest were radiation exposure, position of cannula within pedicles and procedure time.

**Methods:** Kyphoplasty was performed on two cadavers. Computer-navigated, cross-sectional images from a cone-beam CT were used for one and fluoroscopic imaging for the other. In each, T6–9 and T11–L2 vertebrae were selected. For both imaging methods, anteroposterior and lateral x-rays were taken. Radiation exposure for both procedures was measured by four dosimeters. Procedure time, radiation to surgeon and cadaver, and position of cannula placement within pedicles were recorded. The surgeon wore one under the lead gown, another on the lead gown at shoulder level, and a third as a ring on the dominant hand. A dosimeter was also placed on the cadaver.

**Results:** The radiation from the cone-beam, computer-guided imaging system was 0.0 mrem to the surgeon and 0.52 rads to the cadaver. Using fluoroscopic imaging, surgeon's and cadaver's exposure was 5 mrem and 0.047 rads, respectively. Procedure times were similar and neither device resulted in cannula malposition.

**Conclusions:** Cone-beam CT appears as accurate as the fluoroscopy; radiation exposure to the surgeon is eliminated, and radiation levels to the patient are acceptable.

No financial support was received for this research.

## STUDY RATIONALE AND CONTENT

Kyphoplasty is a surgical technique for height restoration and cement augmentation of vertebral bodies following osteoporotic vertebral compression fractures or osteolytic lesions [1–4]. Most studies reveal a low rate of procedure-related adverse events [5–7]. However, when fluoroscopic imaging is used, radiation exposure of the surgeon and patient are of concern. Many of the complications of kyphoplasty have to do with inaccurate cannula placement. Computer guidance has reduced radiation to surgeon but equivalent imaging accuracy to fluoroscopy.

## OBJECTIVE

To examine the proposition that computer-guided cone-beam CT technology could be used to perform balloon kyphoplasty and subsequently reduce patient and physician radiation exposure from that occurring with the fluoroscopic technique without prolonging the procedure or foregoing acceptable positioning of cannulas within pedicles.

## METHODS

**Study design:** Equivalence trial (IRB not required for cadaveric studies).

**Inclusion criteria:** A cadaveric study to examine the use of cone-beam CT and fluoroscopic assistance during a kyphoplasty.

**Exclusion criteria:** Cadavers with spinal malformations and/or deformities were excluded from this study.

### Techniques compared (Table 1)

- Two cadavers were utilized for the study. Cone-beam CT provided imaging assistance on one of the cadavers and fluoroscopy for the second cadaver. In each of the two cadavers, the vertebra T6–9 (thoracic) and T11–L2 (thoracolumbar) were selected.
- **Kyphoplasty:** The thoracic and the thoracolumbar vertebral pedicles were accessed by placing a Jamshidi needle percutaneously in the pedicle and then a guide wire. Subsequently, both cone-beam CT and fluoroscopic images in each cadaver respectively were taken at each level when the cannulas were in the proper position.
- **Cone-beam CT:** The procedure was guided through images obtained from the Breakaway® O-arm (Medtronic Inc., Louisville, CO). Navigation was computer controlled from the Stealth® Station (Medtronic Inc., Louisville, CO). A high-speed drill, guided with Navigation system (Medtronic Inc., Louisville, CO) was used to percutaneously bore a pilot hole down the center of the target pedicle and then place a guide wire in the pilot hole. The cannula was then positioned over the guide wire.
- **Fluoroscopy:** Fluoroscopy was used during the procedure to determine location. Biplanar imaging was used for the fluoroscopic procedure. This included anteroposterior (AP) and a lateral C-arm position. When the cannulas were in proper placement in the pedicle of both the cadavers, AP and lateral x-rays were taken to assess position of the cannulas.

### Outcomes and analysis

- **Primary outcomes:** Procedure time, radiation exposure to the surgeon and cadaver, and acceptable positioning of cannula within pedicles was assessed during the procedure for both cone-beam CT and fluoroscopic assistance.
- **Secondary outcomes:** none.

Additional information regarding technical and methodological aspects can be found in the web appendix at [www.aospine.org/ebsj](http://www.aospine.org/ebsj).

## RESULTS

The time required to perform each procedure with fluoroscopy and cone-beam CT was not significantly different (Table 1).

- Radiation exposure to cadaver from the cone-beam CT was equivalent to the exposure to a patient undergoing a kyphoplasty would experience during cannula insertion (Table 1).
- Assessment of the cannula position revealed no cannula malpositions or procedure-related complications for either technique.
- A cone-beam CT image profile includes images from a single rotation of the cone beam around the cadaver, as well as a digital image that projects instrumental targeting trajectory (Fig 1).
- The fluoroscopic procedure includes an AP (Fig 2a) and a lateral image (Fig 2b).

## DISCUSSION

Radiation is a concern to both the surgeon and patient during a kyphoplasty with minimal available information regarding cone-beam CT exposure [8, 9].

- Both fluoroscopy and cone-beam CT assisted in allowing the acceptable placement of the cannula within pedicles, without a significant difference.
- Acceptable placement was assessed based on a two condition assessment. These conditions included whether the cannula remained within the pedicle or if it violated the cortical boundaries of the pedicle.
- Strengths: Cone-beam CT resulted in zero radiation exposure to the surgeon. When helpful, the system provides imaging assistance with projection of trajectory for cannula placement.
- Limitation: The study may have not included enough cadavers to detect possible surgical performance problems. With this possibility, there may have been differences in procedure time.
- Fluoroscopy and cone-beam CT imaging both provide necessary imaging assistance to perform a kyphoplasty. Cone-beam CT provides additional tools which may be beneficial in minimally invasive procedures and zero radiation exposure to the surgeon.
- A multicenter trial utilizing both fluoroscopy and cone-beam CT during a kyphoplasty may provide stronger evidence for the accuracy and benefit of the two imaging options.

Table 1 Radiation to physician, cadaver, and procedure time

Imaging devices	Number of levels	Radiation to physician	Radiation to cadaver	Total time of procedure
Cone-beamCT	8	0 mrem	0.52 rads	34 minutes, 32 seconds
Fluoroscopy	8	5 mrem	0.047 rads	32minutes,51 seconds

Fig 1 Cone-beam CT image as displayed on the Stealth Navigation workstation screen

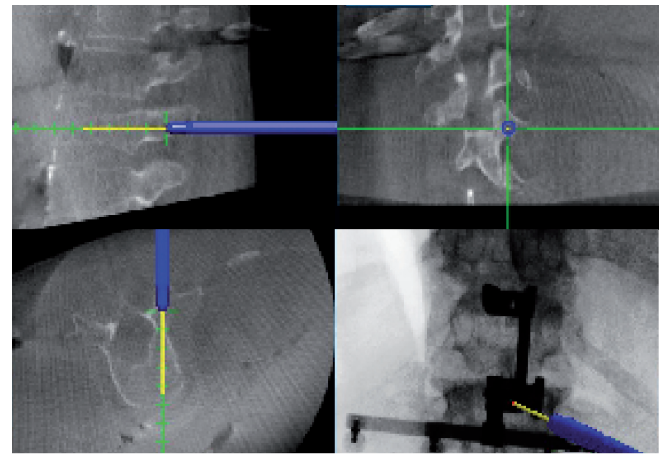
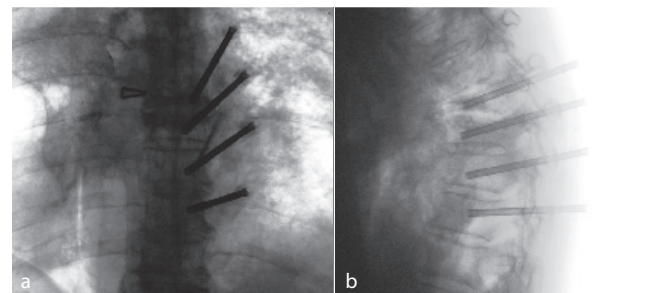


Fig 2 Position of cannulas were assessed in anteroposterior (AP) and lateral views during fluoroscopic imaging.

- anteroposterior image
- lateral image



Cannula placement through pedicles into vertebral bodies.

Lateral view of vertebral body. The location of the cannulas are visualized through the pedicles.

---

## CONCLUSION

Using the cone-beam CT kyphoplasty technique:

- Fluoroscopy and cone-beam CT have similar imaging capabilities with equivalent time and accuracy.
- Cone-beam CT offers options such as targeting tools and projection lines.
- Fluoroscopy results in additional radiation exposure to the surgeon.
- Overall, device choice can be based on the surgeon's preference.

---

## REFERENCES:

1. **Kim DH, Vaccaro AR** (2006) Osteoporotic compression fractures of the spine; current options and considerations for treatment. *Spine J*; 6(5): 479–487.
2. **Berlemann U, Franz T, Orlor R, et al** (2004) Kyphoplasty for treatment of osteoporotic vertebral fractures: a prospective non-randomized study. *Eur Spine J*; 13(6): 496–501.
3. **Lieberman IH, Dudeney S, Reinhardt MK, et al** (2001) Initial outcome and efficacy of “kyphoplasty” in the treatment of painful osteoporotic vertebral compression fractures. *Spine*; 26:1631–1638.
4. **Melton, LJ 3rd, Kan SH, Frye MA, et al** (1989) Epidemiology of vertebral fractures in women. *Am J Epidemiol*; 29(5):1000–1011.
5. **Garfin SR, Buckley RA, Ledlie J** (2006) Balloon kyphoplasty outcomes group: balloon kyphoplasty for symptomatic vertebral body compression fractures results in rapid, significant, and sustained improvements in back pain, function, and quality of life for elderly patients. *Spine*; 31(19): 2213–2220.
6. **McArthur N, Kasperk C, Baier M, et al** (2009) 1150 kyphoplasties over 7 years: indications, techniques and intraoperative complications. *Orthopedics*; 32:90.
7. **Taylor RS, Fritzell P, Taylor RJ** (2007) Balloon kyphoplasty in the management of vertebral compression fractures: an updated systematic review and meta-analysis. *Eur Spine J*; 16:1085–1100.
8. **Villavicencio AT, Burneikiene S, Bulsara KR, et al** (2005) Intraoperative three-dimensional fluoroscopy-based computerized tomography guidance for percutaneous kyphoplasty. *Neurosurg Focus*; 18(3):e3.
9. **Mroz T, Yamashita T, Davros W, et al** (2008) Radiation exposure to the surgeon and the patient during kyphoplasty. *J Spinal Disord Tech*; 21(2):96–100.