

Achalasia associated with multiple esophageal diverticula

We describe a rare case of symptomatic achalasia associated with multiple esophageal diverticula, and report a successful clinical improvement after botulinum toxin injection.

A 66-year-old man had a 2-year history of worsening dysphagia to solids and liquids. In the previous 2 months, the patient had experienced episodes of immediate regurgitation of swallowed food and fluids. Since the onset of dysphagia, he had been treated irregularly with antacids.

Barium esophagogram demonstrated three right-sided esophageal diverticula along the mid to distal esophagus (● Fig. 1). Endoscopy revealed three diverticula in the esophagus (● Fig. 2a). Esophageal manometry was performed and showed that there was no peristalsis in the esophageal body. Each swallow resulted in simultaneous contractions (● Fig. 3)

Botulinum toxin was injected at four sites (● Fig. 2b). Following the injection therapy, the symptomatic response was accompanied by a decrease in the lower esophageal sphincter pressure and the patient was discharged. After 6 months, he had no dysphagia or vomiting.

Although esophageal diverticula have accompanied a variety of esophageal motility disorders, achalasia-associated multiple esophageal diverticula are extremely rare. Treatment of patients with achalasia with esophageal diverticula has the risk of iatrogenic esophageal perforation during pneumatic balloon dilatation [1]. Botulinum toxin injection could be recommended as an alternative treatment, especially in older patients with either an increased risk for dilation or who have failed to respond to other treatment modalities [2].

Endoscopy_UCTN_Code_CCL_1AB_2AC_3AF
Endoscopy_UCTN_Code_CCL_1AB_2AC_3AH

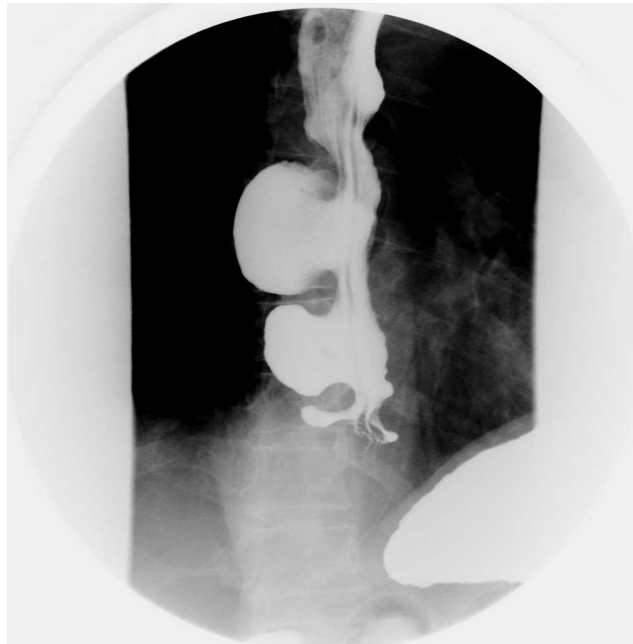

Fig. 1 View of barium esophagogram showing multiple diverticula.

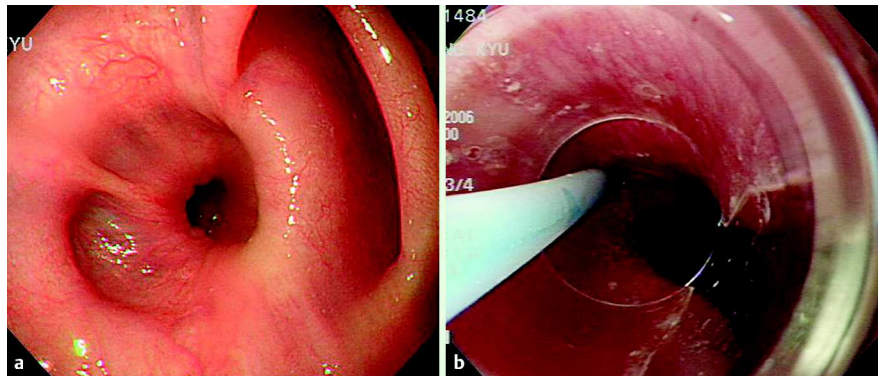


Fig. 2 Endoscopic view of esophageal diverticula. **b** View of botulinum toxin injection treatment.

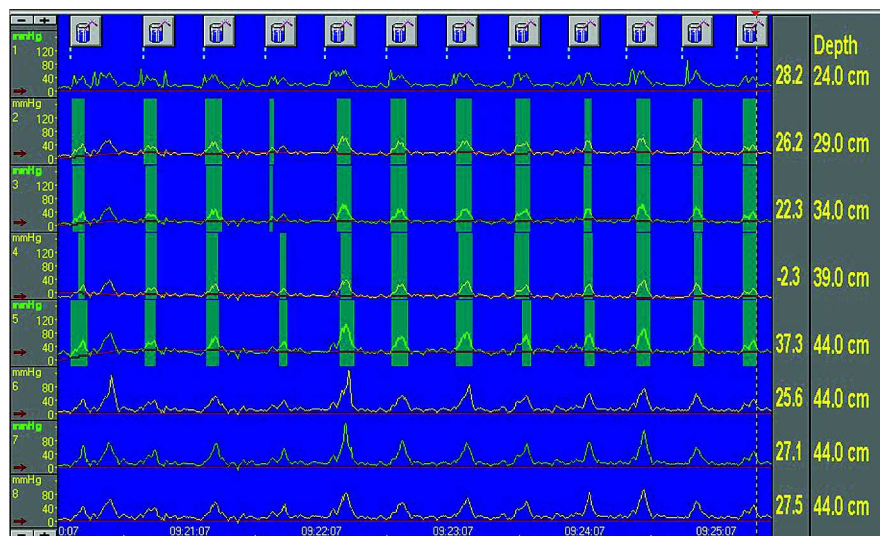


Fig. 3 Manometric view of aperistalsis in the esophageal body.

Y. Kim, J. H. Kim, C. Kim, H. Park

Internal Medicine, Yonsei University
College of Medicine, Seoul, Republic of
Korea

References

- 1 *Cantu P, Bozzani A, Penagini R et al.* Spontaneous perforation of an oesophageal diverticulum in achalasia. *Dig Liver Dis* 2003; 35: 735–737
- 2 *D’Onofrio V, Miletto P, Leandro G, Iaquinto G.* Long-term follow-up of achalasia patients treated with botulinum toxin. *Dig Liver Dis* 2002; 34: 105–110

Bibliography

DOI 10.1055/s-0028-1119488
Endoscopy 2009; 41: E47–E48
© Georg Thieme Verlag KG Stuttgart · New York ·
ISSN 0013-726X

Corresponding author

H. Park, MD
Internal Medicine
Yongdong Severance Hospital
Gangnamku
Dogok-dong 146-92
Seoul 135-720
Republic of Korea
Fax: +82-2-34633882
HJPARK21@yuhs.ac