

Complete esophageal obstruction: an unusual complication of esophageal variceal ligation

A 65-year-old woman with cirrhosis presented having suffered from acute chest discomfort and difficulty swallowing for 1 day. Two weeks previously, she had undergone esophagogastroduodenoscopy (EGD) with endoscopic variceal ligation (EVL) for bleeding esophageal varices. Repeat EVL was done on the day before the present admission for continued variceal eradication. After the procedure, the patient developed acute retrosternal discomfort and inability to tolerate oral intake, which worsened with observation. Gastrografin swallow on admission revealed complete esophageal obstruction at the level of the carina (● Fig. 1).

Repeat EGD showed a necrotic, completely obstructing mass in mid esophagus which could not be traversed even with a slim endoscope. Three bands were noted in the periphery of the obstructive mass (● Fig. 2).

No intervention was performed due to the risk of perforation and the patient was put on total parental nutrition. The following week, she experienced gradual improvement of the dysphagia. Eventually, she was able to tolerate a full diet. An upper gastrointestinal series 2 weeks later showed complete resolution of the esophageal obstruction (● Fig. 3).

Variceal bleeding is a major complication occurring in 30%–60% of patients with cirrhosis [1,2]. The associated mortality is as high as 20% within 6 weeks after the initial bleeding, and 60% of untreated patients experience recurrent bleeding within a year [1]. EVL is the therapy of choice for primary bleeding prophylaxis and postbleeding management [3,4]. The procedure is relatively safe, with very few reported complications; these include band site ulceration, bleeding, infection, transient dysphagia, and esophageal perforation caused by trauma [5].

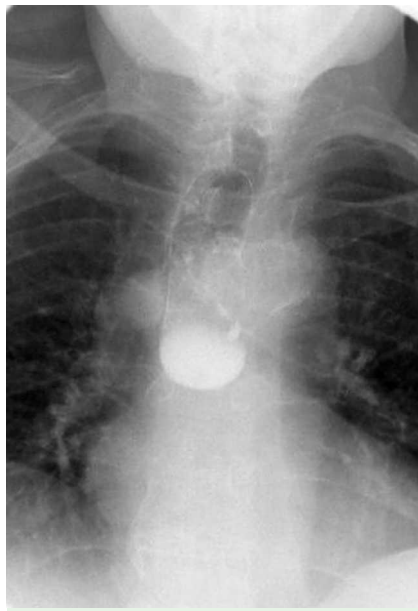


Fig. 1 Gastrografin swallow study showing complete obstruction to the passage of contrast through the esophageal lumen.

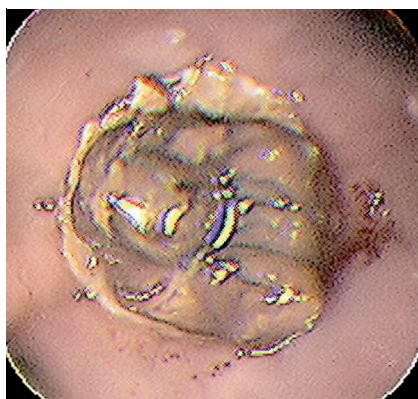


Fig. 2 Endoscopic view of complete obstruction of the esophagus.

Although transient dysphagia can occur following EVL, complete esophageal obstruction is rare. Our patient developed

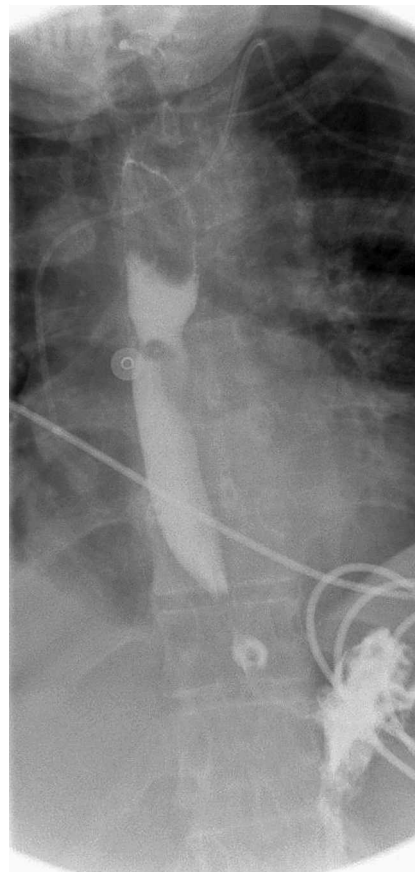


Fig. 3 Resolution of esophageal obstruction with conservative treatment.

complete esophageal obstruction after EVL with significant dysphagia, and the follow-up examination demonstrated esophageal obstruction at the EVL site. This obstruction occurred due to luminal compromise secondary to tissue edema and necrosis at the banding site. To avoid this, we recommend that EVLs should be applied in a spiral fashion, especially in patients needing multiple sessions, so as to avoid extensive luminal compromise on one plane.

Endoscopy_UCTN_Code_CPL_1AH_2AC

D. Verma, C. Pham, A. Madan

Division of Gastroenterology, The University of Texas Health Science Center, Houston, Texas, USA

References

- 1 *D'Amico G, de Franchis R Cooperative Study Group.* Upper digestive bleeding in cirrhosis. Post-therapeutic outcome and prognostic indicators. *Hepatology* 2003; 38: 599–612
- 2 *Carbonell N, Pauwels A, Serfaty L et al.* Improved survival after variceal bleeding in patients with cirrhosis over the past two decades. *Hepatology* 2004; 40: 652–659
- 3 *Garcia-Tsao G, Sanyal AJ, Grace ND, Carey W.* Prevention and management of gastroesophageal varices and variceal hemorrhage in cirrhosis. *Hepatology* 2007; 46: 922–938
- 4 *Lui HF, Stanley AJ, Forrest EH et al.* Primary prophylaxis of variceal hemorrhage: a randomized controlled trial comparing band ligation, propranolol, and isosorbide mononitrate. *Gastroenterology* 2002; 123: 735–744
- 5 *Lo GH, Chen WC, Chen MH et al.* Banding ligation versus nadolol and isosorbide mononitrate for the prevention of esophageal variceal rebleeding. *Gastroenterology* 2002; 123: 728–734

Bibliography

DOI 10.1055/s-0029-1214856
Endoscopy 2009; 41: E200–E201
© Georg Thieme Verlag KG Stuttgart · New York ·
ISSN 0013-726X

Corresponding author**A. Madan, MD, FACP**

Division of Gastroenterology
The University of Texas Health Science Center
6431 Fannin Street, MSB 4.234
Houston
TX 77030
USA
Fax: +1-713-5006699
anandmadan@hotmail.com