

## Endoscopic treatment of Zenker's diverticulum using a hook knife

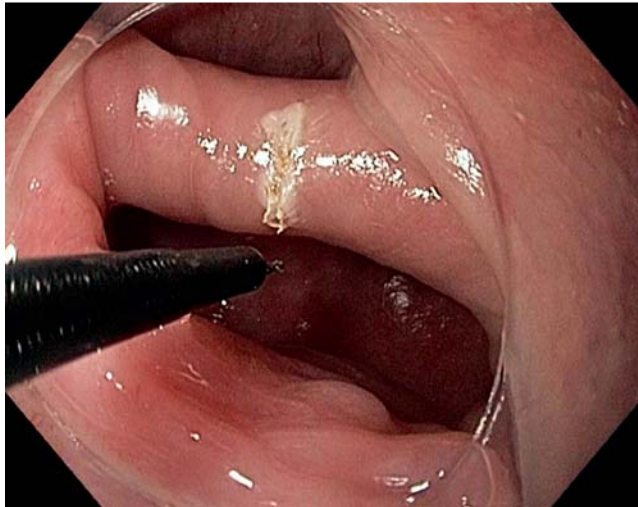
Zenker's diverticulum most often occurs between the seventh and eighth decade of life; the incidence is between 0.01% and 0.11% with a predominance in men. The diverticulum is located in Killian's triangle, between the inferior pharyngeal constrictor and the cricopharyngeus muscle. Its pathogenesis remains disputed, but impaired function of the upper esophageal sphincter, resulting in increased intrabolus pressure, has been implicated in the formation of the diverticulum. Patients with Zenker's diverticulum present with dysphagia, regurgitation of undigested food, and halitosis. With enlargement of the pouch, aspiration and consequent pneumonia, malnutrition, weight loss, and cervical borborygmi can occur. The clinical symptoms and barium swallow lead to diagnosis [1].

Treatment is indicated for all symptomatic patients with Zenker's diverticulum. Minimally invasive, flexible endoscopy techniques utilizing electrocautery, argon plasma coagulator, or carbon dioxide lasers are particularly suitable for the typical elderly patient suffering from Zenker's diverticulum with multiple comorbidities, high anesthetic risk, and reduced mouth opening. Perforation and mediastinitis occur in up to 5% of cases because the inferior border of the diverticulum beneath the muscle is endoscopically hard to define and thermal or incision injury is hard to control [2,3].

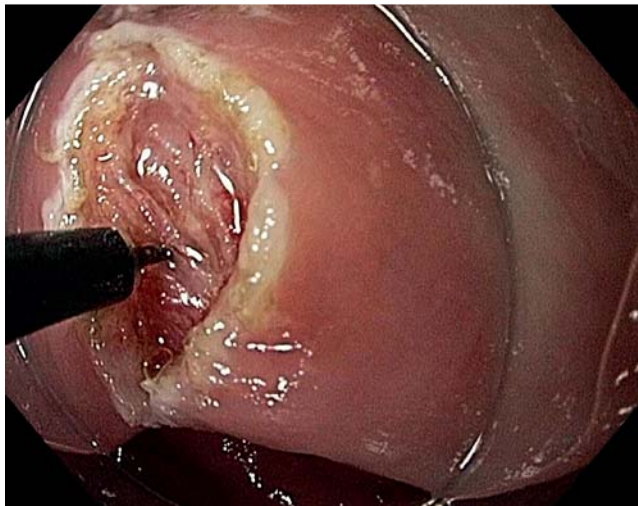
Here we report a case of a 3-cm Zenker's diverticulum in an 81-year-old woman, which was treated using a hook knife. First, a guide wire was inserted into the esophagus under endoscopic control. The endoscope (Olympus, Hamburg, Germany) was then reintroduced beside the guide wire and the mucosa above the cricopharyngeus muscle was incised using a standard needle knife (Olympus, Hamburg, Germany) (● Fig. 1).

The usually clearly visible cricopharyngeal muscle was dissected using the hook knife (Olympus, Hamburg, Germany) (● Fig. 2).

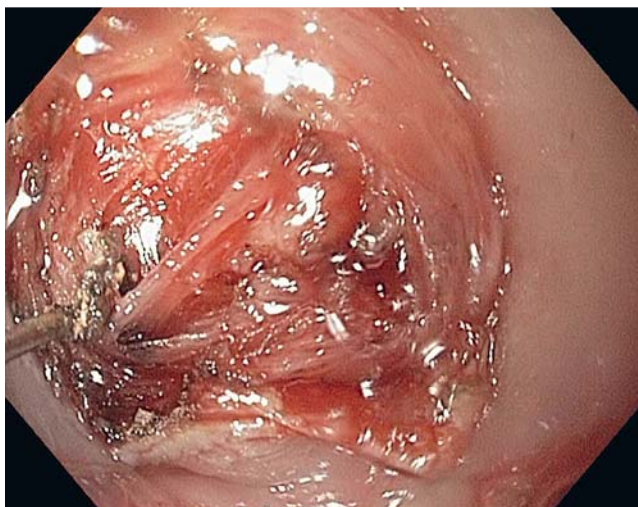
The hook knife is generally used for dissection of the submucosa during endoscopic submucosal dissection. The cricopharyngeal muscle fibers can be lifted easily with the hook knife and then cut



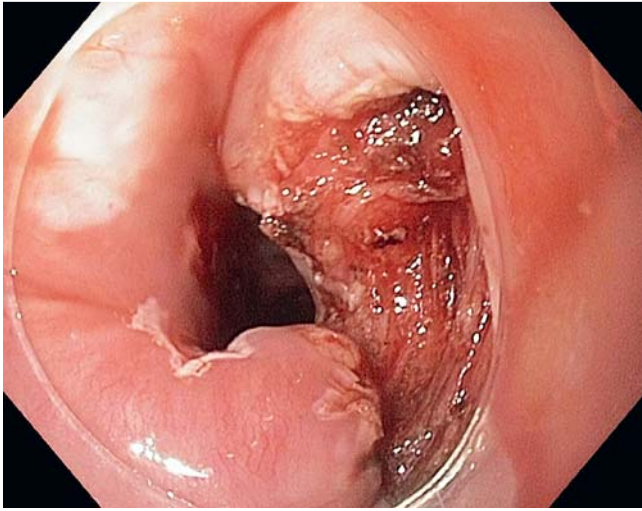
**Fig. 1** Mucosal incision with a needle knife.



**Fig. 2** Lifting and dissecting the muscle fibers with the hook knife.



**Fig. 3** Lifting and dissecting the muscle fibers with the hook knife.



**Fig. 4** The incision site post intervention.

without current applied toward the adventitia (► **Fig. 3** and **4**).

We have used the technique in two consecutive cases and it seems to be a safe alternative to the methods mentioned above. Postinterventional follow-up showed improved swallowing function with no signs of perforation.

Endoscopy\_UCTN\_Code\_TTT\_1AO\_2AN

**H. Heinrich, P. Bauerfeind**

Division of Gastroenterology, Department of Internal Medicine, University of Zürich, Zürich, Switzerland

**References**

- 1 *Ferreira LE, Simmons DT, Baron TH.* Zenker's diverticula: pathophysiology, clinical presentation, and flexible endoscopic management. *Dis Esophagus* 2008; 21: 1–8
- 2 *Costantini M, Zaninotto G, Rizzetto C et al.* Oesophageal diverticula. *Best Pract Res Clin Gastroenterol* 2004; 18: 3–17
- 3 *Sakai P.* Endoscopic treatment of Zenker's diverticulum. *Gastrointest Endosc* 2007; 65: 1054–1055

**Bibliography**

**DOI** 10.1055/s-0029-1215122

*Endoscopy* 2009; 41: E311–E312

© Georg Thieme Verlag KG Stuttgart · New York · ISSN 0013-726X

**Corresponding author**

**Dr. H. Heinrich**

Division of Gastroenterology,  
Department of Internal Medicine,  
University of Zürich

Rämistr 100

8091 Zürich

Switzerland

Fax: +41-442-554591

henriette.heinrich@usz.ch