

Esophagitis dissecans presenting with halitosis

A 25-year-old woman with halitosis but no remarkable medical history was referred for upper gastrointestinal endoscopy. There was no dysphagia, odynophagia, heartburn, weight loss, or any skin disease, but the patient had a cousin who had severe eosinophilic esophagitis. We carried out routine endoscopy under sedation with 5 mg intravenous midazolam and cardiopulmonary monitoring. While insufflating, we were surprised to see the mucosa split longitudinally in the proximal esophagus and the air enter underneath, detaching it (● Fig. 1) so that the mucosa resembled peeling snake skin. This occurred all the way down to the esophagogastric junction (● Fig. 2). There was no bleeding, and under the peeled off mucosa there was normal mucosa and a normal-appearing esophagus. There were no lesions in the stomach and duodenum. We carried out biopsies of the three esophageal segments, stomach, duodenum, and also of the peeled off mucosa. The pathologic examination was negative for eosinophilic esophagitis, with fewer than 10 esophageal eosinophils per high power field. The only significant finding was the presence of mild candidiasis in the peeled mucosa. At clinical follow-up 2 months later, the patient was asymptomatic.

Esophagitis dissecans superficialis is an rare illness, with few case reports; it has a benign outcome and is generally associated with bullous skin disease [1]. It is considered to be an autoimmune condition [2], although the etiology is still unknown and the endoscopic appearance is the most important diagnostic clue. Esophagitis dissecans has been associated with celiac disease and bisphosphonate treatment, although this seems to be more of a chemical esophagitis [3,4]. Its usual symptoms are odynophagia and heartburn, and it can be associated with bleeding and obstruction of the esophageal lumen, mimicking a foreign body. The present patient has no comorbidities, and the halitosis might have been related to the fungal colonization of the detached epithelium.

Endoscopy_UCTN_Code_CCL_1AB_2AC_3AH

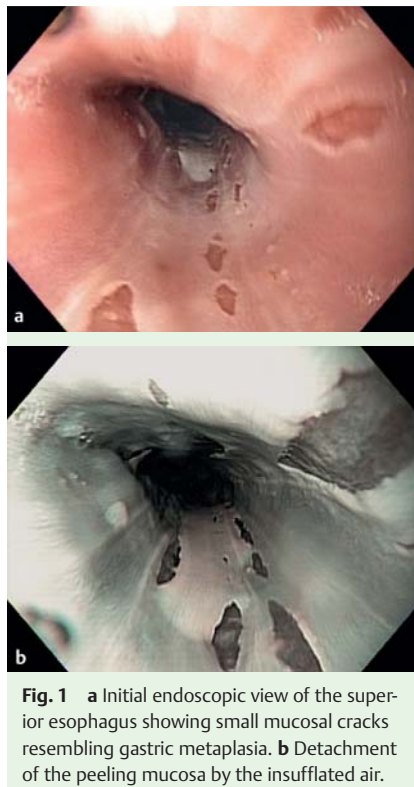


Fig. 1 a Initial endoscopic view of the superior esophagus showing small mucosal cracks resembling gastric metaplasia. b Detachment of the peeling mucosa by the insufflated air.

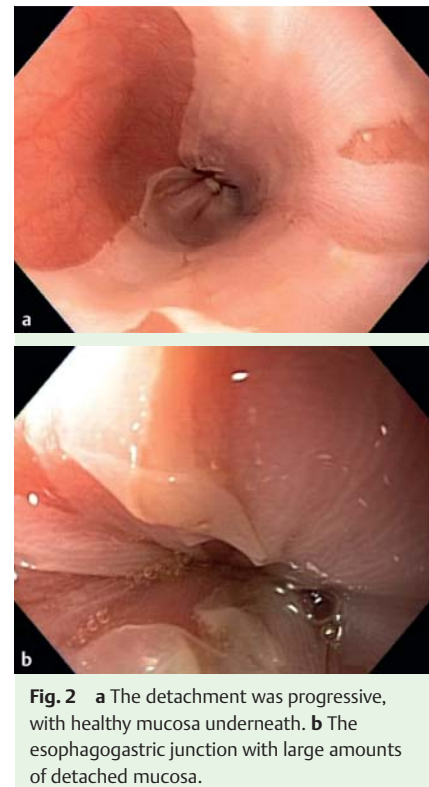


Fig. 2 a The detachment was progressive, with healthy mucosa underneath. b The esophagogastric junction with large amounts of detached mucosa.

I. Robles¹, R. Saenz²

- ¹ Hepatobiliary Surgery Division, Surgical Endoscopy Division, Hospital del Salvador, Santiago, Chile
- ² Gastroenterology and Endoscopy Department, Latin American Gastrointestinal Endoscopy Training Center, Clínica Alemana Universidad del Desarrollo, Santiago, Chile

References

- 1 Cesar WG, Barrios MM, Maruta CW et al. Oesophagitis dissecans superficialis: an acute, benign phenomenon associated with pemphigus vulgaris. *Clin Exp Dermatol* 2009; [Epub ahead of print]
- 2 Ponsot P, Molas G, Scoazec JY et al. Chronic esophagitis dissecans: an unrecognized clinicopathologic entity? *Gastrointest Endosc* 1997; 45: 38–45
- 3 Hokama A, Ihama Y, Nakamoto M et al. Esophagitis dissecans superficialis associated with bisphosphonates. *Endoscopy* 2007; 39 Suppl 1: E91
- 4 Hage-Nassar G, Rotterdam H, Frank D, Green PH. Esophagitis dissecans superficiales associated with celiac disease. *Gastrointest Endosc* 2003; 57: 140–141

Bibliography

DOI 10.1055/s-0029-1215365
 Endoscopy 2010; 42: E21
 © Georg Thieme Verlag KG Stuttgart · New York ·
 ISSN 0013-726X

Corresponding author

I. Robles
 Hepatobiliary Surgery Division,
 Surgical Endoscopy Division,
 Hospital del Salvador
 Príncipe de Gales 8639-E
 La Reina
 Santiago
 Chile
 iroblesg@gmail.com