

Applications of Platelet-Rich Fibrin Matrix in Facial Plastic Surgery

Anthony P. Sclafani, M.D., F.A.C.S.¹

ABSTRACT

Platelet concentrates enjoyed some clinical popularity in facial plastic surgery several years ago. However, interest waned due to expense, amount of blood required, equipment, space, and staff needed, and lack of clinically significant benefit. A novel, simple method of preparing an autologous platelet derivative (Selphyl; Aesthetic Factors, Princeton, NJ) allows rapid and inexpensive generation of a platelet-rich fibrin matrix (PRFM) that can be used to enhance healing after facial procedures as well as to rejuvenate the face without tissue manipulation. PRFM provides autologous, natural, but concentrated platelet growth factor release and stimulation of surrounding tissue. This article describes its use for cosmetic facial applications.

KEYWORDS: Platelets, platelet gel, platelet-rich plasma, platelet-rich fibrin matrix

Platelets are products of megakaryocytes and respond to vascular injury by aggregating. In vivo, platelets attach to nodes of a fibrin scaffold that forms at the site of injury. Platelet activation leads to the development of pseudopods, aggregation, and ultimately platelet degranulation. Alpha granules within the platelets release by exocytosis a multitude of growth factors (GFs), which act as chemoattractants and mitogenic agents. These growth factors include vascular endothelial growth factor (VEGF), platelet-derived growth factor (PDGF), epidermal growth factor (EGF), insulin-like growth factor-1 (IGF-1), basic fibroblast growth factor (bFGF), transforming growth factor- β 1 (TGF- β 1), transforming growth factor α (TGF- α), platelet activating factor (PAF), thrombospondin, platelet thromboplastin, coagulation factors, serotonin, histamine, hydrolytic enzymes, and endostatin.¹ They are released in specific ratios and work both in concert and in a specific order to attract inflammatory cells, fibroblasts, as well as to stimulate collagen deposition

and endothelial budding. These features will lead to appropriate wound healing.

CLINICAL USES OF PLATELET GROWTH FACTORS

The most commonly used and the simplest approach is the direct application of recombinant growth factors. The first to be marketed was PDGF (becaplermin 0.01%; Regranex; Systagenix Wound Management, Inc., London, UK) and is currently in use for treating deep diabetic foot ulcers. Recently, keratinocyte growth factor (KGF; palifermin; Kepivance; Biovitrum AB, Stockholm, Sweden) has been approved for oral mucositis in patients receiving chemotherapy. However, exogenous growth factors applied directly and outside the normal milieu of growth factors may have untoward effects; a black box warning was given to becaplermin by the U.S. Food and Drug Administration (FDA) in 2008, as patients exposed to three or more tubes of becaplermin

¹Director of Facial Plastic Surgery, The New York Eye and Ear Infirmary, New York, New York; and Professor of Otolaryngology, New York Medical College, Valhalla, New York.

Address for correspondence and reprint requests: Anthony P. Sclafani, M.D., F.A.C.S., Director of Facial Plastic Surgery, The New York Eye and Ear Infirmary, 310 East 14th Street, Sixth Floor, North Building, New York, NY 10003 (e-mail: asclafani@nyee.edu).

Management of the Aging Face; Guest Editor, Anthony P. Sclafani, M.D., F.A.C.S.

Facial Plast Surg 2009;25:270-276. Copyright © 2009 by Thieme Medical Publishers, Inc., 333 Seventh Avenue, New York, NY 10001, USA. Tel: +1(212) 584-4662.
DOI 10.1055/s-0029-1242033. ISSN 0736-6825.

had a fivefold increase in cancer mortality. The safety of palifermin in patients with nonhematologic malignancies has not been established.

CLINICAL USES OF PLATELET-RICH PLASMA

In an attempt to better simulate the native wound-healing environment compared with that after isolated growth factor application, concentrated platelet preparations have been used clinically. Most clinically applicable platelet recovery systems have been developed from a perfusion perspective. Erythrocytes are separated from white cells and platelets in distinct fractions and can be used separately. Platelet pellets are resuspended in recovered plasma, usually with 6 or more times the normal concentration of platelets in peripheral blood. This platelet-rich plasma (PRP) is then activated with exogenous calcium and (usually bovine) thrombin. This leads to significant platelet degranulation, releasing massive amounts of all platelet growth factors. This release is substantially higher than naturally stimulated growth factor release, and there is no evidence that the normal sequence or ratio of growth factor concentrations is maintained.

In vitro models have suggested a potential utility of PRP. Kakudo et al² treated human adipose-derived stem cells and dermal fibroblasts with activated or non-activated PRP or platelet-poor plasma (PPP). These workers found an increase in proliferation of stem cells when treated with PRP or PPP activated with calcium and thrombin compared with that after treatment with nonactivated PRP or PPP, as well as with whole blood; human dermal fibroblasts showed increased proliferation when treated with PRP or PPP only if activated. Tellingly, both the stem cells and the dermal fibroblasts showed maximal proliferation at 7 days when treated with a 5% PRP compared with that after treatment with higher or lower concentrations of PRP; these workers concluded that the appropriate GF concentrations are necessary to maximize effects. Choi et al³ also noted that alveolar bone cell proliferation was stimulated by low, but suppressed by high, concentration of PRP.

In an animal model, Sclafani et al⁴ evaluated the cellularity of a porous implant treated at the time of implantation with either PPP, PRP, or autologous blood clot (ABC). ABC- and PRP- treated implants had higher levels of inflammatory cells at 2 days after implantation than that of controls; PRP-treated implants had higher levels of fibroblasts and endothelial cells within the pores of the implant at 7 days after implantation than that of ABC-treated implants, although counts in both were higher than that of controls. However, these higher cell counts were not noted at 14 days or later, suggesting a transient effect of the PRP. Hom et al⁵ treated wounds of the adult thigh with

autologous platelet gel; compared with controls, he noted earlier wound epithelialization, although ultimate cellularity was no different than that of controls. Powell et al⁶ noted a non-significant trend toward less post-operative edema and ecchymosis in hemifaces treated with PRP prior to flap closure during deep plane face-lifting. Others⁷ have failed to show any substantial improvements in vivo using PRP.

CLINICAL USES OF PLATELET-RICH FIBRIN MATRIX

Additional features of the natural wound response include the presence of a fibrin matrix. Fibrin matrices have been shown to enhance the delivery of platelet growth factors.⁸ Indeed, Torio-Padron et al⁹ and Scholler et al¹⁰ noted enhanced survival and differentiation of transplanted preadipocytes when fibrin is coinjected as a carrier material. Clinically, Azzena et al¹¹ and Cervelli and Gentile¹² described treating patients with autologous fat coinjected with platelet-rich fibrin matrix (PRFM) with good results.

In a rabbit model, Nitche et al¹³ found that patellar tendon defects surgically repaired and additionally treated with PRFM showed decreased inflammation, more organized collagen, and increased tensile strength compared with tendons not treated with PRFM after 3 weeks; however, this difference was not noted after 6 weeks. Sánchez et al¹⁴ found that after Achilles' tendon repair in athletes, there was a 30% reduction in time to full range of motion and a 33% shorter time to resumption of training when repair was supplemented with intratendinous injection and tendon covering with a PRFM. Fanelli et al¹⁵ describe the use of PRFM in the repair of posterior collateral ligament injuries. In addition to orthopedic applications, PRFM has been used to accelerate the rate and increase the chance of complete healing of chronic venous leg ulcers.¹⁶

Selphyl PRFM Therapy

Selphyl (Aesthetic Factors, LLC, Princeton, NJ) is an FDA-cleared device consisting of materials needed to produce an autologous PRFM. Blood is drawn from the patient into a vacuum collection tube containing a thixotropic separator gel. When centrifuged for 6 minutes at 1100 RPM, the blood is separated into a supernatant plasma/platelet suspension, with the remaining cells located below the separator gel. The fibrin, platelets, and serum are then transferred aseptically to a second vacuum tube containing a calcium chloride solution. At this point, fibrin polymerization begins, slowly at first but complete in ~10 minutes. Prior to full polymerization, the suspension can easily be injected through a 30-gauge needle. Once this polymerization has occurred, platelets are embedded in this fibrin matrix. These platelets have

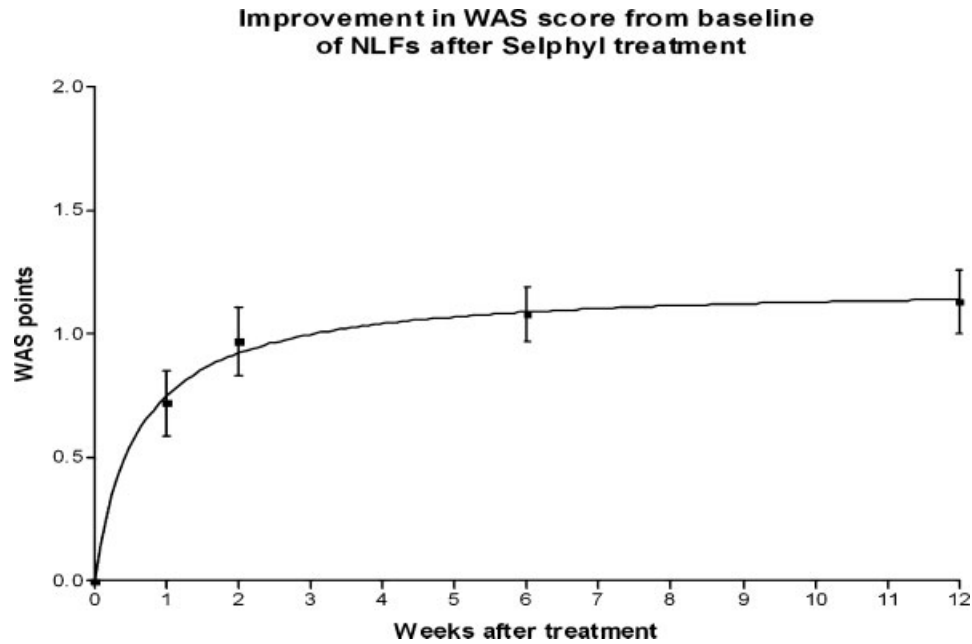


Figure 1 Improvement in Wrinkle Assessment Scale (WAS) score after treatment of the nasolabial folds (NLFs) with Selphyl PRFM.

been shown to be highly viable (59% are viable at 7 days after harvesting) and capable of a sustained release of PDGF-BB, VEGF-A, TGF- β , and IGF-1 over 7 days in vitro; this has been associated with increased endothelial cell proliferation.^{17,18}

PRFM has been used in several clinical settings relevant to facial plastic surgery. The simplicity and portability of the system lends itself well to a variety of office-based or operative applications.

MINIMALLY INVASIVE THERAPIES

Dermal Augmentation Treatment of dermal and subdermal tissues of the nasolabial folds with PRFM has been shown to yield clinically significant improvements within 2 weeks of treatment; these improvements showed no sign of decline over the 3 months of the study (Fig. 1).¹⁹ Publication of a larger study is pending, but this treatment can be used for other areas of soft tissue deficit. The skin of target areas is treated as needed either intradermally (via a 30-gauge needle) or subdermally (via a 27-gauge needle) to maximal correction. There is generally scant ecchymosis and edema, which generally subside within a few days. Significant improvement is usually evident by 1 to 2 weeks after treatment (Fig. 2).

Treatment of Acne Scars Broad-based, atrophic acne scars can be difficult to treat without significant morbidity, and even with invasive procedures such as dermabrasion, results can be disappointing. Acne scar subcision attempts to divide any fibrous bands tethering the base of the scar to the subdermal tissues using a

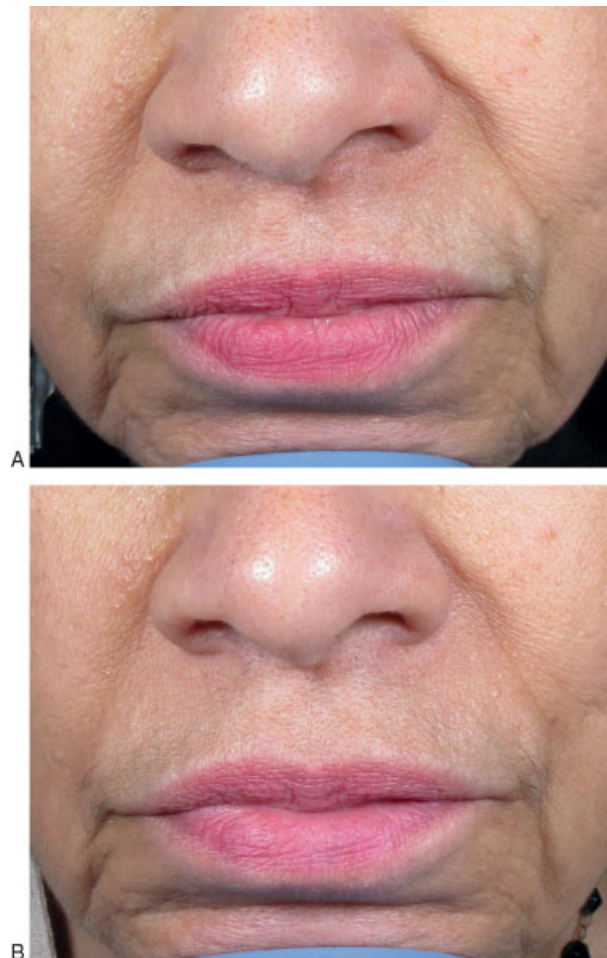

Figure 2 Typical improvement seen after a single Selphyl PRFM treatment of the nasolabial folds. (A) Pretreatment; (B) 12 weeks after treatment.

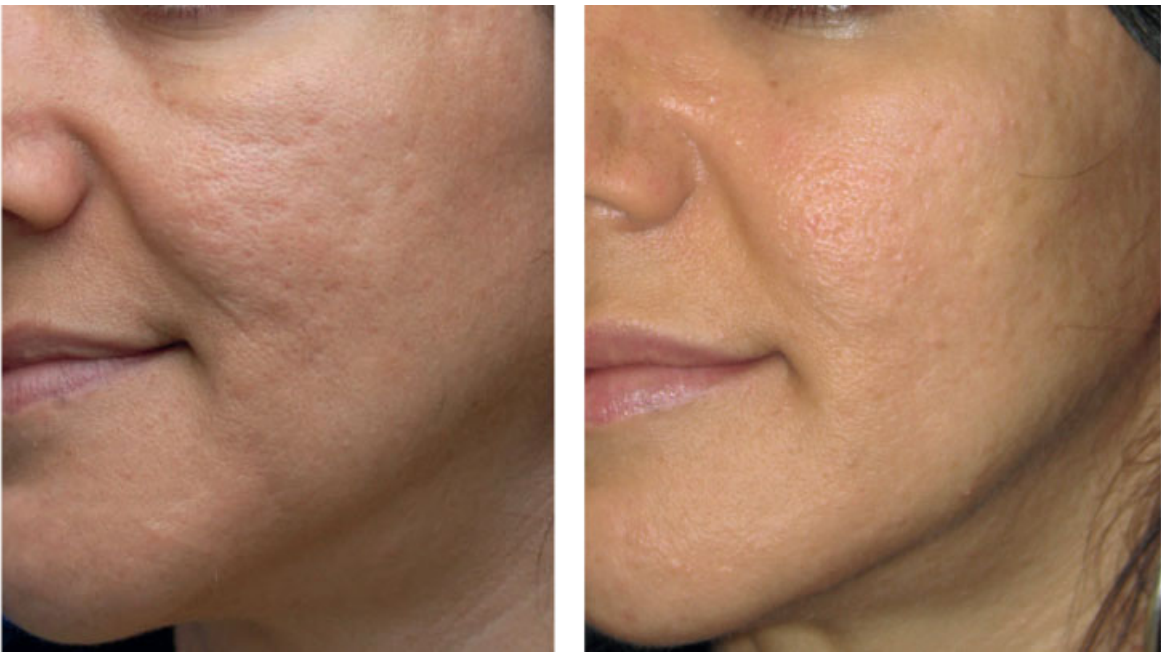

Figure 3 Atrophic acne scars can be treated with subcision and PRFM injection below the subcised scars. (A) Pretreatment; (B) posttreatment.

Nocor needle (Becton, Dickinson & Co., Franklin Lakes, NJ). This technique has been modified to allow for restructuring of the subdermis. A 19-gauge needle is placed on a 3-cc syringe filled with PRFM. The needle is passed through the skin, and the subdermal bands

tethering the base of the acne scars are lysed by sweeping the needle and using the sharp edge to cut through these fibers. Without removing the needle from the skin, the PRFM is then injected into the subdermal plane below the acne scars: 2 cc to 4 cc PRFM is

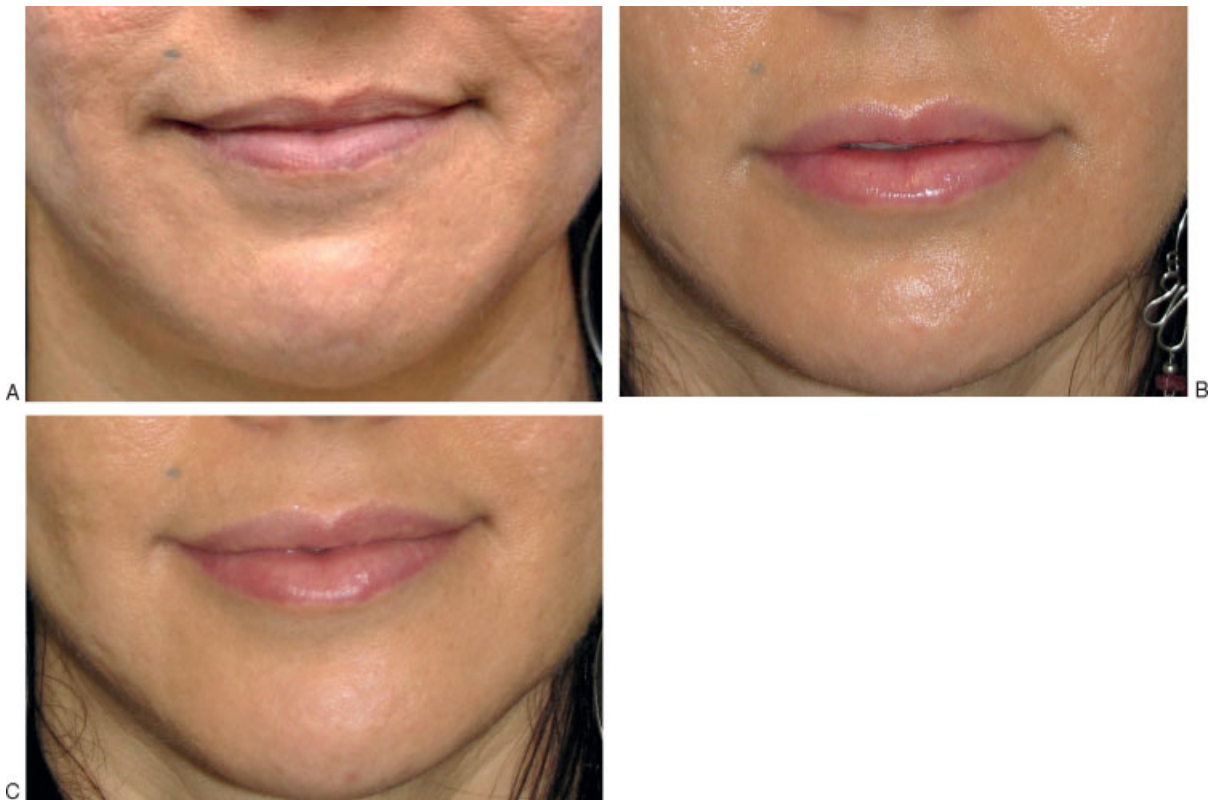

Figure 4 Autologous fat transfer to the lips. Fat was mixed with PRFM in a 2:1 ratio. (A) Pretreatment; (B) 1 week after treatment; (C) 4 weeks after treatment, with little volume loss compared with 1 week posttreatment.

injected below the typical cheek. The area is not massaged, but a cool compress is applied for the next 4 to 6 hours. Similar to the nasolabial fold treatment, there is mild transient edema and generally little ecchymosis. Results can be seen as early as 1 to 3 weeks

after treatment and are substantially better than that after subcision alone (Fig. 3).

Autologous Fat Transfer A central tenet of autologous fat transfer is the gentle and atraumatic handling of

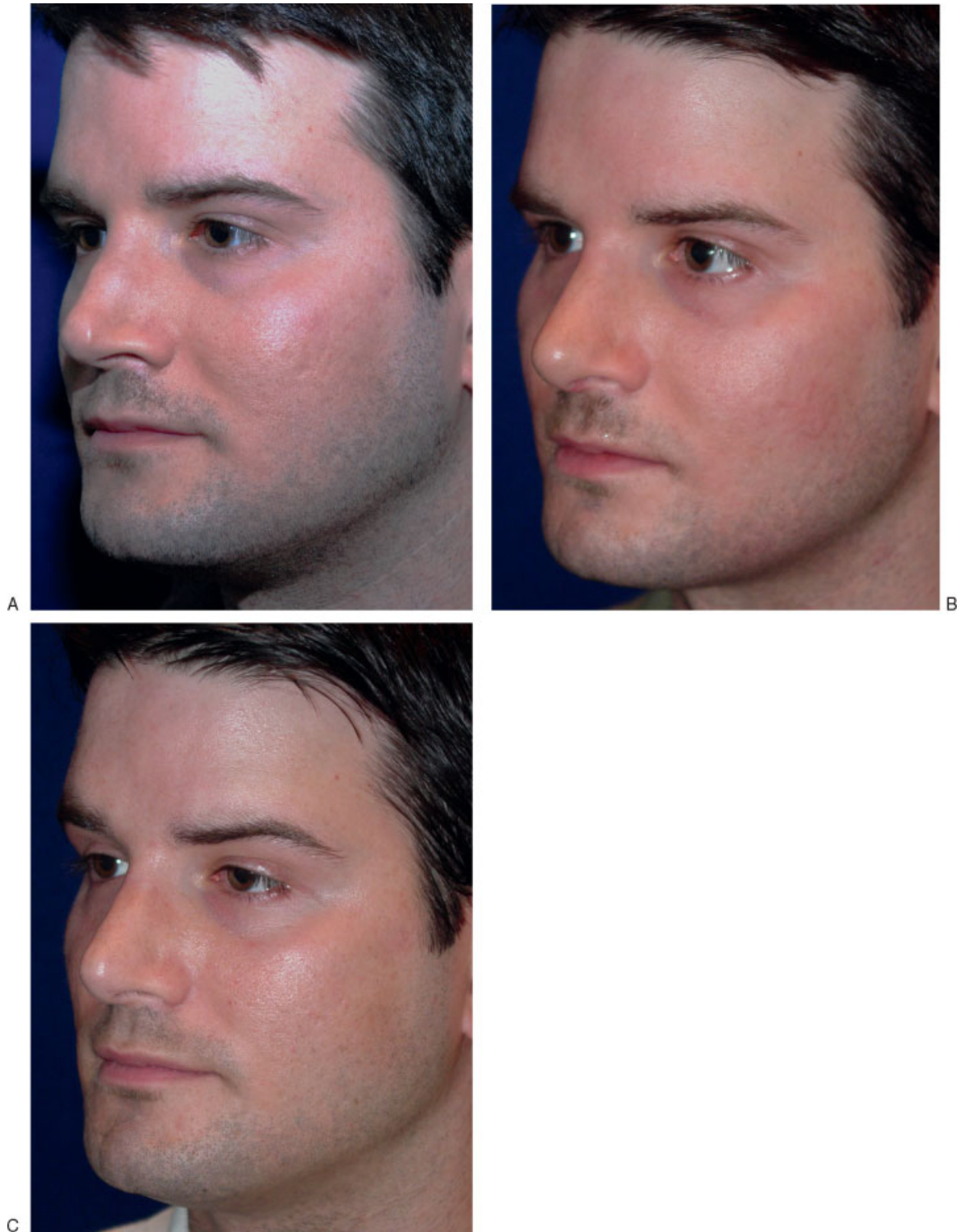

Figure 5 Healing around synthetic implants can be enhanced by treatment with PRFM. (A) Preoperative view of patient undergoing revision open approach rhinoplasty, alloplastic augmentation of the malar arch, and conservative buccal fat pad excision; (B) 1 week after treatment; (C) 5 months after treatment.

fat and placement to allow for rapid revascularization. PRFM can be mixed with autologous fat *ex vivo* and the composite graft injected. Both the fibrin matrix as well as the platelet-released growth factors should promote better graft take as suggested by Azzena et al¹¹ and Cervelli and Gentile.¹² Currently, we aspirate ~0.3 cc of PRFM into a 1-cc syringe first, then transfer autologous fat into this syringe. The fat is then placed into the proper locations via standard technique. Early results are promising, with apparently less ecchymosis and good volume retention (Fig. 4).

INTRAOPERATIVE USES

One of the significant advantages of the Selphyl PRFM system is its simplicity and portability. The system can easily be transferred from the office to the operating room. After the platelet-fibrin suspension is mixed with calcium chloride, the activated PRFM can be sprayed under a skin, face-lift, or myocutaneous flap to promote hemostasis, fibrosis, and angiogenesis. Likewise, I cover facial implants with a layer of PRFM after proper positioning in the implant pocket to accelerate soft tissue enclosure of the pocket and ingrowth into porous implants. Finally, I inject PRFM after lateral osteotomies to reduce ecchymosis after rhinoplasty (Fig. 5).

COMPLICATIONS

I have used Selphyl PRFM in ~100 cases over the past 18 months, both in minimally invasive applications as well as intraoperatively. No patients have complained of nor have I noted at any time nodularity, palpability, or inflammation out of proportion to the general procedure performed. No infections or seromas were noted in any patient. In general, PRFM dermal applications were well-tolerated and had very brief recovery times; intraoperative use of PRFM seemed to be associated with less postoperative edema and ecchymosis, but a large-scale trial is necessary to definitively demonstrate this.

CONCLUSION

PRFM is an autologous treatment with the potential to stimulate natural biologic processes to achieve aesthetic improvements. This system essentially replicates the wound-healing process, but the lack of erythrocytes may assist in bypassing the inflammatory stage. This may lead to an earlier initiation of the proliferative phase, which may explain the relatively early improvements, especially with dermal augmentation. We are currently investigating the histologic changes that occur after treatment of soft tissue with PRFM. As we continue to refine our understanding of the biologic processes that occur with use of platelet-fibrin products, we will be better able to tailor PRFM treatment to each particular application. Based on a firm understanding of the natural wound-healing process, this simple-to-use, inexpensive,

and all-natural treatment is a major addition to the facial plastic surgery armamentarium.

REFERENCES

1. Hom DB. New developments in wound healing relevant to facial plastic surgery. *Arch Facial Plast Surg* 2008;10:402-406
2. Kakudo N, Minakata T, Mitsui T, Kushida S, Notodihardjo FZ, Kusumoto K. Proliferation-promoting effect of platelet-rich plasma on human adipose-derived stem cells and human dermal fibroblasts. *Plast Reconstr Surg* 2008;122:1352-1360
3. Choi BH, Zhu SJ, Kim BY, Huh JY, Lee SH, Jung JH. Effect of platelet-rich plasma (PRP) concentration on the viability and proliferation of alveolar bone cells: an *in vitro* study. *Int J Oral Maxillofac Surg* 2005;34:420-424
4. Sclafani AP, Romo T III, Ukrainsky G, et al. Modulation of wound response and soft tissue ingrowth in synthetic and allogeneic implants with platelet concentrate. *Arch Facial Plast Surg* 2005;7:163-169
5. Hom DB, Linzie BM, Huang TC. The healing effects of autologous platelet gel on acute human skin wounds. *Arch Facial Plast Surg* 2007;9:174-183
6. Powell DM, Chang E, Fariior EH. Recovery from deep-plane rhytidectomy following unilateral wound treatment with autologous platelet gel: a pilot study. *Arch Facial Plast Surg* 2001;3:245-250
7. Danielsen P, Jørgensen B, Karlsmark T, Jørgensen LN, Agren MS. Effect of topical autologous platelet-rich fibrin versus no intervention on epithelialization of donor sites and meshed split-thickness skin autografts: a randomized clinical trial. *Plast Reconstr Surg* 2008;122:1431-1440
8. Anitua E, Sanchez M, Nurden AT, et al. Autologous fibrin matrices: a potential source of biological mediators that modulate tendon cell activities. *J Biomed Mater Res* 2006;77A:285-293
9. Torio-Padron N, Baerlecken N, Momeni A, Stark GB, Borges J. Engineering of adipose tissue by injection of human preadipocytes in fibrin. *Aesthetic Plast Surg* 2007;31:285-293
10. Schoeller T, Lille S, Wechselberger G, et al. Histomorphologic and volumetric analysis of implanted autologous preadipocyte cultures suspended in fibrin glue: a potential new source for tissue augmentation. *Aesthetic Plast Surg* 2001;25:57-63
11. Azzena B, Mazzoleni F, Abatangelo G, Zavan B, Vindigni V. Autologous platelet-rich plasma as an adipocyte *in vivo* delivery system: case report. *Aesthetic Plast Surg* 2008;32:155-158; discussion 159-161
12. Cervelli V, Gentile P. Use of platelet gel in Romberg syndrome. *Plast Reconstr Surg* 2009;123:22e-23e
13. Nitche J, Greco S, Merriam A, et al. Platelet rich fibrin matrix to enhance periarticular tendon to bone healing. Presented at: The American Orthopedic Society for Sports Medicine 2008 Annual Meeting; July 10-13, 2008; Orlando, FL
14. Sánchez M, Anitua E, Azofra J, Andía I, Padilla S, Mujika I. Comparison of surgically repaired Achilles tendon tears using platelet-rich fibrin matrices. *Am J Sports Med* 2007;35:245-251
15. Fanelli GC, Edson CJ, Reinheimer KN. Surgical technique: surgeon details pearls for two PCL reconstruction methods. *Orthoped Today* 2007;27:1-5

16. O'Connell SM, Impeduglia T, Hessler K, Wang X-J, Carroll RJ, Dardik H. Autologous platelet-rich fibrin matrix as cell therapy in the healing of chronic lower-extremity ulcers. *Wound Repair Regen* 2008;16:749-756
17. Carroll RJ, Arnoczky SP, Graham S, O'Connell SM. Characterization of autologous growth factors in Cascade[®] platelet-rich fibrin matrix (PRFM). Edison, NJ: Musculoskeletal Transplant Foundation; 2005;. 128-XM 307C5
18. O'Connell SM, Carroll RJ, Beavis A, Arnoczky SP. Flow cytometric characterization of Cascade[®] platelet-rich fibrin matrix (PRFM): the impact of exogenous thrombin of platelet concentrates (PC). Edison, NJ: Musculoskeletal Transplant Foundation; 2006;. 128-2.5M 406TC1
19. Sclafani AP. Platelet rich fibrin matrix for improvement of deep nasolabial folds. Presented at: The Annual Meeting of the Triological Society; May 28-30, 2009; Scottsdale, AZ