

# Fat Management in Lower Lid Blepharoplasty

Cory C. Yeh, M.D.,<sup>1,2</sup> and Edwin F. Williams III, M.D.<sup>1,2</sup>

## ABSTRACT

Aging of the lower eyelid involves a complex series of anatomic and physiologic changes that occur over time. Rejuvenation of the lower eyelid complex must systemically address the various contributions of soft tissue laxity, pseudoherniation of orbital fat, and loss of periorbital volume. This article outlines the evolution of our approach to lower eyelid blepharoplasty with a specific focus on the importance of management of fat in the periocular region. A discussion of various surgical approaches with their advantages and disadvantages is presented, and the importance of maintaining a safe lower eyelid is emphasized. A comprehensive and systematic approach to restoration of the lower eyelid is highlighted with specific postoperative results.

**KEYWORDS:** Blepharoplasty, orbital fat, lipotransfer, periorbital rejuvenation

Rejuvenation of the lower eyelid has significantly evolved over time. This is due in part to an improved understanding of the anatomic changes associated with aging of the entire lid complex, as well as to a gradual refinement in surgical technique. One of the most critical aspects of lower lid blepharoplasty is the appropriate management of orbital fat and lower eyelid volume loss. The goal of this article is to detail the evolution of our thought process in the comprehensive management of lower eyelid rejuvenation.

Normal lower eyelid anatomy has been described in detail by previous authors.<sup>1</sup> One of the most defining features of a youthful lid is a shorter, fuller eyelid.<sup>2</sup> This is in stark contrast with the aged eyelid, which clinically appears longer and deflated and demonstrates anatomic features such as laxity, loss of volume, and pseudoherniation of orbital fat through a weakened orbital septum. Multiple changes to the intricate anatomy of the lower eyelid occur over time resulting in an aesthetic deformity and the projection of a tired appearance. These changes are thought to be secondary to gravitational descent, changes in periorbital fat, and solar damage of the skin. Laxity of the lower eyelid is common in aging and occurs

due to a weakening of the orbital retaining ligaments and an inferior displacement of the zygomatico-cutaneous ligament (Fig. 1).<sup>3</sup> As with all facial soft tissue, the effect of gravity results in a gradual downward displacement of the entire lower eyelid complex, which is exacerbated by relaxation of these compromised orbital ligaments. As a result, the lower eyelid shows an apparent increase in the vertical lid length. Just as important a concept to understand is the loss of lower eyelid volume. This process is thought to be secondary to atrophy of the lower lid subcutaneous tissue and gravitational descent of both the suborbicularis oculi fat pad (SOOF) and malar fat pad. As a result, the lower eyelid often demonstrates periorbital hollowing, a tear-trough deformity, and a flattened midface. Lastly, the aged eyelid typically demonstrates pseudoherniation of orbital fat through a weakened orbital septum. This results in an unnatural soft tissue convexity over the orbital rim and the classic “bags under the eyes” appearance. The cumulative effects of aging on the lower eyelid are clearly demonstrated (Fig. 2).

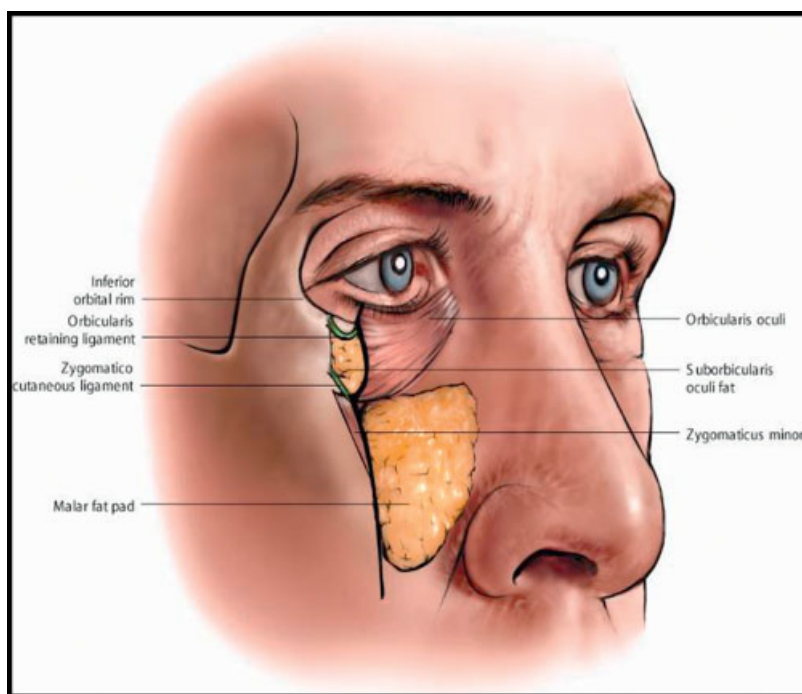
One of our earliest surgical approaches used for lower eyelid blepharoplasty involved a skin-muscle flap

<sup>1</sup>Williams Center Plastic Surgery Specialists, Latham, New York;  
<sup>2</sup>Facial Plastic and Reconstructive Surgery, Department of Surgery, Division of Otolaryngology-Head and Neck Surgery, Albany Medical Center, Albany, New York.

Address for correspondence and reprint requests: Cory C. Yeh, M.D., Williams Center Plastic Surgery Specialists, 1072 Troy-Schenectady Road, Latham, NY 12110 (e-mail: coryyeh@gmail.com).

Management of the Aging Face; Guest Editor, Anthony P. Sclafani, M.D., F.A.C.S.

Facial Plast Surg 2009;25:234–244. Copyright © 2009 by Thieme Medical Publishers, Inc., 333 Seventh Avenue, New York, NY 10001, USA. Tel: +1(212) 584-4662.  
DOI 10.1055/s-0029-1242035. ISSN 0736-6825.



**Figure 1** Anatomic changes in the aged lower lid include a weakened orbital septum, laxity of the orbicularis retaining ligament and zygomatico-cutaneous ligament, and descent of the malar fat pad. (From Defatta RJ, Williams EF. Evolution of midface rejuvenation. *Arch Facial Plast Surg* 2009;11:7. Copyright (2009), American Medical Association. All rights reserved. Reprinted with permission.)

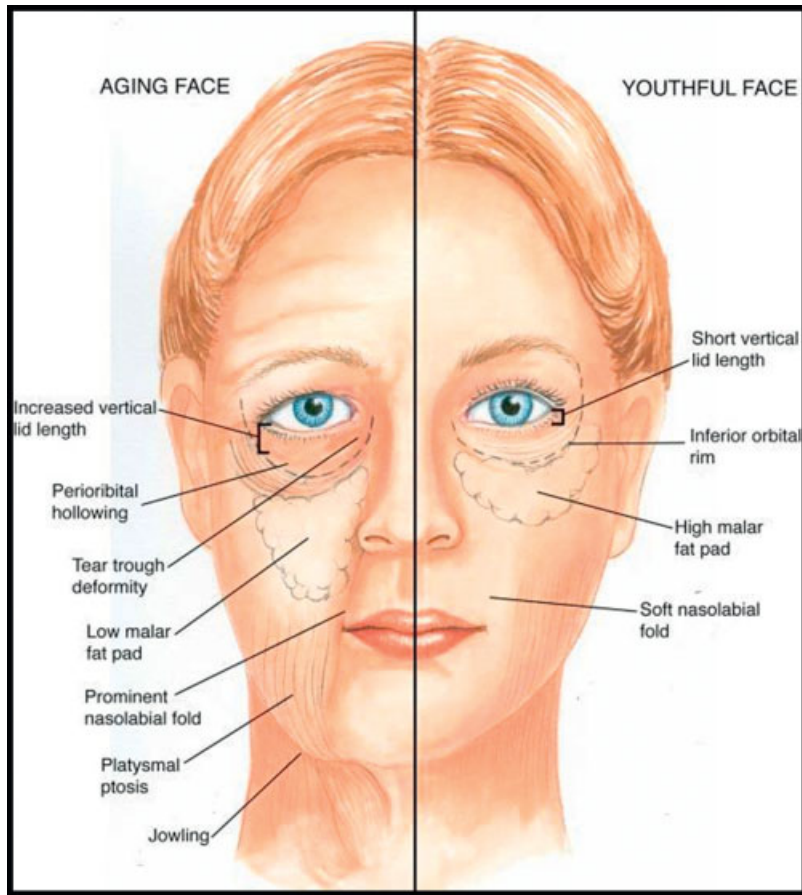
technique. In this approach, a subciliary incision is made ~2 to 3 mm below the eyelid margin and carried medially from within 1 mm of the inferior punctum to a position within 8 to 10 mm lateral to the lateral canthus. A relatively avascular dissection plane is created below the orbicularis muscle down to the infraorbital rim. The pseudoherniated fat pockets are then addressed by removal of fat through the orbital septum, and appropriate amounts of redundant skin and orbicularis muscle are removed prior to closure. Although this procedure is time-tested and still used today by many experienced surgeons, our practice has largely abandoned this technique due to the concern of both immediate and delayed functional lower eyelid impairment.

Many complications after skin-muscle flap lower eyelid blepharoplasty are not unique to this surgical approach but are inherent risks associated with periorbital rejuvenation.<sup>4</sup> Some authors indicate that this surgical technique is safe and effective when performed in a conservative fashion or with routine lateral canthal support.<sup>5,6</sup> However, careful analyses of postoperative photos and long-term patient follow-up have indicated to our group that a skin-muscle flap blepharoplasty approach is associated with a significantly higher rate of cosmetic deformity and functional impairment. Unfavorable aesthetic changes may vary from frank ectropion to scleral show (Fig. 3). Other changes such as subtle lower eyelid rounding may not be appreciated by the patient but are easily recognized by the experienced surgeon critical of his or her results (Fig. 4). Whereas all

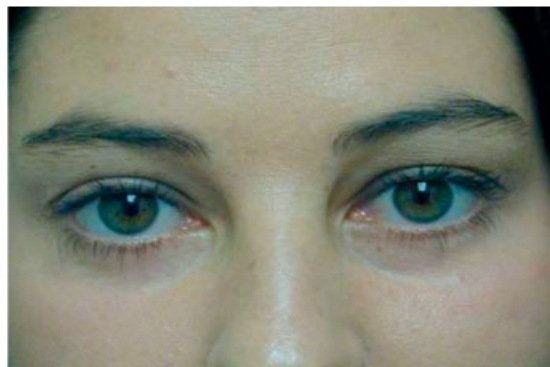
of these various manifestations of lower eyelid malposition are cosmetically unfavorable, even more concerning is the long-term functional impairment of normal eyelid physiology. Conditions such as epiphora and dry eyes may plague our patients in their senior years at the expense of earlier cosmetic improvement achieved through a skin-muscle flap approach (Fig. 5).

Revisiting the physiologic forces on lower eyelid position helped to bridge a transition to a transconjunctival blepharoplasty approach. Forces that facilitate a downward displacement of the lower eyelid include lid edema, gravitational pull of soft tissue, atrophy of the lacrimal gland, middle lamellar scar and/or insufficient anterior lamella from prior blepharoplasty, and denervation of the orbicularis muscle that occurs with a skin-muscle flap approach. These forces are counterbalanced by the anatomic and physiologic forces that hold the lower eyelid up. These favorable forces include an intact orbicularis muscle, the inherent strength of the tarsal-orbicularis canthal sling, and compensatory surgical maneuvers such as suspension of the lateral canthus and midface. In an effort to shift the balance toward an upward vector pull over downward lower eyelid displacement, our practice used a transconjunctival lower eyelid blepharoplasty approach on most patients for almost 10 years.

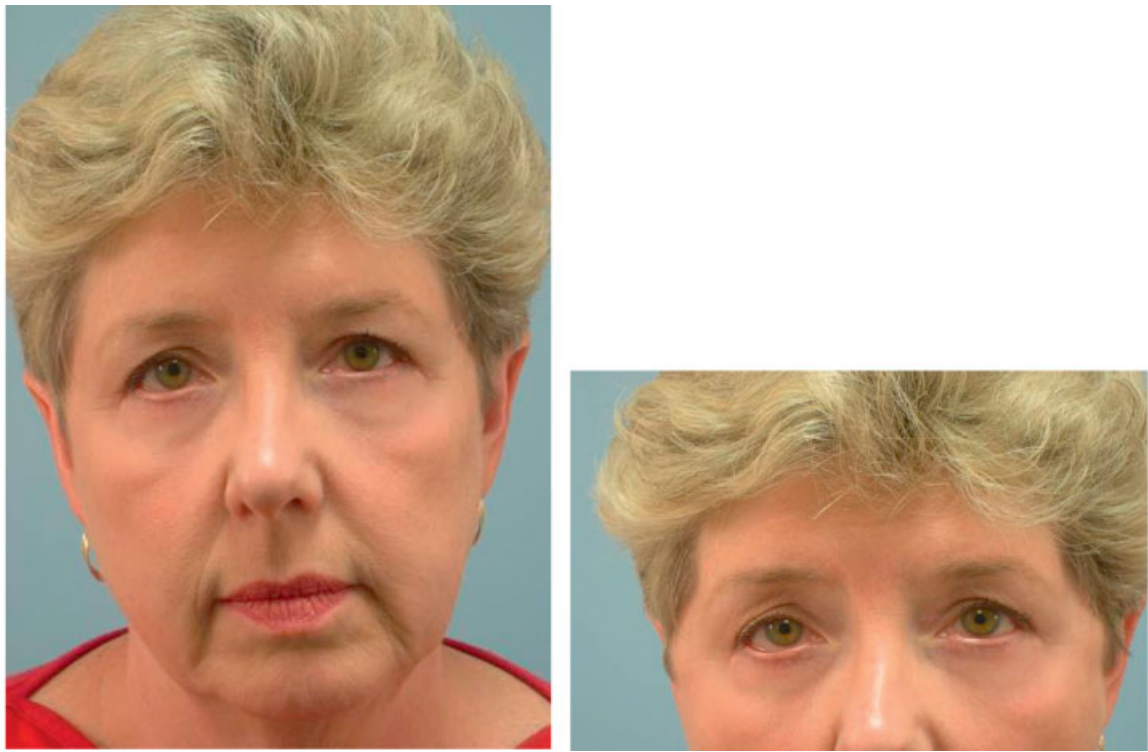Transconjunctival lower eyelid blepharoplasty was first described in 1924 by Bourquet. It is a well-established surgical approach that when properly performed respects the integrity of the orbicularis oculi muscle, avoids an external scar, and minimizes lower eyelid



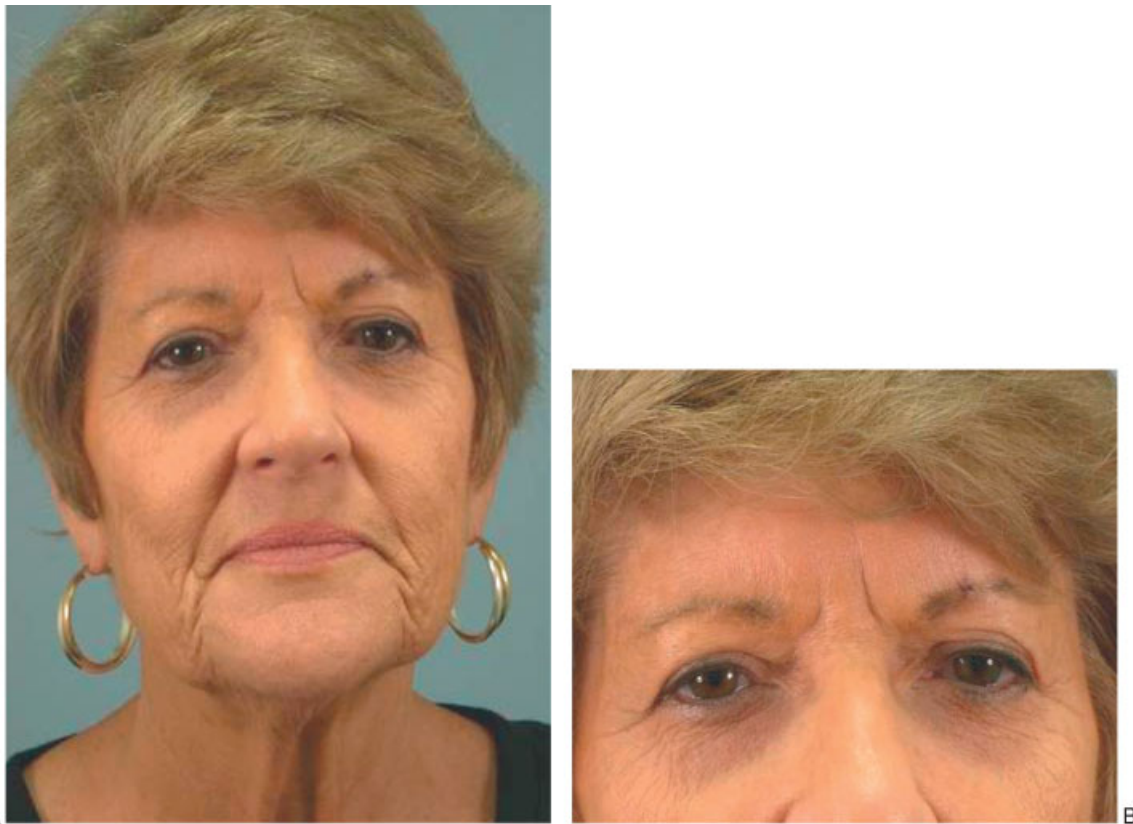**Figure 2** Comparison of the cumulative effects of aging on the lower lid and midface complex. In youth, the lower lid appears short and full with a gentle convexity over the infraorbital rim. In contrast, an aged lid demonstrates an increase in vertical lid height, a double convexity due to pseudohermiation of orbital fat and malar fat ptosis, and a loss of volume over the infraorbital rim. (From Defatta RJ, Williams EF. Evolution of midface rejuvenation. Arch Facial Plast Surg 2009;11:9. Copyright (2009), American Medical Association. All rights reserved. Reprinted with permission.)



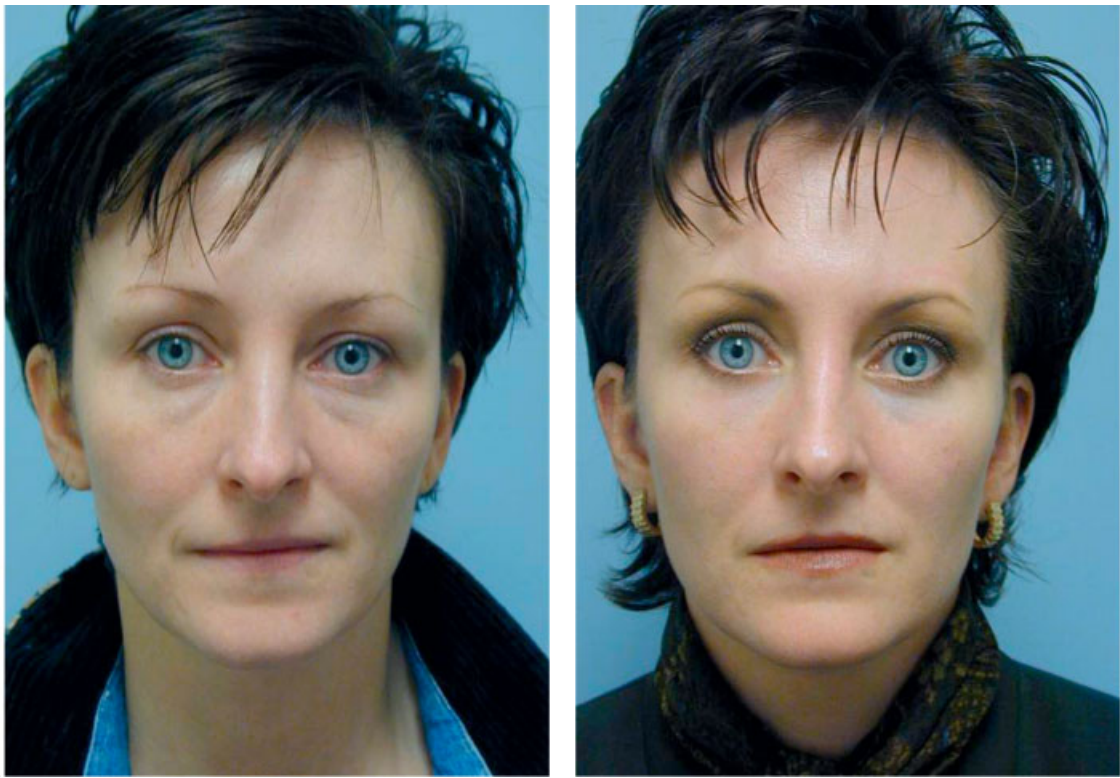**Figure 3** (A) A 30-year-old woman who underwent a skin-muscle flap blepharoplasty by another surgeon demonstrates bilateral scleral show and mild skeletonization of the orbit. (B) A close-up photograph of the eyes of the same woman in Fig. 3A.



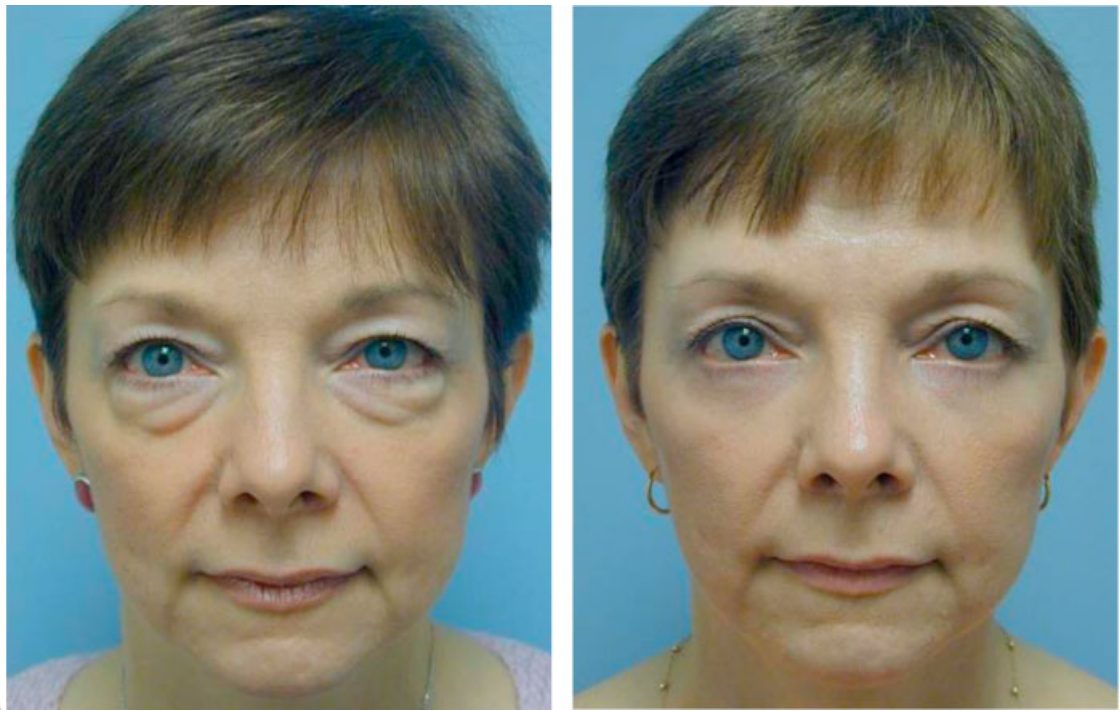**Figure 4** (A) A woman 2 months after a skin-muscle flap blepharoplasty who demonstrates right lower eyelid malposition and rounding secondary to scar contracture. (B) A close-up photograph of the eyes of the same woman in Fig. 4A.



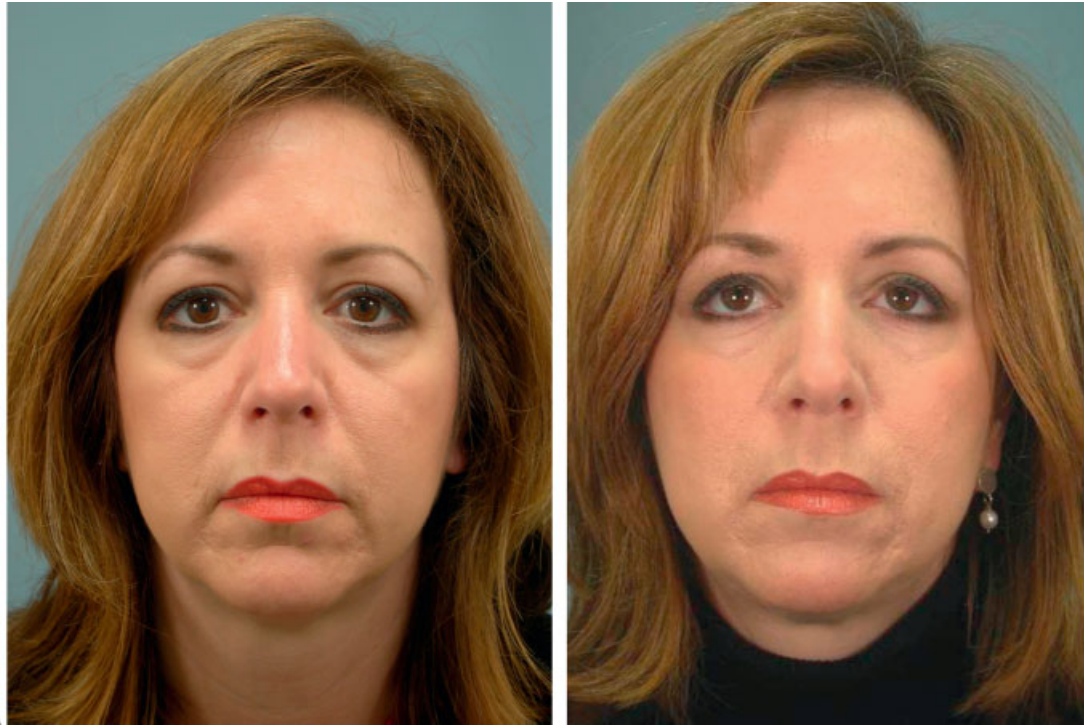**Figure 5** (A) A woman 5 years after a skin-muscle flap blepharoplasty who is pleased with her cosmetic results but complains of severe dry eyes bilaterally. (B) A close-up photograph of the eyes of the same woman in Fig. 5A.



**Figure 6** (A) Preoperative photograph of a woman who demonstrates mild lower lid and midface volume loss. (B) Postoperative photograph at 1 year after transconjunctival blepharoplasty.



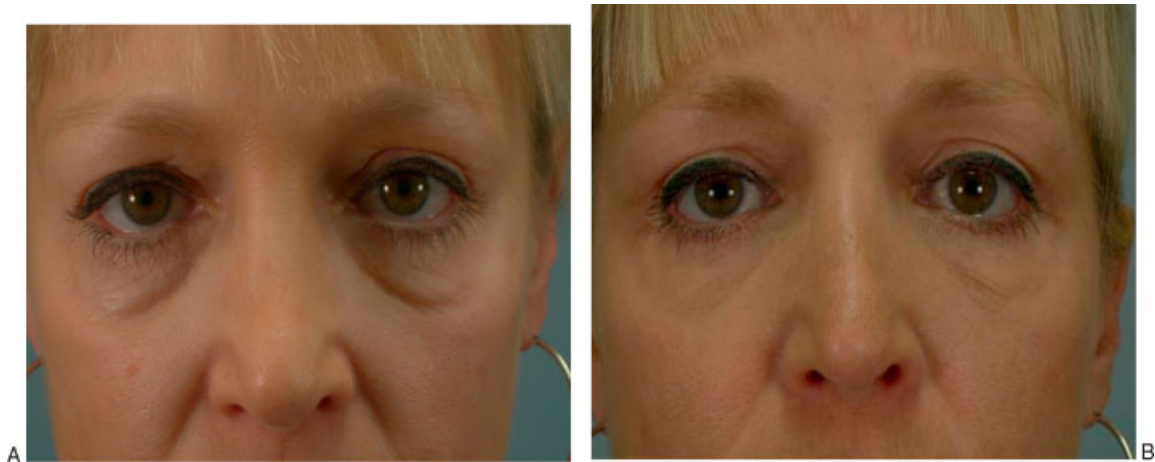
**Figure 7** (A) Preoperative photograph of a woman who demonstrates significant pseudohermiation of the orbital fat bilaterally. (B) Postoperative photograph at 1 year after transconjunctival blepharoplasty.



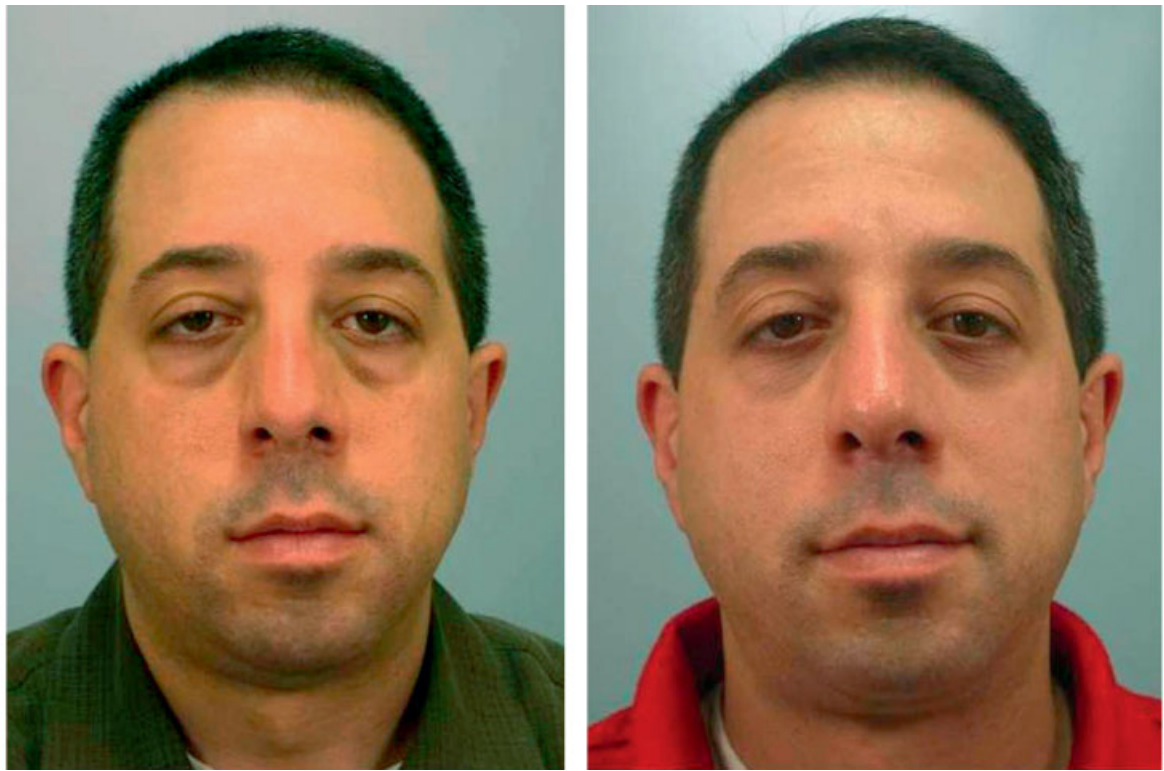
**Figure 8** (A) Preoperative photograph of a woman who demonstrates moderate pseudoherniation of the orbital fat and mild lower lid and midface volume loss. (B) Postoperative photograph at 1 year after transconjunctival blepharoplasty.

malposition. Results of lower eyelid rejuvenation from an isolated transconjunctival blepharoplasty approach certainly reveal an aesthetic improvement of the lower lid. Although in our hands this proved to be a safer operation with equally efficacious results compared with those of a skin-muscle flap technique, it has since become clear that the best candidates for an isolated transconjunctival blepharoplasty are those patients that have either minimal upper midface volume loss/ptosis (Fig. 6) or significant amounts of pseudoherniation of the lower eyelid orbital fat (Figs. 7 and 8).

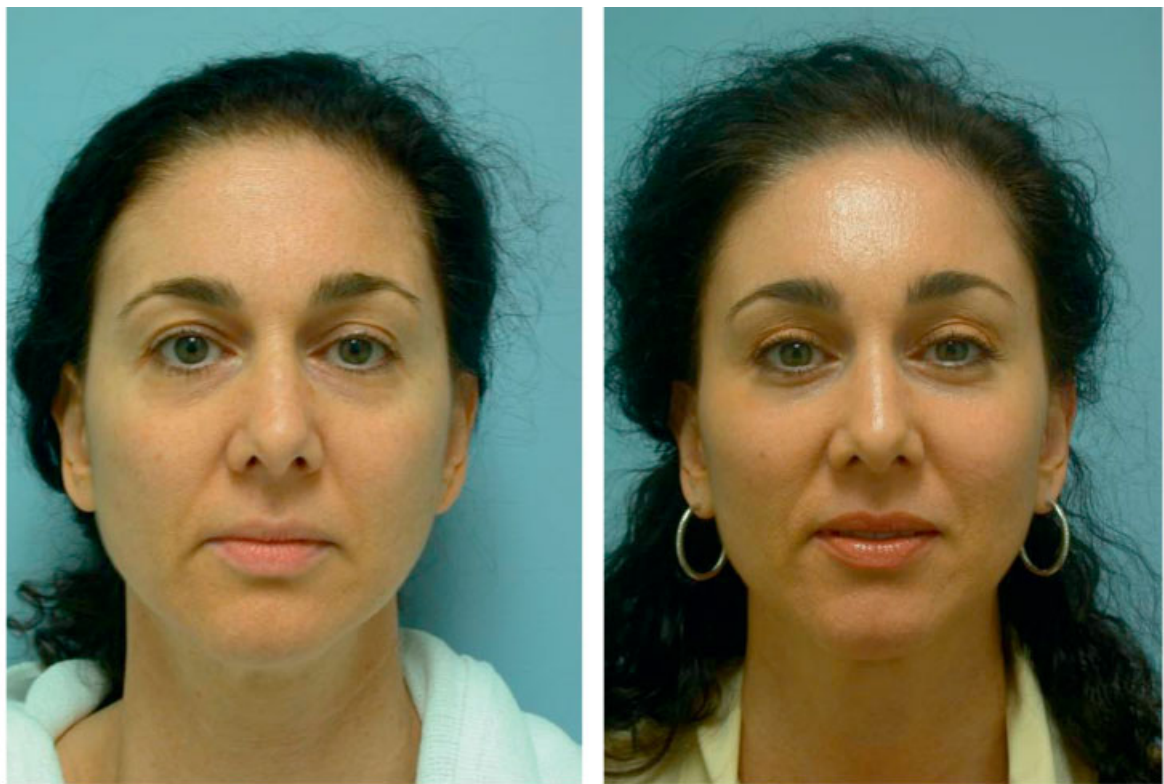With time, the limitations of a transconjunctival blepharoplasty for lower eyelid rejuvenation were better appreciated. Critical review of postoperative results demonstrated an improvement in reducing the double convexity associated with pseudoherniated orbital fat as well as a smoother contour to the lower eyelid complex. Yet, the persistence of the lower eyelid periorbital shadow and partial skeletonization of the infraorbital rim were features that demanded an alternative conceptual approach to periorbital rejuvenation (Figs. 9 and 10). As a result, some surgeons returned to a skin-muscle flap technique



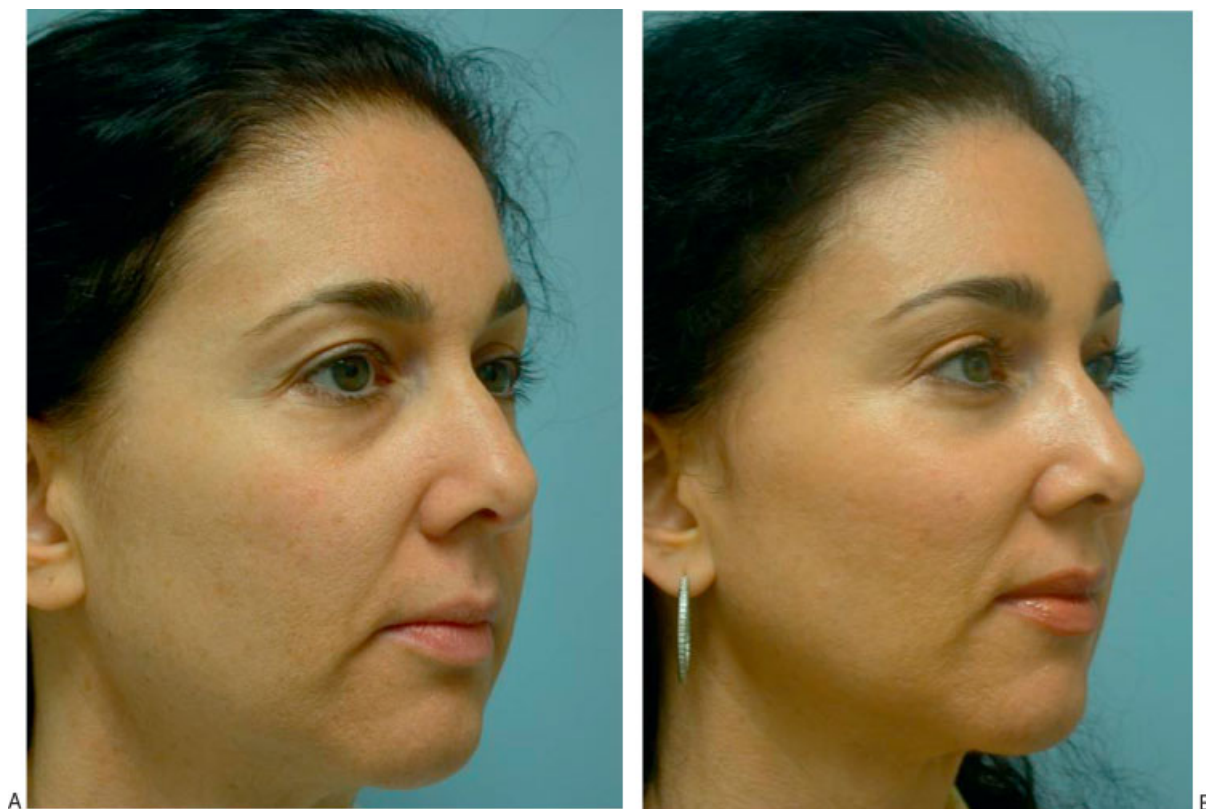**Figure 9** (A) Preoperative photograph of a woman who demonstrates significant lower eyelid aging. (B) Postoperative photograph at 1 year after transconjunctival blepharoplasty shows improvement but demonstrates a persistent aesthetic deformity due to uncorrected lower eyelid volume loss.



**Figure 10** (A) Preoperative photograph of a man with significant periorbital aging thought to be secondary to pseudoherniation of orbital fat. (B) Postoperative photograph at 1 year after transconjunctival blepharoplasty shows improvement after reduction of pseudoherniated fat but demonstrates a suboptimal result due to persistent periorbital volume loss.



**Figure 11** (A) Preoperative photograph of a woman with lower lid and midface aging. (B) Postoperative photograph at 1 year after subperiosteal midface lifting without blepharoplasty demonstrates an improved lower lid contour due to resuspension of the entire midface complex.



**Figure 12** (A) Preoperative oblique photograph of the same woman in Fig. 11A. (B) Postoperative oblique photograph at 1 year of the same woman in Fig. 11B demonstrates an improved lower lid contour in the absence of a blepharoplasty procedure.

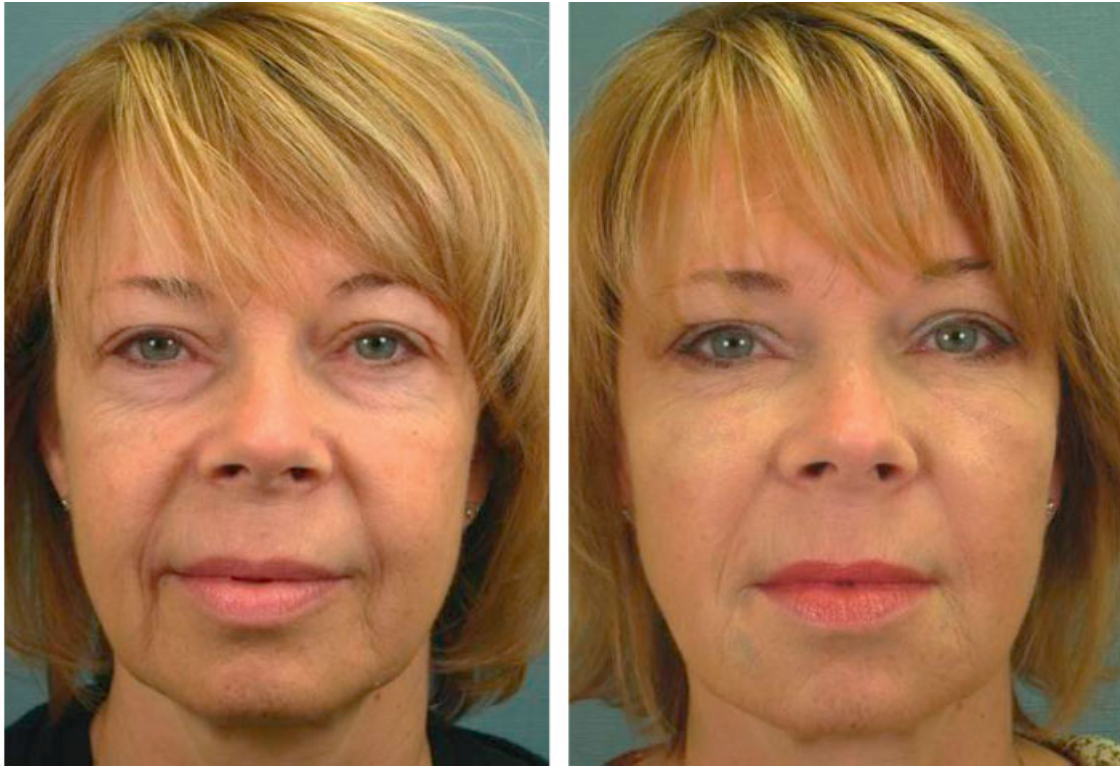to move the periorbital shadow up and create a superolateral vector pull on the lower lid. Others turned to a SOOF lift or transposition of orbital fat to improve lower lid contouring.<sup>7,8</sup> In our practice, experience with subperiosteal midface lifts for facial rejuvenation demonstrated an apparent improvement in periorbital rejuvenation even in the absence of a blepharoplasty procedure (Fig. 11). This is thought to be secondary to elevation of the malar fat pad and suspension of soft tissue over the infraorbital rim.<sup>9</sup> As a result, the lower eyelid appears shorter and fuller (Fig. 12).

The most recent evolution of our thought process on lower eyelid rejuvenation has developed over the past few years. With techniques employed to address pseudoherniation of the orbital fat without risking lower eyelid malposition through a transconjunctival blepharoplasty approach and other approaches designed to address descent of the lower eyelid and midface tissue through subperiosteal midface lifting, attention was then turned to the problem of lower eyelid volume loss. With the advent of injectable dermal fillers, some patients with isolated periorbital volume loss achieved improvements in lower eyelid rejuvenation that rivaled prior blepharoplasty results (Figs. 13 and 14). This experience advanced our understanding of changes in lower eyelid anatomy and revealed that periorbital volume loss was

just as important a contributor to lower lid aging as soft tissue descent and pseudoherniation of orbital fat.

To address lower eyelid volume loss, our practice turned to periorbital lipotransfer. Indications for this technique include evidence of fat atrophy with the appearance of a prominent infraorbital rim, skeletonization of the orbit, and a prominent tear-trough deformity. In this technique, autogenous fat is harvested from a donor site, typically either the abdomen or thighs, with a standard liposuction cannula under low-pressure hand suction. The fat is then prepared under sterile conditions by centrifugation to remove the supernatant components of lysed fat cells, tumescent solution, and blood. The fat is then injected transcutaneously to the lower eyelid and midface complex with small lipotransfer cannulas.<sup>10</sup> In our experience, problems such as fat granulomas and contour irregularities are largely avoided through careful attention to surgical technique. These considerations include slow delivery of the fat to the lower eyelid complex with avoidance of deposition of larger fat boluses in one particular area and minimizing the delivery of fat to the superficial plane above the orbicularis oculi muscle.<sup>11</sup> Results of lipotransfer to the lower eyelid are impressive in restoration of periorbital volume, particularly in those patients who are significantly volume depleted (Figs. 15 and 16). Complications of

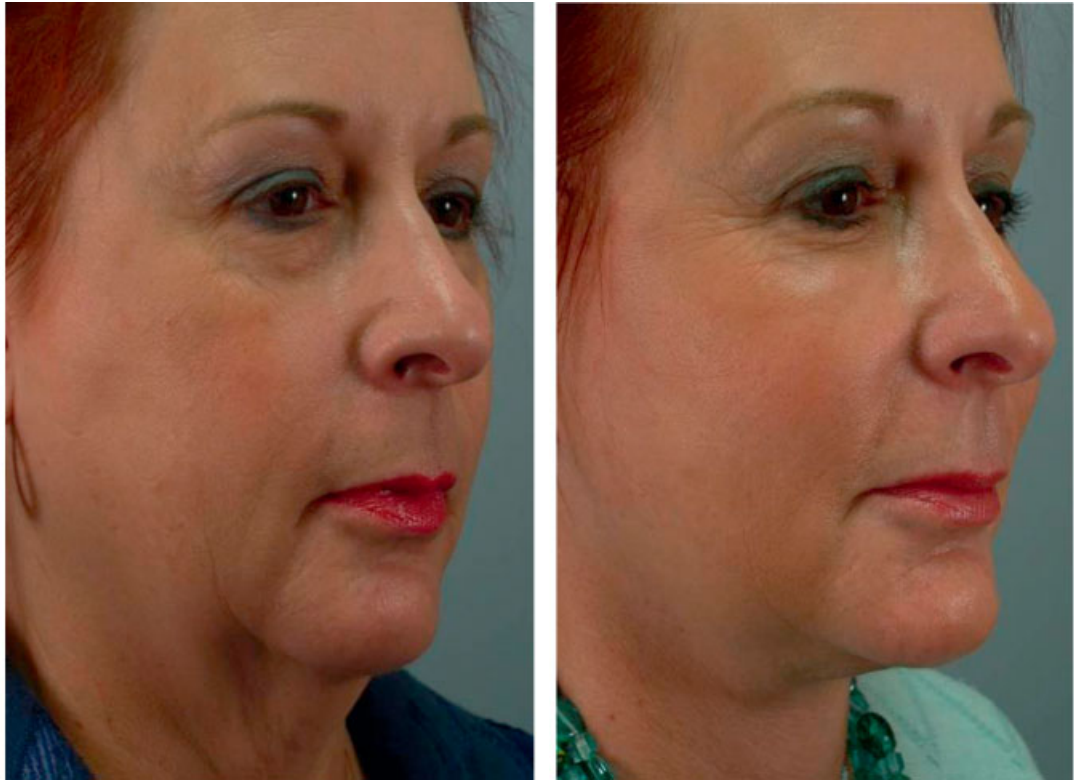



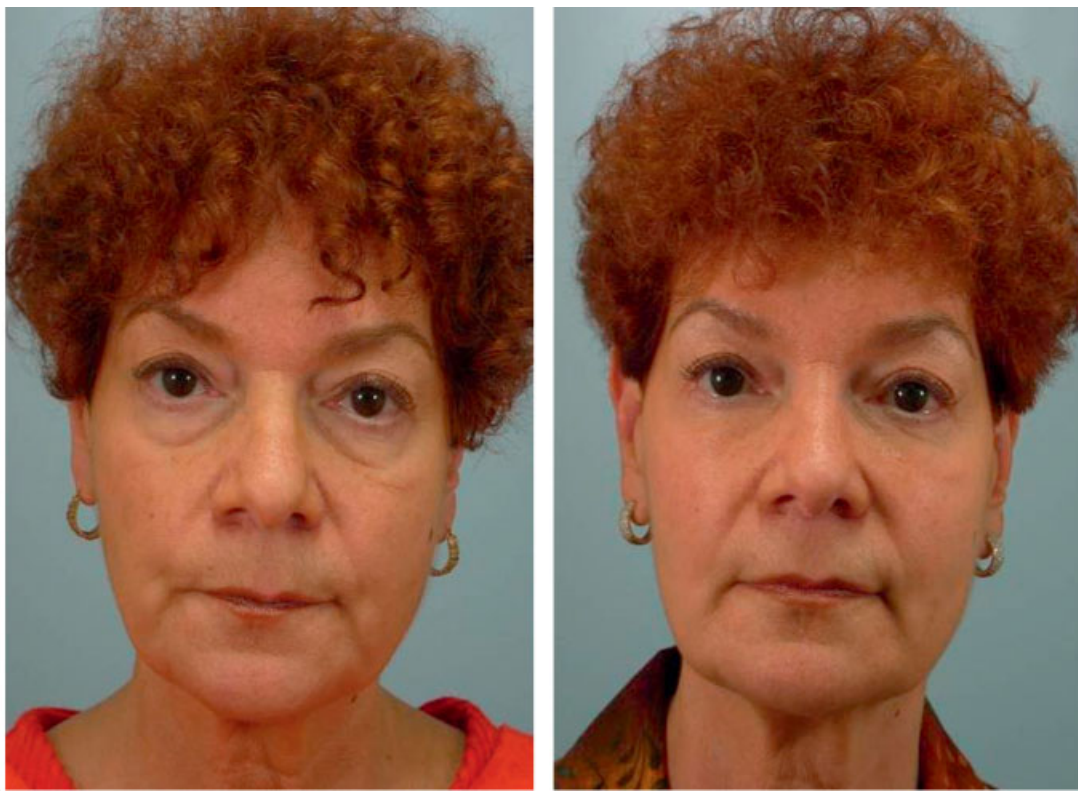**Figure 13** (A) Preprocedure photograph of a woman with moderate periorbital volume loss. (B) Postprocedure photograph after injection of 4 mL Radiesse (Bioform Medical Inc., San Mateo, CA) to the lower eyelids, nasolabial folds, and marionette lines.



**Figure 14** (A) Preprocedure photograph of a woman with moderate periorbital volume loss. (B) Postprocedure photograph after injection of 2 mL Radiesse (Bioform Medical Inc.) to the lower eyelid and midface complex.



**Figure 15** (A) Preoperative oblique photograph of a woman with significant periorbital volume loss and skeletonization of the orbit. (B) Postoperative photograph at 1 year after lipotransfer to the lower eyelid demonstrates restoration of a youthful lower eyelid contour.



**Figure 16** (A) Preoperative photograph of a woman with significant periorbital volume loss and skeletonization of the orbit. (B) Postoperative photograph at 1 year after lipotransfer to the lower eyelid demonstrates cosmetic improvement through periorbital volume restoration.

fat transfer are typically mild and include edema, bruising, undercorrection, overcorrection, visible fatty deposits, and formation of fat granulomas.

Our experience with lipotransfer to the lower eyelid and midface complex offers a complementary approach to periorbital rejuvenation as well as several distinct advantages over available dermal filler agents. One advantage includes a reduction in the rejection of the implanted material as autogenous fat is typically better tolerated than synthetic dermal fillers. Yet, most modern dermal filler agents demonstrate high rates of tissue tolerance because they are derived from ubiquitous tissue components such as hyaluronic acid or calcium hydroxyapatite. Other more significant advantages include the potential for longer-lasting effects and that more volume can be easily obtained from fat harvesting, which permits the injection of larger volumes if needed.<sup>12</sup>

Currently, our approach to periorbital rejuvenation includes a comprehensive and systemic approach to restore the individual patient's anatomic deficiencies. As previously mentioned, we favor a transconjunctival lower eyelid blepharoplasty approach if patients demonstrate pseudoherniation of orbital fat or significant orbital fat asymmetry. If there is redundant lower eyelid skin with periorbital rhytides, we will perform a skin pinch to the lower eyelid with simultaneous laser resurfacing. For patients with concomitant midface ptosis that contributes significantly to periorbital aging, we favor a subperiosteal midface lift to resuspend this tissue. In most patients, however, periorbital volume loss is not only the major contributor to lower eyelid aging but often is the first anatomic change that can be seen in the thirties and forties. For these patients, periorbital lipotransfer is a highly effective technique to correct volume depletion.

In conclusion, the key to achieving successful lower eyelid rejuvenation on a consistent basis is through a thorough understanding of the complex effects of aging on lower eyelid anatomy. Once the individual patient's deficiencies are identified, a systematic approach to restoration of the periorbital complex can be

planned and executed. Careful attention paid to the individual contributions of soft tissue descent, pseudoherniation of orbital fat, and volume loss will dictate the surgical approaches and maneuvers necessary to achieve successful lower eyelid rejuvenation.

## REFERENCES

1. Rankin BS, Arden RL, Crumley RL. Lower eyelid blepharoplasty. In: Papel I, Frodel J, Holt G, et al, eds. *Facial Plastic and Reconstructive Surgery*. 2nd ed. New York, NY: Thieme Medical Publishers; 2002:196–207
2. Hamra ST. A study of the long-term effect of malar fat repositioning in face lift surgery: short-term success but long-term failure. *Plast Reconstr Surg* 2002;110:940–951; discussion 952–959
3. DeFatta RJ, Williams EF III. Evolution of midface rejuvenation. *Arch Facial Plast Surg* 2009;11:6–12
4. Morax S, Touitou V. Complications of blepharoplasty. *Orbit* 2006;25:303–318
5. Garcia RE, McCollough EG. Transcutaneous lower eyelid blepharoplasty with fat excision: a shift-resisting paradigm. *Arch Facial Plast Surg* 2006;8:374–380
6. Codner MA, Wolff JN, Anzarut A. Primary transcutaneous lower blepharoplasty with routine lateral canthal support: a comprehensive 10-year review. *Plast Reconstr Surg* 2008;121:241–250
7. Freeman MS. Transconjunctival sub-orbicularis oculi fat (SOOF) pad lift blepharoplasty: a new technique for the effacement of nasojugal deformity. *Arch Facial Plast Surg* 2000;2:16–21
8. Nassif PS. Lower blepharoplasty: transconjunctival fat repositioning. *Otolaryngol Clin North Am* 2007;40:381–390
9. Marotta JC, Quatela VC. Lower eyelid aesthetics after endoscopic forehead midface-lift. *Arch Facial Plast Surg* 2008;10:267–272
10. Pontius AT, Williams EF III. The evolution of midface rejuvenation: combining the midface-lift and fat transfer. *Arch Facial Plast Surg* 2006;8:300–305
11. Ciuci PM, Obagi S. Rejuvenation of the periorbital complex with autologous fat transfer: current therapy. *J Oral Maxillofac Surg* 2008;66:1686–1693
12. Coleman SR. Long-term survival of fat transplants: controlled demonstrations. *Aesthetic Plast Surg* 1995;19:421–425