

Management of benign intrahepatic bile duct strictures: initial experience with polydioxanone biodegradable stents

Benign biliary strictures are challenging to manage. They often affect young patients, and although they have a good long-term prognosis, they frequently recur and patients remain at risk of life-threatening cholangitis and liver cirrhosis. Older patients may not be fit for surgery or multiple procedures, but permanent stent insertion has a poor outcome.

Balloon dilation often only results in short-term improvement. Long-term patency can be improved by “splinting” the stricture endoscopically with multiple plastic stents [1], but biliary dilation is extremely painful and repeated endoscopic retrograde cholangiopancreatography (ERCP) is expensive and associated with significant morbidity. Temporary stenting with removable metal stents is a promising new strategy [2], however, these require removal.

A new biodegradable stent theoretically allows long-term dilatation without the need for removal. It is woven from a monofilament of specially treated polydioxanone (► Fig. 1), a resorbable suture and implant material that has been in use for over 20 years [3].

Degradation occurs by hydrolysis [4]. The monofilament loses 50% of its breaking strength after 3 weeks and is absorbed within 6 months [5]; a reduced pH hastens hydrolysis. Larger stent versions are already available for benign esophageal strictures. We describe the first use of 10-mm stents in the biliary tree.

Two patients (74 and 70 years) who had undergone bilioenteric anastomosis for stone disease presented 2 years after surgery with intrahepatic biliary strictures causing new stone formation and chronic cholangitis. Percutaneous balloon dilation, cholangioscopy, and lithotripsy were carried out and biodegradable Ella-DV biliary stents (ELLA-CS, Hradec Králové, Czech Republic) inserted to prevent stricture recurrence (► Figs. 2–6).

The patients developed transient cholangitis as stent fragments were passed three months later. However, no further intervention was required, and 2 years after




Fig. 1 A 10-mm diameter Ella-DV stent.

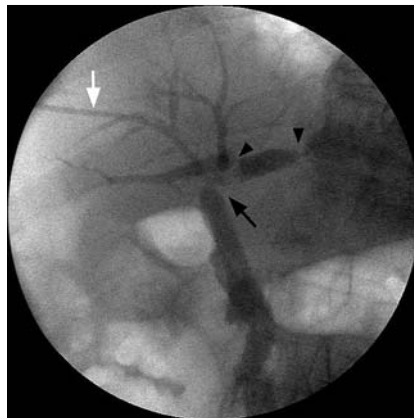


Fig. 2 Percutaneous transhepatic cholangiogram: injection through a right-sided biliary catheter (white arrow) shows a short stricture in the left hepatic duct above the bifurcation (arrow) with filling defects caused by stones above it (arrowheads).

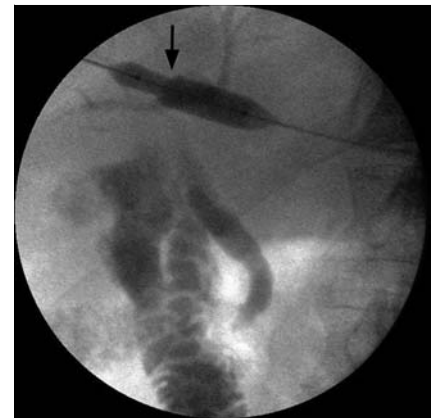

Fig. 3 Balloon dilation of the stricture. Note the shouldering of the balloon where it exits from the percutaneous sheath (arrow).

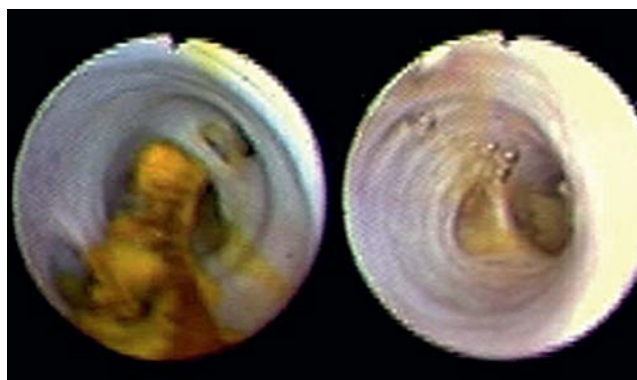


Fig. 4 Cholangioscopy before and after lithotripsy.

implantation the patients remain asymptomatic with normal liver function.

The optimal aftercare to prevent cholangitis at stent disintegration needs further investigation, but initial results regarding stent insertion and stricture patency are encouraging.

Acknowledgment

▼ The treatment was supported by a state grant from the Ministry of Industry and Trade of the Czech Republic (Project IMPULS, project no.: FI-IM2/108).

Endoscopy_UCTN_Code_TTT_1AR_2AZ

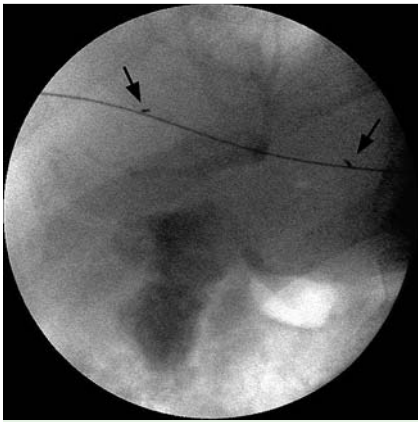


Fig. 5 Introduction of the stent delivery system. The stent is radiolucent, but identified by the radiopaque markers (arrows).

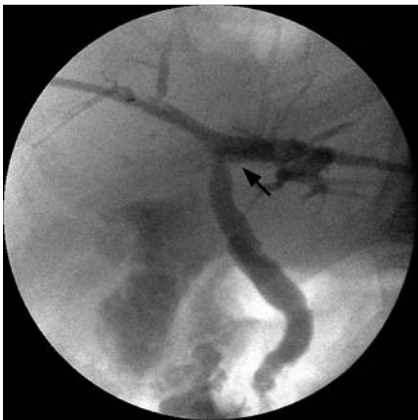

Fig. 6 Deployed stent. The site of the stricture is fully dilated (arrow) and there is free drainage of the contrast through the mesh of the stent into the common bile duct and duodenum.

J. Petrtýl¹, R. Brůha¹, L. Horák²,
Z. Zádorová³, J. Doseděl⁴, H.-U. Laasch⁵

¹ 1st Faculty of Medicine, Charles University, Prague, 4th Department of Internal Medicine, General Teaching Hospital, Prague, Czech Republic

² 3rd Faculty of Medicine, Charles University, Prague, Department of General Surgery, Faculty Hospital Kralovske Vinohrady, Prague, Czech Republic

³ 3rd Faculty of Medicine, Charles University, Prague, 2nd Department of Internal Medicine, Faculty Hospital Kralovske Vinohrady, Prague, Czech Republic

⁴ Department of Internal Medicine, Hospital of Saint Charles of Boromej, Prague, Czech Republic

⁵ Department of Radiology, The Christie NHS Foundation Trust, Manchester, UK

References

- 1 Costamagna G, Shah SK, Tringali A. Current management of postoperative complications and benign biliary strictures. *Gastrointest Endosc Clin N Am* 2003; 13: 635–648
- 2 Gwon DI, Shim HJ, Kwak BK. Retrievable biliary stent-graft in the treatment of benign biliary strictures. *J Vasc Interv Radiol* 2008; 19: 1328–1335
- 3 Ray JA, Doddi N, Regula D et al. Polydioxanone (PDS), a novel monofilament synthetic absorbable suture. *Surg Gynecol Obstet* 1981; 153: 497–507
- 4 Sabino AM, Gonzales S, Marquez L, Feijoo JL. Study of the hydrolytic degradation of polydioxanone PPDx. *Polym Degrad Stab* 2000; 69: 209–216
- 5 Middleton JC, Tipton AJ. Synthetic biodegradable polymers as medical devices. *Medical Plastics and Biomaterials* 1998; 3: 30–39

Bibliography

DOI 10.1055/s-0029-1243880

Endoscopy 2010; 42: E89–E90

© Georg Thieme Verlag KG Stuttgart · New York · ISSN 0013-726X

Corresponding author

Dr. H.-U. Laasch, MRCP, FRCR

Consultant Radiologist

The Christie NHS Foundation Trust

Wilmslow Road

Manchester M20 4BX

UK

Fax: +44 161 4468505

HUL@christie.nhs.uk