

An unusual case of pinworm infection

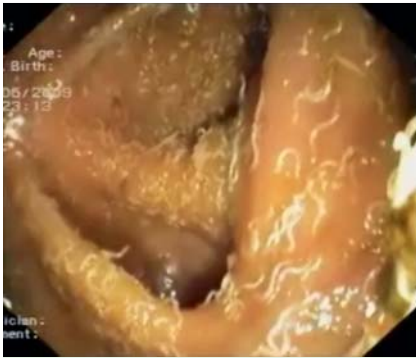

Fig. 1 Pinworm in the sigmoid colon.

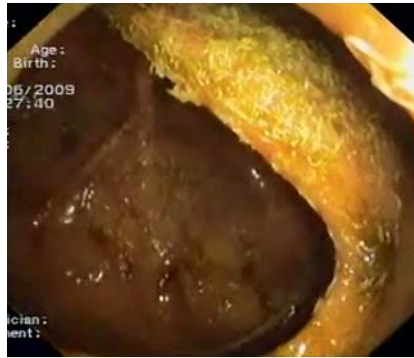

Fig. 2 Pinworm near the ileocecal valve.

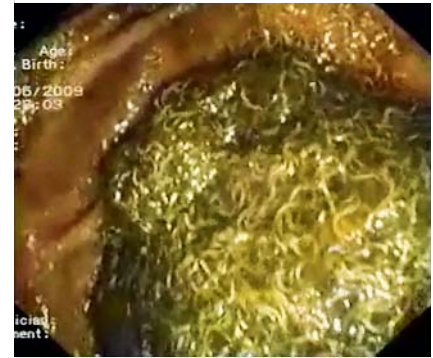


Fig. 3 Pinworm "bezoar" in the right colon.

We report the case of a 45-year-old female, who was observed in a gastroenterology outpatient clinic with a history of abdominal pain and a positive fecal occult blood test. Physical examination was unremarkable. Colonoscopy was performed, and countless pinworms were identified (● Fig. 1, 2). In the right colon they were observed as a cluster around some feces, resembling a bezoar (● Fig. 3, 4, 5, ● Video 1).

Enterobiasis is the name given to pinworm infection by *Enterobius vermicularis*. These parasites are nematodes of less than 15 mm in length and which infect the intestine of mammals, particularly primates, including humans. It is the only parasitic disease that is still common today in developed countries, particularly among children. We present this case for its rarity and curiosity of the images collected.

Video 1

Countless pinworms in the colon.

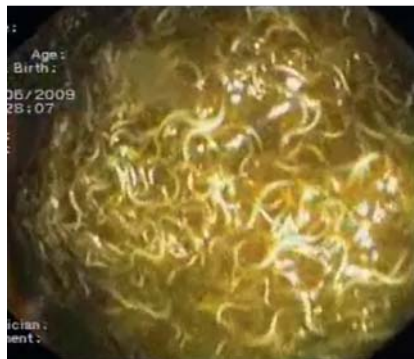


Fig. 4 Pinworm "bezoar" in the right colon.

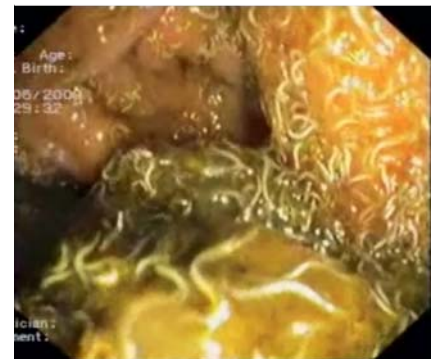


Fig. 5 Pinworm "bezoar" in the right colon.

**R. Araújo, A. Silva, J. Machado,
A. Ramalho, A. Castanheira,
E. Cancela, P. Ministro**
Gastroenterology Department,
St Teotónio Hospital, Viseu, Portugal

Bibliography

DOI 10.1055/s-0029-1244153
Endoscopy 2010; 42: E155
© Georg Thieme Verlag KG Stuttgart · New York ·
ISSN 0013-726X

Corresponding author

R. N. C. Araújo, MD
Gastroenterology Department,
St Teotónio Hospital
Rua da Mata Mansa 191 3º Posterior
3500-899 Viseu
Portugal
Fax: +351-232-420591
Ricardocaraujo@gmail.com

Competing interests: None

Endoscopy_UCTN_Code_CCL_1AD_2AZ