Suture material in the common bile duct causing recurrent post-cholecystectomy pain

A 55-year-old woman presented with recurrent biliary colic for the past 10 months. She had undergone an open cholecystectomy with common bile duct (CBD) exploration 14 months prior to presentation. Transabdominal ultrasound revealed a dilated CBD (11 mm), with echogenic material in lower third of the duct. Her complete blood counts and liver function tests were normal. An endoscopic retrograde cholangiography (ERC) also showed a dilated CBD but no filling defects (**Fig. 1 a**).

A biliary sphincterotomy and a balloon sweep revealed no stones, and despite this procedure the patient had recurrence of colic with cholangitis. A repeat ultrasound revealed a persistently dilated CBD (9.6 mm) with a stone measuring ~ 3 × 2 mm in its terminal intrapancreatic part. On repeat ERC with diluted contrast, the cholangiogram revealed a rounded filling defect in the terminal CBD (**Fig. 1 b**). Balloon and basket extraction revealed two surgical sutures with knots in situ (**Fig. 1 c**). Macroscopic and microscopic examination of the multifilament suture material was suggestive of silk (**Fig. 2 a – d**).

Following the extraction of the sutures the patient remains asymptomatic.

Surgical nonabsorbable sutures can act as a nidus for symptomatic CBD stones [1]. However, migrated suture material per se, without stone formation, causing symptoms has been reported in only one patient in the English-language literature [2]. Silk sutures are absorbed and degraded slowly over a period of ~ 2 years via a foreign body reaction [3]. Migration into the CBD is associated with necrosis and erosion of tissue layers of the cystic duct (CyD) stump either by the tight ligature and the foreign body reaction [4] or by pressure from the adjacent tissues, causing inversion of the CyD-stump into the CBD lumen with subsequent FBR causing suture migration [5]. Our patient started having colic about ~ 4 months after surgery, when the suture must have migrated into the CBD. Our report highlights the advantages of absorbable sutures for CyD ligation and use of diluted contrast for better visualization of intraluminal CBD materials/stones on cholangiography.

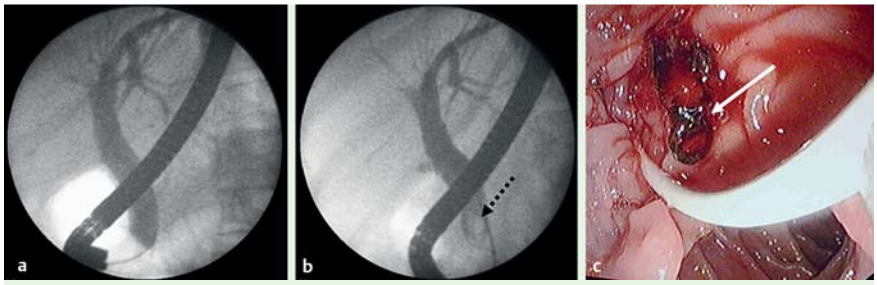

Fig. 1 **a** The initial cholangiogram failed to show filling defects; **b** Cholangiogram showing rounded filling defect in the terminal common bile duct (dashed arrow); **c** Surgical suture with knot in situ extracted with a balloon (arrow).

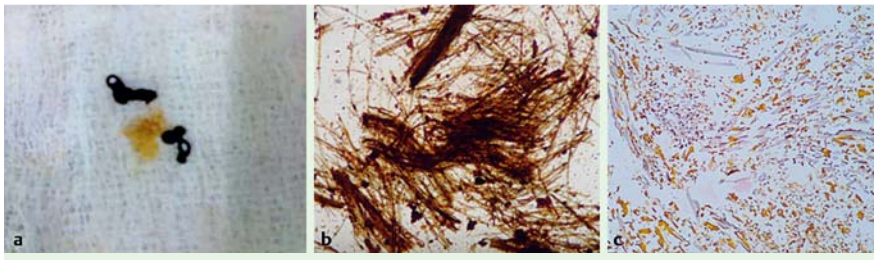

Fig. 2 **a** Extracted surgical silk sutures with knots in situ. **b** Microscopic examination showing the multifilament bile-stained partially degraded silk threads. **c** Associated sludge and cholesterol crystals.

Competing interests: None

Endoscopy_UCTN_Code_CCL_1AZ_2AI

K. Das[1], K. Basu[2], S. Ray[1], S. Chatterjee[2]

[1] Division of Gastroenterology, School of Digestive and Liver Diseases, IPGMER, Kolkata, India

[2] Division of Gastrointestinal Pathology, School of Digestive and Liver Diseases, IPGMER, Kolkata, India

References

1 *Ban JL, Hirose FM, Benfield JR.* Foreign bodies of the biliary tract: report of two patients and a review of the literature. Ann Surg 1972; 176: 102 – 107

2 *Rees BI, Jacob G.* Silk sutures in the common bile duct. Br Med J 1977; 4: 1265

3 *Altman GH, Diaz F, Jakuba C et al.* Silk based biomaterials. Biomaterials 2003; 24: 401 – 416

4 *Newman CE, Hamer JD.* Non-absorbable cystic duct ligatures and common bile duct calculi. Br Med J 1975; 4: 504

5 *Kitamura K, Yamaguchi T, Nakatani H et al.* Why do cystic duct clips migrate into the common bile duct? Lancet 1995; 346: 965 – 966

Bibliography

DOI 10.1055/s-0030-1255655

Endoscopy 2010; 42: E258

ISSN 0013-726X

Corresponding author

K. Das

Division of Gastroenterology

School of Digestive and Liver Diseases

IPGMER

Kolkata

dockdas@gmail.com