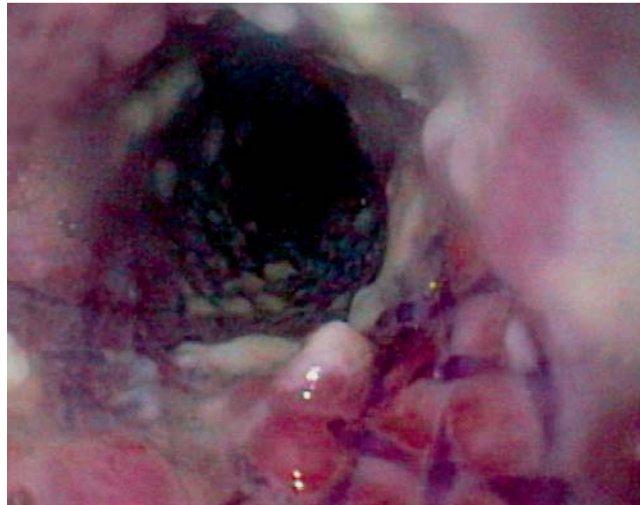


## Tracheoesophageal fistula following implantation of a biodegradable stent for a refractory benign esophageal stricture

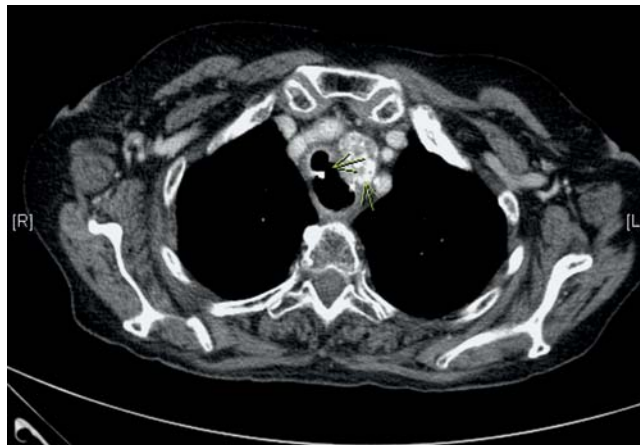Besides repeated dilatations, biodegradable esophageal stents provide a new alternative in the treatment of patients with benign refractory esophageal stenoses. Despite encouraging preliminary results published in a small series of case reports [1–4], potential complications of biodegradable stents, like those seen with self-expandable plastic stents (SEPS) and self-expandable metallic stents (SEMS), have not been addressed yet. We report for the first time the development of a tracheoesophageal fistula after placement of a biodegradable esophageal stent for benign refractory esophageal stenosis.

Seven months after curative radiochemotherapy for a squamous cell carcinoma of the esophagus (cT4N2M0) at 22–33 cm from the mouth, a 66-year-old woman developed a symptomatic esophageal stenosis, at a distance from the mouth extending from 25 to 28 cm. Over a period of 3 years, symptomatic relief was achieved by serial esophageal dilatations (n = 13) employing Savary-Miller bougies (24–45 Fr). During the following year, however, the symptom-free intervals gradually decreased to a few weeks, with progressively worsening dysphagia. Repeated biopsies taken during the whole treatment period remained negative, which suggested that a tumor recurrence was unlikely.

We decided to treat the patient's symptoms by using a biodegradable stent (800 mm, width 30–25–30 mm; Nicolai, Langenhagen, Germany), which was placed without complications at a 19–31 cm distance from the mouth. Besides slight pain and regurgitation directly after stent placement, the patient reported no other complaints. Correct stent position and a free passage were confirmed endoscopically at day 1 and day 27 after stenting. Four weeks after stent placement, however, the patient started complaining about rapidly progressive dysphagia with an inability to swallow solid food, and an unintentional loss of body weight of 5 kg over the period. Control esophagoscopy confirmed the correct position of the stent (● Fig. 1).



**Fig. 1** Esophagoscopy on day 43 after placement of the biodegradable stent.

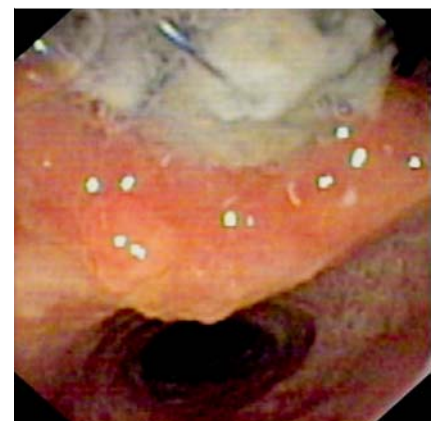


**Fig. 2** Computed tomography (CT) scan showing a tracheoesophageal fistula on the upper edge of the stent.

Only a little granulating tissue was present at the stent site and there was no evidence of stent degradation. A computed tomography (CT) scan performed on the same day, however, revealed a tracheoesophageal fistula at the upper end of the stent (● Fig. 2) without evidence of tumor recurrence.

Bronchoscopy confirmed the fistula with protrusion of the proximal part of the stent into the trachea.

To occlude the fistula, a covered tracheal stent (Leufen ST05-10218060; Leufen Medical GmbH, Aachen, Germany) of 18 × 600 mm was placed, which led to immediate clinical success. After 3 months, complete degradation of the stent was observed endoscopically. The patient was



**Fig. 3** Three-month follow-up after placement of a covered tracheal stent over the tracheoesophageal fistula. The fistula persisted without signs of regression.

symptom free, but the fistula persisted without signs of regression (● Fig. 3). Although the fistula was controlled symptomatically after placement of a covered tracheal stent, this severe stent-related complication, reported here for the first time, should lead to a cautious application of this type of biodegradable stent in benign esophageal strictures.

**Competing interests:** None

Endoscopy\_UCTN\_Code\_CPL\_1AH\_2AD

**G. E. Jung<sup>1</sup>, P. Sauer<sup>2</sup>, A. Schaible<sup>3</sup>**

<sup>1</sup> Surgical Department, Heidelberg University Hospital, Heidelberg, Germany

<sup>2</sup> Interdisciplinary Endoscopic Centre (IEZ), Department of Gastroenterology, Heidelberg University Hospital, Heidelberg, Germany

<sup>3</sup> Interdisciplinary Endoscopic Centre (IEZ), Surgical Department, Heidelberg University Hospital, Heidelberg, Germany

## References

- 1 *Siersema PD*. Stenting for benign esophageal strictures. *Endoscopy* 2009; 41: 363–373 [Epub 2009 Apr 1]
- 2 *Saito Y, Tanaka T, Andoh A et al*. Usefulness of biodegradable stents constructed of poly-l-lactic acid monofilaments in patients with benign esophageal stenosis. *World J Gastroenterol* 2007; 13: 3977–3980
- 3 *Saito Y, Tanaka T, Andoh A et al*. Novel biodegradable stents for benign esophageal strictures following endoscopic submucosal dissection. *Dig Dis Sci* 2008; 53: 330–333 [Epub 2007 Aug 23]
- 4 *Tanaka T, Takahashi M, Nitta N et al*. Newly developed biodegradable stents for benign gastrointestinal tract stenoses: a preliminary clinical trial. *Digestion* 2006; 74: 199–205 [Epub 2007 Mar 6]

## Bibliography

**DOI** 10.1055/s-0030-1256005

*Endoscopy* 2010; 42: E338–E339

© Georg Thieme Verlag KG Stuttgart · New York · ISSN 0013-726X

## Corresponding author

**G. E. Jung, MD**

Surgical Department

Heidelberg University Hospital

Im Neuenheimer Feld 110

69120 Heidelberg

Germany

Fax: +49-6221-568904

Tel.: +49-162-2999435

Gregor.Jung@med.uni-heidelberg.de