An improved method for nasojejunal feeding tube placement in patients requiring endoscopic nasobiliary drainage

Enteral nutritional support is economical, simple, safe, and effective, and is an essential component of the treatment of patients with severe diseases [1]. The most common method of enteral nutrition is through nasojejunal tube placement [2,3]. There are several methods of nasojejunal feeding tube placement (NFTP) [4], with endoscopic placement currently the most common because it is effective, quick, and comparatively successful [5].

To avoid a second endoscopy for NFTP in patients undergoing endoscopic nasobiliary drainage (ENBD), we studied an improved NFTP method. For patients undergoing ENBD, we placed a nasojejunal feeding tube (NFT) as follows. After a line of silk suture was placed around the NFT guide wire (**Fig. 1 a**), the guide wire was inserted into the top of the NFT (**Fig. 1 b**) to connect the nasobiliary tube and NFT loosely using a loop of the line (**Fig. 1 c, d**). The NFT was inserted into the duodenum along the nasobiliary tube. After the guide wire was removed, the loop was retained at the nasobiliary tube, thereby removing the connection between the NFT and nasobiliary tube (**Fig. 1 e**). The NFT was partially inserted again; if bile could not be extracted from the NFT and a small amount of saline could be injected without resistance, the NFT was fixed. If necessary, the location of the NFT could be confirmed by radiographic imaging (**Fig. 2**).

Improved NFTP can be applied to ENBD patients who are unable or unwilling to take food by mouth, especially those with severe pancreatitis due to bile duct disease who require long-term fasting, or patients with postoperative bile leakage or common biliary duct stones, and cardiac dysfunction patients who refuse food. For patients with ENBD, the improved method is a safer, easier, more effective and practical method of enteral nutrition than the endoscopic method, and deserves general adoption in clinical work.

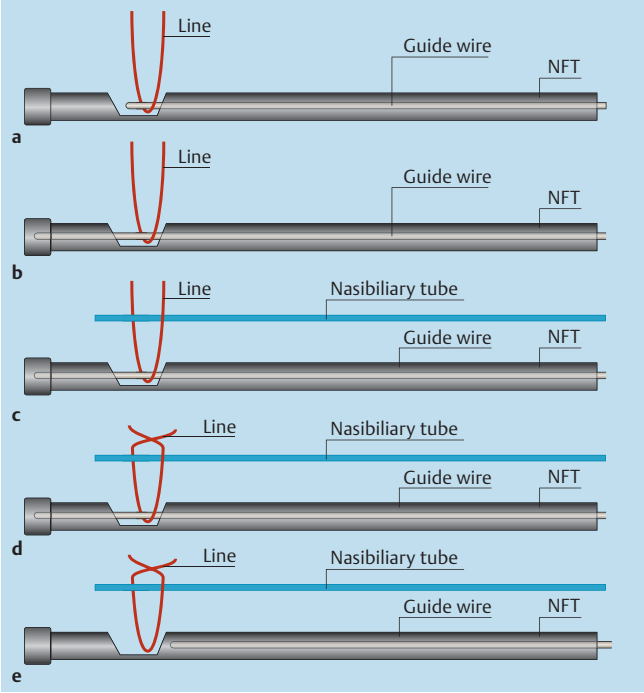

Fig. 1 The steps in the placement of the nasojejunal feeding tube (NFT). **a** The line is placed around the NFT guide wire. **b** The guide wire is inserted into the top of the NFT. **c** The line surrounds the nasobiliary tube and NFT guide wire. **d** The nasobiliary tube and NFT guide wire are fixed together by looping the line. **e** The guide wire retaining the line surrounding the nasobiliary tube is removed to lose the connection with the NFT.

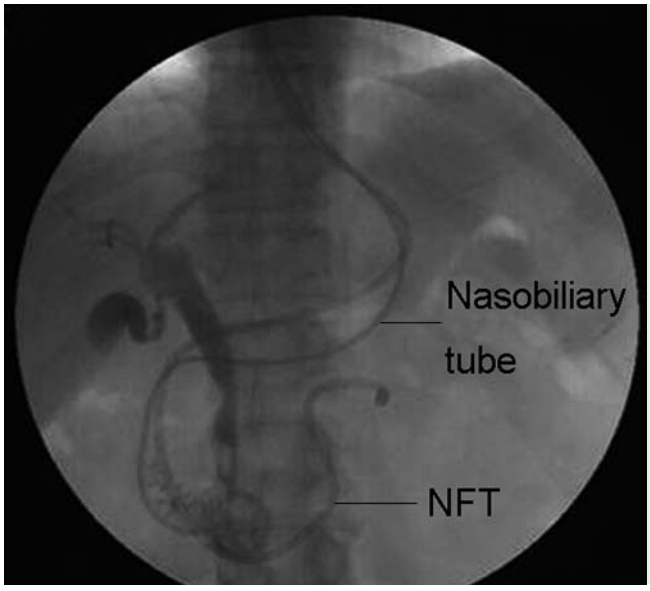

Fig. 2 Visualization by radiograph of the location of the nasojejunal feeding tube (NFT) and nasobiliary tube.

Acknowledgement

We thank Medjaden Bioscience Limited for assisting in the preparation of this manuscript.

Endoscopy_UCTN_Code_TTT_1AO_2AK

Competing interests: None

Z.-W. Lv, X.-H. Wang, B. Qu, M.-N. Liu, H. Xing, W. Zhou, C.-Q. Lv, B. Du
Department of Gastroenterology,
The Second Affiliated Hospital of Harbin Medical University, Harbin, China

This document was downloaded for personal use only. Unauthorized distribution is strictly prohibited.

References

1 *Boulton-Jones JR, Lewis J, Jobling JC, Teahon K.* Experience of post-pyloric feeding in seriously ill patients in clinical practice. Clin Nutr 2004; 23: 35 – 41

2 *Niv E, Fireman Z, Vaisman N.* Post-pyloric feeding. World J Gastroenterol 2009; 15: 1281 – 1288

3 *Ji F, Zhao JL, Jin X et al.* Endoscopic nasojejunal feeding tube placement in patients with severe hepatopancreatobiliary diseases: a retrospective study of 184 patients. Hepatobiliary Pancreat Dis Int 2010; 9: 54 – 59

4 *Wiggins TF, DeLegge MH.* Evaluation of a new technique for endoscopic nasojejunal feeding-tube placement. Gastrointest Endosc 2006; 63: 590 – 595

5 *Byrne KR, Fang JC.* Endoscopic placement of enteral feeding catheters. Curr Opin Gastroenterol 2006; 22: 546 – 550

Bibliography

DOI 10.1055/s-0030-1257052
Endoscopy 2012; 44: E131 – E132

© Georg Thieme Verlag KG Stuttgart · New York ·

ISSN 0013-726X

Corresponding author

Z.-W. Lv, MD
Department of Gastroenterology
The Second Affiliated Hospital of Harbin Medical University
194 Xue Fu Road
Harbin
Heilongjiang Province 150080
China
Fax: +86-451-86605404
drzwl@yahoo.com.cn

This document was downloaded for personal use only. Unauthorized distribution is strictly prohibited.