Diagnostic Accuracy of CEUS in the Differential Diagnosis of Small (≤ 20 mm) and Subcentimetric (≤ 10 mm) Focal Liver Lesions in Comparison with Histology

Results of the DEGUM Multicenter Trial

Diagnostische Treffsicherheit des kontrastmittelverstärkten Ultraschalls in der Differentialdiagnose kleiner (≤ 20 mm) und kleinster (≤ 10 mm) solider Leberraumforderungen im Vergleich zur Histologie

Ergebnisse der DEGUM-Multizenterstudie

Authors D. Strobel[1], T. Bernatik[1], W. Blank[2], A. Schuler[3], C. Greis[4], C. F. Dietrich[5], K. Seitz[6]

Affiliations Affiliation addresses are listed at the end of the article.

Key words
- abdomen
- tumor
- ultrasound
- tumor

Zusammenfassung

Hintergrund: Evaluierung der diagnostischen Treffsicherheit der Kontrastmittelsonografie in der Differenzialdiagnose kleiner Leberläsionen.

Material und Methoden: 1349 Patienten mit im B-Bild und Power Doppler unklarem Lebertumor wurden prospektiv mittels KM-Sono multizentrisch mit standardisiertem Protokoll (mechanischer Index < 0,4, Phase/Puls-Inversion-Technik, Sonovue-Bolus-Injektion) untersucht. Die Differenzialdiagnose im KM-Sono basierte auf tumortypischen Vaskularisationsmustern in der arteriellen, portalvenösen Phase und Spätphase (EFSUMB-Leitlinie). 335 Patienten mit fokalen Leberläsionen (FLLs) ≤ 20 mm wurden analysiert. Die Tumorklassifizierung nach KM-Sono wurde mit der Histologie (73,2 %) oder in einigen Fällen mit CT und/oder MRT verglichen.

Ergebnisse: Eine definitive Tumordiagnose war in 329 FLLs möglich. Die Enddiagnose der ≤ 20 mm FLLs mit histologischer Sicherung (n = 241) beinhaltete 87 benigne und 154 maligne Tumore. Die diagnostische Treffsicherheit des KM-Sono bei ≤ 20 mm histologisch gesicherten FLLs war 83,8 %. Die KM-Sono identifizierte 144 /154 maligne FLLs (Sensitivität 93,5 %) und 58 /87 benigne FLLs (Spezifität 66,7 %). 24 /241 FLLs blieben nach der KM-Sono unklar (9,9 %). Die KM-Sono klassifizierte 15 /241 FLLs (6,2 %) falsch (12 benigne und 3 maligne FLLs). Die positive Voraussagekraft der KM-Sono bei malignen FLLs war 92,3 %, die negative Voraussagekraft 95,1 %. Von 241 histologisch gesicherten FLLs waren 62 FLLs ≤ 10 mm (diagnostische Treffsicherheit KM-Sono 80,6 %) und 179 FLLs > 10 mm ≤ 20 mm (diagnostische Treffsicherheit KM-Sono 80,6 %).

Schlussfolgerung: Die KM-Sonografie hat eine hohe diagnostische Treffsicherheit in der Differenzierung kleiner und kleinster (≤ 1 cm) FLL im klinischen Alltag.

Abstract

Purpose: To evaluate the diagnostic accuracy of contrast-enhanced ultrasound (CEUS) in the differential diagnosis of small and subcentimetric liver tumors in clinical practice.

Materials and Methods: 1349 patients with a hepatic tumor lacking a definite diagnosis based on B-mode ultrasound and power Doppler ultrasound were examined at 14 hospitals by CEUS using a standardized protocol (pulse/phase inversion imaging, mechanical index < 0.4). Differential diagnosis was based on the vascularity pattern and contrast enhancement pattern during the arterial, portal, and late phase according to the EFSUMB guidelines. 335 patients with focal liver lesions (FLL) ≤ 20 mm were analyzed. The tumor status established after CEUS was compared to histology (73.2 %) or in some cases to CT or MRI.

Results: A definitive diagnosis based on the gold standard was possible in 329 FLLs, while 6 FLLs remained unclear even in the combined gold standard (histology and/or CT and/or MRI). The final diagnoses of ≤ 20 mm FLL with histological confirmation (n = 241) included 87 benign and 154 malignant entities. The overall diagnostic accuracy of CEUS in FLL ≤ 20 mm with histological confirmation was 83.8 %. CEUS correctly identified 144 /154 malignant FLLs (sensitivity 93.5 %) and 58 /87 benign FLLs (specificity 66.7 %). 24 / 241 FLLs remained unclear after CEUS (9.9 %). CEUS misclassified 15 /241 FLLs (6.2 %; 12 benign and 3 malignant FLLs). The positive predictive value of CEUS for a malignant FLL was 92.3 % and the negative predictive value was 95.1 %. Out of 241 small FLLs with histological confirmation, 62 FLLs were ≤ 10 mm (diagnostic accuracy of CEUS 80.6 %) and 179 FLLs were > 10 mm and ≤ 20 mm (diagnostic accuracy of CEUS 84.9 %).

Conclusion: CEUS has a high diagnostic accuracy for the differential diagnosis of small and subcentimetric FLLs in clinical practice.

received 4.10.2011
accepted 10.11.2011

Bibliography
DOI http://dx.doi.org/10.1055/s-0031-1271114
Published online: 2011
Ultraschall in Med 2011; 32: 593–597 © Georg Thieme Verlag KG Stuttgart · New York · ISSN 0172-4614

Correspondence
Prof. Dr. Deike Strobel
Internal medicine I,
University of Erlangen
Ulmenweg 18
91058 Erlangen
Germany
Tel.: ++49/91 31/8 53 50 00
Fax: ++49/91 31/8 53 52 52
deike.strobel@uk-erlangen.de

Introduction

Small and subcentimetric focal liver lesions (FLL) are increasingly found in patients due to the wide accessibility of modern high-resolution imaging procedures. Despite the improved sensitivity, small FLLs are more difficult to characterize due to their size. While the prevalence of benign FLLs in the general population is high, the prevalence of benigne FLLs in cancer patients is variable depending on the tumor stage. In patients with known extrahepatic malignancy, up to 51 % of small indeterminate FLLs in CT were benign on the basis of other imaging studies, biopsy results, or size stability for at least 6 months [1]. Schwartz et al. detected small indeterminate FLLs in 12 % of cancer patients in CT, but 82 % out of them were proven to be benign at follow-up [2].

Recently it was shown that ultrasound (US) and contrast-enhanced ultrasound (CEUS) are helpful for demonstrating or excluding metastases in patients with extrahepatic malignancy and indeterminate subcentimetric FLLs in MDCT [3]. According to the data of several national multicenter trials, CEUS is currently a well-established technique for characterizing non-cystic liver lesions [4 – 8]. However, the diagnostic performance of CEUS for the characterization of small and subcentimetric solid FLLs is not yet well addressed.

In this paper we report the results of a subanalysis of the prospective multicenter study initiated by the German Society for Ultrasound in Medicine (DEGUM) with respect to small (≤ 2 cm) and subcentimetric (≤ 1 cm) FLLs.

Materials and Methods

Study design

The study received approval from the institutional ethical review board. All patients gave written informed consent. Consecutive patients with a solid liver tumor visible at routine US were recruited for CEUS at the time of their US examination, after contraindications for US contrast has been ruled out. Patients with liver lesions diagnosed from characteristic B-mode echo morphology, such as patients with cysts or typical hemangiomas (in a non-steatotic liver), as well as lesions with clear signs of malignancy like vessel infiltration were not included in the study. Detailed information on the study design and patient characteristics were published earlier [4]. All patients were examined according to EFSUMB guidelines [9] according to a standardized protocol using low MI imaging with Sonovue bolus injection (BR1; Bracco, Milan, Italy) as described previously [4].

Liver tumor characterization

In the standardized protocol, liver tumor characterization was based on: a) real-time assessment of contrast enhancement of the FLL (hypo-enhanced, iso-enhanced, hyper-enhanced) in comparison with the surrounding liver parenchyma during the arterial phase (5 – 25 sec), portal-venous phase (25 – 60 sec), and late phase (> 120 sec after contrast injection), b) location of the initial contrast enhancement in the FLL (center, periphery), and c) specific vascularization pattern (wheel spoke pattern, irregular arteries, nodular enhancement, rim sign) in the arterial and portal-venous phases (fill-in pattern, washout pattern. (**Fig. 1, 2**) (3). Criteria used for a tumor-specific diagnosis of FLL have been previously presented in detail [5].

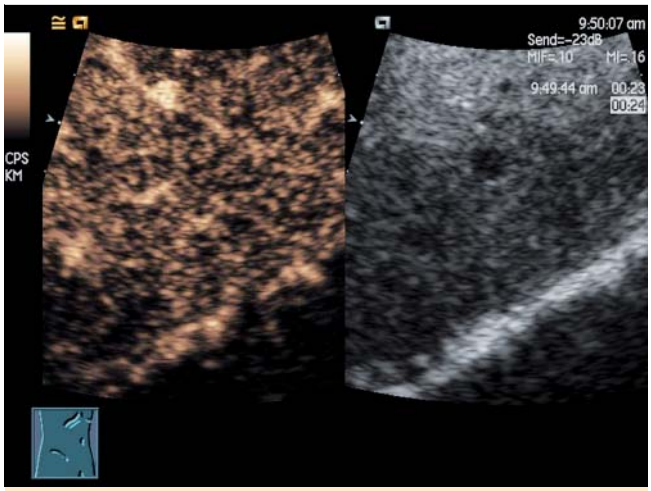

Fig. 1 Dual-mode image (B-mode and CEUS) of an 8 mm FLL (arterial phase). B-mode (right side) shows a hypoechoic 8 mm FLL. CEUS (left side) shows intratumoral vascularization 24 seconds after contrast application (isoenhancement in comparison to the surrounding liver parenchyma).

Abb. 1 B-Bild und Kontrastmittelverstärkter Ultraschall einer 8 mm großen Leberraumforderung (Arterielle Phase): Echoarme Raumforderung im B-Bild (rechte Bildhälfte). 24 Sekunden nach Kontrastmittelgabe intratumorale Vaskularisation, die Raumforderung stellt sich echogleich im Vergleich zum umgebenden Lebergewebe dar (linke Bildhälfte).

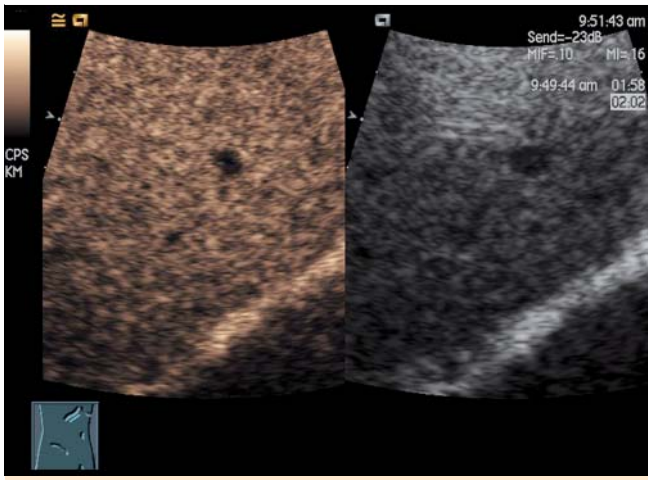

Fig. 2 Dual-mode image (B-mode and CEUS) of an 8 mm FLL (late phase). B-mode (right side of the image) shows a hypoechoic 8 mm FLL. CEUS (left side of the image) shows contrast washout diagnostic for metastasis 122 seconds after contrast application.

Abb. 2 B-Bild und Kontrastmittelverstärkter Ultraschall einer 8 mm großen Leberraumforderung (Spätphase): Echoarme Raumforderung im B-Bild (rechte Bildhälfte). 122 Sekunden nach Kontrastmittelgabe keine intratumorale Vaskularisation, Auswaschen des Kontrastmittels (linke Bildhälfte).

Tumor diagnosis reference (gold standard)

As a reference standard, the final diagnosis was based on all available imaging and clinical data, including histology and additional follow-up information. In 241/329 FLLs, including 179 FLLs > 10 mm and ≤ 20 mm and 62 FLLs ≤ 10 mm, histology served as the reference standard. In other cases (mainly typical FNHs and hemangiomas in CEUS), imaging modalities (CT and/or MRI) and

Table 1 Accuracy of CEUS in small (≤ 20 mm) and subcentimetric (≤ 10 mm) FLL with histologically confirmed diagnosis (n = 241).

CEUS	Sensitivity	Specificity	diagnostic accuracy	PPV	NPV
all FLL ≤ 20 mm (n = 329)	93.3 %	75.9 %	84.5 %	91.6 %	94.7 %
FLL with histological confirmation					
≤ 20 mm (n = 241)	93.5 %	66.7 %	83.8 %	92.3 %	95.1 %
> 10 mm ≤ 20 mm (n = 179)	94.6 %	68.7 %	84.9 %	92.2 %	97.9 %
≤ 10 mm (n = 62)	90.5 %	60.0 %	80.6 %	92.7 %	85.7 %

Table 2 Lesion type of small FLL (≤ 20 mm) with histologically confirmed diagnoses (n = 241).

FLL type	241
malignant FLL	154
metastases	116
hepatocellular carcinoma	26
other malignant FLL	12
benign FLL	87
hemangioma	20
FNH	21
regenerative nodule	10
focal fatty changes	9
other benign FLL	27

follow-up were judged as the reference standard. Detailed information on standardized CT and MR protocols used in this trial has been previously described [10, 11].

Statistics

The accuracy of CEUS for FLL characterization was assessed in terms of tumor dignity. Tumor status was assessed as benign, indeterminate or malignant. Diagnostic accuracy was calculated as the sum of true negatives and true positives divided by the total number of patients with each tumor entity based on the final reference diagnosis (histology).

The sensitivity was calculated as the percentage of true positive malignancies divided by the number of malignant FLLs based on the final diagnosis. The specificity was calculated as the number of true negative malignancies (i. e., classification as benign) divided by the number of benign FLLs based on the final reference diagnosis. Indeterminate classifications were rated as incorrect classifications in both calculations. The positive predictive value was calculated as the number of true positive malignancies divided by all positive classifications in CEUS. The negative predictive value was calculated as the number of true negatives (i. e. classification as benign) divided by all negative classifications in CEUS.

Data were analyzed using online data forms, which were part of the study protocol and were filled in by each examiner. The preparation of the online data forms, data quality control, calculation and statistical analysis were performed by an independent statistics institute, the Medidata Group, Konstanz, Germany. The work of Medidata Group was financially supported by Bracco Research Pharma, Konstanz, Germany. The authors had exclusive control of data and information presented in the manuscript. There was no other financial support.

Results

Out of the total of 1349 cases, 335 FLLs were ≤ 20 mm (24.8 %), a definitive diagnosis based on the gold standard was possible in 329 FLLs, and 6 FLLs remained unclear even in the combined gold standard (histology; if histology not available typical findings in CT and/or MRI). The final diagnoses of ≤ 20 mm FLLs included 166 benign and 163 malignant FLLs. In 185 patients (56.2 %), the FLL was an incidental finding. In 133 patients (40.4 %), a history of an extrahepatic malignancy was known, including 72 patients with liver metastasis (54.1 %).

Histological confirmation was assessed in 241 FLLs ≤ 20 mm (73.6 %). The overall diagnostic accuracy of CEUS in histologically confirmed FLLs ≤ 20 mm was 83.8 % (**Table 1**). CEUS correctly identified 144/154 malignant FLLs (sensitivity 93.5 %) and 58/87 benign FLLs (specificity 66.7 %). 24 /241 FLLs remained unclear after CEUS (9.9 %). CEUS misclassified 15/241 FLLs (6.2 %), including 12 benign FLLs and 3 malignant FLLs. The positive predictive value of CEUS in the classification of malignant FLLs was 92.3 % and the negative predictive value was 95.1 %.

Out of 241 small FLLs with histological confirmation, 179 FLLs were > 10 mm and ≤ 20 mm. The overall diagnostic accuracy of CEUS in FLLs > 10 mm and ≤ 20 mm with histological confirmation (n = 179) was 84.9 %. CEUS correctly identified 106 /112 malignant FLLs (94.6 %) and 46 /67 benign FLLs (68.7 %). 17 /179 FLLs remained unclear after CEUS (9.5 %). CEUS misclassified 10 /179 FLLs (5.6 %), including 9 benign FLLs and 1 malignant FLL. Including the misclassified FLLs and calculating the unclear FLLs as incorrect diagnoses, the sensitivity of CEUS for the classification of malignant FLLs > 10 mm and ≤ 20 mm was 94.6 % and the specificity was 68.7 %. The positive predictive value of CEUS in the classification of malignant FLLs > 10 mm and ≤ 20 mm was 92.2 % and the negative predictive value was 97.9 %.

Of 241 small FLLs with histological confirmation, 62 FLLs were ≤ 10 mm. The overall diagnostic accuracy of CEUS in FLLs ≤ 10 mm (n = 62) was 80.6 %. CEUS correctly identified 38 /42 malignant FLLs (sensitivity 90.5 %) and 12 /20 benign FLLs (specificity 60.0 %). After CEUS 7 /62 FLLs remained unclear (11.3 %). CEUS misclassified 5 /62 FLLs (8.1 %), including 3 benign FLLs and 2 malignant FLLs. The positive predictive value of CEUS in the classification of malignant FLLs ≤ 10 mm was 92.7 % and the negative predictive value was 85.7 %.

Tumor-specific diagnosis

Detailed information on specific tumor diagnoses is given in **Table 2**. Tumor-specific diagnoses based on histology were given in 187 /241 small focal FLLs, including 116 liver metastases, 26 HCCs, 21 FNHs, 20 hemangiomas, 10 regenerative nodules, 9 focal fatty changes and other rare entities. Due to the small numbers of tumor-specific diagnoses in the subgroups ≤ 10 mm; > 10 mm and ≤ 20 mm), only the tumor diagnostic accuracy for liver metastases was calculated: 99 out of 116 histologically confirmed metastases ≤ 20 mm were correctly diagnosed by CEUS, including 27 metastases ≤ 10 mm and 72 metastases > 10 mm and ≤ 20 mm.

Table 3 Diagnostic accuracy of CEUS, CT and MRI in histologically confirmed diagnoses.

patient	FLL (mm)	histology	CEUS	CT
1	4	scar	indeterminate	metastasis
2	8	metastasis	metastasis	metastasis
3	9	benign	metastasis	indeterminate
4	10	metastasis	metastasis	indeterminate
5	10	metastasis	metastasis	metastasis
6	10	metastasis	metastasis	indeterminate
7	11	regenerative nodule	regenerative nodule	HCC
8	12	metastasis	metastasis	metastasis
9	14	FNH	FNH	focal fat
10	14	FNH	benign	adenoma
11	14	FNH	benign	FNH
12	14	inflammatory FLL	indeterminate	metastasis
13	14	focal non fat	hemangioma	HCC
14	15	metastasis	metastasis	metastasis
15	15	metastasis	metastasis	metastasis
16	15	benign	metastasis	indeterminate
17	16	FNH	benign	hemangioma
18	17	metastasis	HCC	indeterminate
19	18	benign	hemangioma	hemangioma
20	18	HCC	HCC	HCC
21	18	focal fat	focal fat	focal fat
22	18	FNH	metastasis	malignant
23	19	scar	indeterminate	cyst
24	19	benign	FNH	indeterminate
25	20	FNH	FNH	indeterminate
26	20	FNH	indeterminate	FNH
27	20	metastasis	metastasis	metastasis
28	20	focal non fat	indeterminate	cyst
patient	**FLL (mm)**	**histology**	**CEUS**	**MRI**
1	1	FNH	FNH	FNH
2	4	angiomyolipoma	indeterminate	HCC
3	5	metastasis	indeterminate	cyst
4	8	metastasis	metastasis	metastasis
5	10	hemangioma	hemangioma	hemangioma
6	10	metastasis	hemangioma	metastasis
7	12	hemangioma	hemangioma	hemangioma
8	14	focal non fat	hemangioma	indeterminate
9	15	metastasis	hemangioma	metastasis
10	18	hemangioma	indeterminate	hemangioma
11	20	metastasis	metastasis	metastasis
12	20	metastasis	metastasis	metastasis
13	20	HCC	HCC	HCC
14	20	hemangioma	metastasis	metastasis
15	20	hemangioma	metastasis	hemangioma

CEUS versus CT and MRI

Due to the design of the multicenter trial in which histology was the major gold standard (in the majority of FLLs), it is not possible to statistically compare the diagnostic accuracy of CEUS to CT and MRI in small FLLs. FLLs ≤ 20 mm were examined by CT (n = 28) and MRI (n = 15). Comparative data of these FLLs are given in detail in ▶ **Table 3**. Only one FLL (histologically focal non-fatty lesion) was examined by all three imaging modalities. The CEUS diagnosis was hemangioma, the CT diagnosis was HCC, and the MRI diagnosis was indeterminate.

Discussion

Based on the ongoing technical progress of US, CEUS, CT and MRI [12], there is an overall increase in the detection of small and subcentimetric FLLs within the liver parenchyma. However, especially subcentimetric FLLs are frequently difficult to characterize in CT and MRI. Based on the high spatial resolution in real-time imaging, ultrasound is ideal for characterizing FLLs which remain unclear in CT and MRI. B-scan ultrasound can identify small cysts at the site of indeterminate CT or MRI findings. For the characterization of non-cystic liver FLLs which remain unclear in conventional B-mode ultrasound, CEUS is currently a well-established technique [4–7]. With respect to small FLLs, the value of CEUS is not yet well defined. The prevalence of small FLLs in cancer patients and in the general population is different and the risk of malignant nature in the latter is significantly lower. Particularly with respect to cancer patients, prognosis and treatment are strictly dependent on a precise tumor diagnosis. A high percentage (92 %) of benign subcentimetric FLLs has been found in breast cancer patients [13, 14]. The reported incidence of at least one hepatic lesion too small to characterize was 29.4 % in women without definite liver metastasis on CT [13] and MRI offered marginal additional diagnostic accuracy [14]. The limitation of multidetector CT to characterize small < 1.5 cm hypoattenuating FLLs has also been addressed in a recent

study in patients with rectal cancer using follow-up CT data [15]. In the differentiation of small benign and metastatic lesions (≤2 cm) in colorectal cancer patients, MRI is superior to helical CT [16]. Due to the design of our trial choosing histology as the gold standard (in the majority of FLLs), it is not possible to compare the diagnostic accuracy of CEUS to CT and MRI. Thus, it remains speculative that the diagnostic performance of CEUS for the differential diagnosis of small and subcentimetric FLLs is superior to CT and MRI based on the fact that US offers the superior spatial resolution and real-time assessment of tumor vascularization. CEUS offers excellent visualization of the vascularity pattern and the washout phenomenon of malignant tumors as seen in **Fig. 1, 2** is useful to differentiate them from benign FLLs. However, CEUS has the same limitations as all US techniques in patients with extreme meteorism and obesity, especially in the visualization of small and deeply localized lesions. Therefore, CEUS is not suitable for all patients. Nevertheless, in patients with sufficient scanning conditions, CEUS can serve as a problem-solving tool for indeterminate FLLs on prior CT or MRI scans. In a recent study by Laghi et al., CEUS was shown to be helpful in demonstrating or excluding metastases in cancer patients with MDCT evidence of subcentimetric, indeterminate focal liver lesions [3]. Among 206 indeterminate, subcentimetric FLLs ≤10 mm) in MDCT, B-mode US proved the cystic nature of 138 lesions and CEUS correctly classified 65 non-cystic FLLs.

In the German multicenter study (DEGUM study) including only liver FLLs that were unclear based on sonomorphological criteria in B-mode and color or power Doppler US, CEUS showed a high overall diagnostic accuracy of more than 90%. We now demonstrate the high diagnostic accuracy of CEUS in small FLLs (≤10 mm FLLs 80.6%; >10 ≤20 mm FLLs 84.9%). Our study confirms that CEUS can characterize the majority of small FLLs which remain unclear in conventional ultrasound.

Abbreviations

FLL	focal liver lesion
CT	computed tomography
MRI	magnetic resonance imaging
MDCT	multi-detector computed tomography
FNH	focal nodular hyperplasia
DEGUM	German Society for Ultrasound in Medicine
EFSUMB	European Federation of Societies for Ultrasound in Medicine and Biology

Parts of this manuscript were presented at the EUROSON ultrasound summer school meeting 2010, Bad Saulgau, Germany.
Statistical analysis was provided by an independent statistics institute, the Medidata Group, Konstanz, Germany. The work of Medidata Group was financially supported by Bracco Research Pharma, Konstanz, Germany. The authors had exclusive control of data and information presented in the manuscript. There was no other financial support.

Affiliations

[1] Dept. of Medicine 1, University of Erlangen
[2] Dept. of Internal Medicine, Krankenhaus Reutlingen
[3] Dept. of Internal Medicine, Helfenstein-Klinik Geislingen
[4] Research Unit, Bracco Imaging, Konstanz
[5] Dept. of Internal Medicine, Caritas-Krankenhaus Bad Mergentheim
[6] Dept. Internal Medicine, Kreiskrankenhaus Sigmaringen

Acknowledgment

The active support of the participating centers for patient recruitment is greatly acknowledged: Department of Medicine I (A. v. Herbay), University of Tuebingen Department of Internal Medicine, Klinikum Villingen-Schwenningen, (G. Kunze); Department of Internal Medicine, KKH Eckernfoerde (D. Becker); Department of Gastroenterology, SRH Waldklinikum Gera (U. Will); Department of Medicine I, University of Ulm (W. Kratzer); Department of Gastroenterology, Westpfalz Klinikum Kaiserslautern (F. W. Albert).

References

1 *Jones EC, Chezmar JL, Nelson RC et al.* The frequency and significance of small hepatic lesions (<15 mm) detected by CT. AJR 1992; 158: 535–539
2 *Schwartz LH, Gandras EJ, Colangelo SM et al.* Prevalence and importance of small hepatic lesions found at CT in patients with cancer. Radiology 1999; 210: 71–74
3 *Laghi F, Catalano O, Maresca M et al.* Indeterminate, subcentimetric focal liver lesions in cancer patients: additional role of contrast-enhanced ultrasound. Ultraschall in Med 2010; 31: 283–288
4 *Strobel D, Seitz K, Blank W et al.* Contrast-enhanced ultrasound for the characterization of focal liver lesions – diagnostic accuracy in clinical practice (DEGUM multicenter trial). Ultraschall in Med 2008; 29: 499–505
5 *Strobel D, Seitz K, Blank W et al.* Tumor-specific vascularization pattern of liver metastasis, hepatocellular carcinoma, hemangioma and FNH in the differential diagnosis of 1,349 liver lesions in contrast-enhanced ultrasound (CEUS). Ultraschall in Med 2009; 30: 376–382
6 *Tranquart F, Correas JM, Ladam MarcusV et al.* Real-time contrast-enhanced ultrasound in the evaluation of focal liver lesions: diagnostic efficacy and economical issues from a French multicentric study. J Radiol 2009; 90: 109–122
7 *Schuler A, Reuss J, Delorme S et al.* Costs of clinical ultrasound examinations – an economical cost calculation and analysis. Ultraschall in Med 2010; 31: 379–386
8 *Romanini L, Passamonti M, Aiani L et al.* Economic assessment of contrast-enhanced ultrasonography for evaluation of focal liver lesions: a multicentre Italian experience. Eur Radiol 2007; 17: F99–F106
9 *Claudon M, Cosgrove D, Albrecht T et al.* Guidelines and good clinical practice recommendations for contrast enhanced ultrasound (CEUS) – update 2008. Ultraschall in Med 2008; 29: 28–44
10 *Seitz K, Strobel D, Bernatik T et al.* Contrast-Enhanced Ultrasound (CEUS) for the characterization of focal liver lesions – prospective comparison in clinical practice: CEUS vs. CT (DEGUM multicenter trial). Ultraschall in Med 2009; 30: 383–389
11 *Seitz K, Bernatik T, Strobel D et al.* Contrast-enhanced ultrasound (CEUS) for the characterization of focal liver lesions in clinical practice (DEGUM Multicenter Trial): CEUS vs. MRI – a prospective comparison in 269 patients.. Ultraschall in Med 2010; 31: 492–499
12 *Mostbeck G.* Imaging of focal liver lesions: the 90%-rule. Ultraschall in Med 2010; 31: 545–547
13 *Khalil HI, Patterson SA, Panicek DM.* Hepatic lesions deemed too small to characterize at CT: prevalence and importance in women with breast cancer. Radiology 2005; 235: 872–878
14 *Patterson SA, Khalil HI, Panicek DM.* MRI evaluation of small hepatic lesions in women with breast cancer. AJR 2006; 187: 307–312
15 *Tan CH, Bhosale PR, Das P et al.* Multidetector computed tomography follow-up of hypoattenuating small liver lesions in patients with rectal cancer. Am J Clin Oncol 2011; 34: 411–416
16 *Kim KW, Kim AY, Kim TK et al.* Small ((2 cm) hepatic lesions in colorectal cancer patients: detection and characterization on mangafodipir trisodium-enhanced MRI. AJR Am J Roentgenol 2004; 182: 1233–1240