

The Effect of High Dose Methylprednisolone on Experimental Ovarian Torsion/Reperfusion Injury in Rats

Die Wirkung von hochdosiertem Methylprednisolon auf experimentelle Ovarialtorsion/Reperfusion in Ratten

Authors

M. A. Osmanağaoğlu¹, M. Kesim², E. Yuluğ³, A. Menteşe⁴, C. S. Karahan⁴

Affiliations

¹ Department of Obstetrics and Gynecology, Karadeniz Technical University, Trabzon, Turkey

² Department of Pharmacology, Karadeniz Technical University, Trabzon, Turkey

³ Department of Histology and Embryology, Karadeniz Technical University, Trabzon, Turkey

⁴ Department of Biochemistry, Karadeniz Technical University, Trabzon, Turkey

Schlüsselwörter

- hoch Dosis Methylprednisolon
- Ratten
- Ovarial Ischämie-Reperfusion
- oxidativ Stress
- Histopathologie

Key words

- high dose methylprednisolone
- rats
- ovarian ischemia-reperfusion
- oxidative stress
- histopathology

Abstract

Purpose: Aim of the study was to evaluate the effects of high dose methylprednisolone on experimental ovarian torsion-detorsion injury in rats.

Materials and Methods: Twenty-two Sprague-Dawley rats were randomly divided into three groups. Group 1 (ischemia group, 8 rats) were subjected to left adnexal torsion for 2 h but received no treatment. Group 2 (methylprednisolone group, 8 rats) were subjected to left adnexal torsion for 2 h and received methylprednisolone (30 mg/kg, administered intraperitoneally) at the end of a 2-hour ischemic period followed by 24-hour reperfusion. Group 3 (control group, 6 rats) underwent a sham operation with no adnexal torsion and no treatment.

Results: Serum malondialdehyde (MDA), ischemia-modified albumin (IMA), total oxidant status (TOS) and tissue MDA levels were increased in Group 1 rats; total antioxidant status (TAS) levels and oxidative stress index (OSI) were significantly decreased compared with rats in Groups 2 and 3 ($p < 0.05$). MDA, IMA, TOS and tissue MDA levels were lower and TAS levels and OSI were higher in Group 3 compared to Group 2. Ovarian damage scores in Group 1 were significantly higher compared with Groups 2 and 3 ($p < 0.05$).

Conclusion: This study demonstrated that high dose methylprednisolone reduces ovarian ischemia/reperfusion injury.

Zusammenfassung

Fragestellung: Ziel der Studie war es, die Effekte von hohen Dosen Methylprednisolon auf experimentelle ovariale Torsion-Detorsions-Verletzungen bei Ratten zu bewerten.

Material und Methoden: 22 Sprague-Dawley-Ratten wurden in 3 Gruppen randomisiert. In Gruppe 1 (Ischämiegruppe, 8 Ratten) wurde der linke Adnex 2 h einer Torsion unterzogen, es erfolgte keine Behandlung. In Gruppe 2 (Methylprednisolon-Gruppe, 8 Ratten) wurde nach 2-stündiger Torsion des linken Adnexes und der damit verbundenen Ischämie Methylprednisolon (30 mg/kg, intraperitoneal) verabreicht, es folgte eine 24-Stunden-Reperfusion. Gruppe 3 (Sham-Operationsgruppe als Kontrollgruppe, 6 Ratten) blieb ohne Torsion des Adnexes oder Behandlung.

Ergebnisse: Serum-Malondialdehyd (MDA), Ischämie-modifiziertes Albumin (IMA), Gesamt-oxydationsmittelstatus (TOS) und MDA-Level in Gewebe waren in den Gruppe-1-Ratten erhöht; das Niveau des Gesamtantioxydationsmittelstatus (TAS) und der Index des oxidativen Stresses (OSI) waren im Vergleich zu Gruppe-2- und Gruppe-3-Ratten signifikant verringert ($p < 0,05$). In Gruppe 3 waren die MDA-, IMA-, TOS- und Gewebe-MDA-Level niedriger und die TAS- und OSI-Level höher als in Gruppe 2. Der Grad des resultierenden ovariären Schadens war in Gruppe 1 signifikant höher als in Gruppe 2 und 3 ($p < 0,05$).

Schlussfolgerung: Diese Studie demonstrierte, dass hoch dosiertes Methylprednisolon ovariale Ischämie-/Reperfusions-Verletzungen reduziert.

received 17.9.2011
revised 13.11.2011
accepted 13.11.2011

Bibliography

DOI <http://dx.doi.org/10.1055/s-0031-1280433>
Geburtsh Frauenheilk 2012; 72: 70–74 © Georg Thieme Verlag KG Stuttgart · New York · ISSN 0016-5751

Correspondence

Dr. Mehmet A. Osmanağaoğlu
Karadeniz Technical University
Department of Obstetrics and Gynecology
61080 Trabzon
Turkey
drmaosmanaga@gmail.com

Introduction

Ovarian torsion is the twisting of the ovary and/or tube on its ligamentous support. It is a rare but serious event with an incidence of 2.7% and requires emergency gynecological surgery [1]. If ovarian torsion is diagnosed and treated early with surgical detorsion of the involved segments, the outlook for preserving fertility is good [2].

Ischemic damage caused by decreased adnexal circulation due to torsion is one possible cause of adnexal injury, with lipid peroxide levels in tissue and IMA levels in plasma increasing as a result of hypoxia resulting from the decrease in blood flow [3, 4]. However, it has been shown that the detorsion process can lead to excessive production of reactive oxygen species (ROS) such as superoxide anions, hydrogen peroxide, and hydroxyl radicals [5, 6].

The precise mechanisms of corticosteroid effects have not yet been elucidated. Inhibition of inflammatory cytokines, modulation of inflammatory/immune cells, the improvement of blood flow and the prevention of intracellular and extracellular Ca^{2+} current, cell degeneration have all been proposed [7]. Inhibition of lipid peroxidation has been hypothesized to be the most protective effect of glucocorticoids, and methylprednisolone appears to be particularly efficacious compared with other glucocorticoids [8]. The protective effect of methylprednisolone may be due to its anti-inflammatory properties or because of a direct impact on vascular permeability and edema [9, 10].

The aim of this study was to investigate the effect of high dose methylprednisolone with its antioxidant and membrane-stabilizing characteristics on recovery from ischemia-reperfusion injury in an experimental rat adnexal torsion model.

Materials and Methods

Rat model

A total of 22 female adult Sprague-Dawley rats weighing between 145–280 g were used in this study. The animals were obtained from the Karadeniz Technical University's Experimental Animal Laboratory. Animals were housed at the Animal Research Center of Karadeniz Technical University and were kept under constant laboratory conditions at room temperatures of 20°C to 22°C in a 12-hour light-dark cycle, and were allowed free access to food and water. The experimental protocol was approved by the Animal Care and Ethics Committee of the Faculty of Medicine, Karadeniz Technical University (approval number: 2011/16). The surgical procedures described below were performed in accordance with the guidelines of the National Institutes of Health. The study team was blinded to the randomized groups.

Rats were allocated into one of 3 groups as follows:

- ▶ Group 1 (torsion group, 8 rats); rats were subjected to left adnexal torsion for 2 h but received no further treatment;
- ▶ Group 2 (methylprednisolone group, 8 rats); rats were subjected to left adnexal torsion for 2 h. At the end of 2-hour ischemia, methylprednisolone (30 mg/kg, intraperitoneally) was administered and 24-hour reperfusion was continued;
- ▶ Group 3 (sham-operated group serving as controls, 6 rats); rats had no adnexal torsion and received no treatment.

Anesthesia and surgical procedure

All rats were weighed and anesthetized with a mixture of 50 mg/kg body weight ketamine hydrochloride (Ketalar, Eczacıbaşı, İstanbul, Turkey) and 10 mg/kg body weight xylazine (Rompun,

Bayer, Leverkusen, Germany) injected intraperitoneally. They were allowed to breath spontaneously (not intubated) during the study. Abdomens were shaved and cleaned with a 10% solution of polyvinyl pyrrolidone/iodine. A longitudinal incision was performed in the midline area of the lower abdomen. A small peritoneal incision was made, and the uterine horns and adnexa were located. In the ischemia groups (Groups 1 and 2), left unilateral ovarian ischemia was induced by applying two vascular clips using a silicone catheter to increase the pressure, one below the left ovary and the other in the uterus. In the torsion group, the clips were removed after a 2-hour period of ischemia, and the left ovary was surgically removed for histological examination. In the methylprednisolone group, following left unilateral ovarian ischemia with two vascular clips for a period of 2 hours, 30 mg/kg methylprednisolone was administered intraperitoneally, the incision was closed in layers and 24-hour reperfusion was continued. Until the end of the experimental protocol (24 hours), the animals were housed in a temperature-controlled room with food and water provided ad libitum. At the end of 24 hours, rats were anesthetized by intraperitoneal administration of 50 mg/kg ketamine hydrochloride and 10 mg/kg xylazine hydrochloride, and relaparotomy was done in all groups of rats. A 1.5–2 ml blood sample was taken from the abdominal aorta of each rat for biochemical examination. After taking the blood samples, the left ovaries were surgically removed. Ovaries were bisected, with one half used to determine MDH levels in ovarian tissue and the other half fixed in a 10% formaldehyde solution for histological examination. All rats were sacrificed by drawing arterial blood from the aorta of the abdomen.

Histological examination

Ovarian tissues were fixed in 10% neutral buffered formalin solution for 48 h, dehydrated, cleared in xylene, and embedded in paraffin. Sections (5 µm) were cut and stained with hematoxylin and eosin (H & E) and observed by light microscopy to investigate histological alterations. All sections were examined with a photomicroscope (BX-51; Olympus, Tokyo, Japan) and photographed. At least five microscopic areas of each ovary in each group were randomly selected, and examined to determine the semiquantitative score of the specimen. The criteria for ovarian injury were: follicular cell degeneration, vascular congestion, hemorrhage and infiltration by inflammatory cells. Each specimen was scored for each criterion, using a scale ranging from 0 to 3 (0: none; 1: mild; 2: moderate; 3: severe) [11]. The ovarian sections were all analyzed by the same histologist blinded to the groups (E.Y).

Specimens

Blood samples were withdrawn from the ascending aorta of rats, placed into plain tubes containing separation gels and allowed to clot for 30 min. Serum samples were prepared by 15 min centrifugation at 3000 rpm. Tissue and blood samples were kept at –80°C until biochemical analysis.

Serum malondialdehyde (MDA) activity assay

Lipid peroxidation in rat serum samples was determined based on malondialdehyde concentrations, using the method described by Yagi [12]. Briefly, 2.4 mL of N/12 H_2SO_4 and 0.3 mL of 10% phosphotungstic acid were added to 0.3 mL of serum. After standing at room temperature for 5 min, the mixture was centrifuged at 1600 g for 10 min. The supernatant was discarded and the sediment was suspended in 4 mL of distilled water. Subsequently, 1 mL of 0.67% thiobarbituric acid was added, and the

mixture was heated in boiling water for 60 min. The mixture was centrifuged at 1600 g for 10 min. Absorbance of the organic layer was read at 532 nm. Tetramethoxypropane was used as a standard and MDA levels were calculated as nmol/mL.

Serum ischemia-modified albumin (IMA)

Reduced cobalt to albumin binding capacity (IMA level) was analyzed using the rapid and colorimetric method of Bar-Or et al. [13]. Two hundred μL of rat serum were placed into glass tubes and 50 μL of 0.1% cobalt chloride (Sigma, $\text{CoCl}_2 \cdot 6\text{H}_2\text{O}$) in H_2O were added. After gentle shaking, the solution was left for 10 minutes to ensure sufficient cobalt albumin binding. Fifty microliters of dithiothreitol (DTT) (Sigma, 1.5 mg/mL H_2O) were added as a colorizing agent, and the reaction was quenched 2 min later by adding 1.0 mL of 0.9% NaCl. A colorimetric control was prepared for preoperative and postoperative serum samples. In the colorimetric control samples, 50 μL of distilled water was substituted for 50 μL of 1.5 mg/mL DTT. Specimen absorbance was analyzed at 470 nm by a spectrophotometer (Shimadzu UV1601, Australia). The color of the DTT-containing specimens was compared with that of the colorimetric control tubes. The results were reported as absorbance units (ABSUs).

Measurement of total antioxidative capacity (TAC)

The total antioxidant status of the serum was determined using a novel-automated measurement method, as developed and described by Erel [14].

Measurement of total oxidant status (TOS)

TOS of serum was determined using a novel automated measurement method as previously described [15].

Oxidative stress index (OSI)

The percentage ratio of the total peroxide level to the TAC was used to calculate the oxidative stress index (OSI) [16].

Tissue MDA activity assay

Left ovarian tissues were weighed and homogenized in ice-cold 1.15% KCl (2 and 10% w/v, respectively). The homogenate was centrifuged at 2000 g for 10 min. MDA levels in tissue samples were determined using the method of Mihara and Uchiyama [17]. Tetramethoxypropane was used as a standard and tissue MDA levels were calculated as nmol/g wet tissue.

Statistical analysis

The Statistical Package for the Social Sciences program (SPSS version 13.0; SPSS Inc., Chicago, IL, USA) was used for statistical analysis. Comparisons between groups were performed by Kruskal-Wallis analysis of variance and Mann Whitney U tests. Results are expressed as mean \pm SD. A p value less than 0.05 was considered statistically significant.

Results

There was no statistical difference in mean weights between any of the groups examined (Table 1). Serum MDA, IMA, TOS and tissue MDA levels in Group 1 were significantly increased. TAS levels and OSI were significantly decreased compared with Groups 2 and 3 (Table 1). MDA, IMA, TOS and tissue MDA levels were lower and TAS levels and OSI were higher in Group 3 compared to Group 2 (Table 1). Ovarian damage scores in Group 1 were significantly higher compared with Groups 2 and 3. Semi-quantitative and the mean total histopathological scores for the left ovaries (scores of the four ovarian damage parameters) are shown in Table 2. Ovaries of the control group (Group 3) exhibited a normal microscopic structure (Fig. 1). Significant structural differences were observed in the torsion group (Group 1), where widespread severe hemorrhage and moderate vascular congestion were noted (Fig. 2). In the methylprednisolone group (Group 2), ovarian sections showed mild hemorrhage (\uparrow) and moderate vascular congestion (Fig. 3). Ovarian damage scores in Group 1 were significantly higher compared with Groups 2 and 3 (Table 2). The morphological changes noted in Group 1 were partially reversed in Group 2 by the administration of high dose methylprednisolone.

Discussion

Several factors have been associated with ischemia/reperfusion injury, including free radicals and neutrophils [18]. Free oxygen radicals, which are created as a result of the reperfusion injury, react with lipids and cause the formation of lipid peroxides. As was noted in the present study, increased levels of tissue MDA indicate the level of lipid peroxidation in tissue, which is considered a marker of tissue injury [19]. Peroxidation of lipids disrupts

Table 1 Characteristic of biochemical and tissue measurements in rats with left ovarian injury.

	Torsion group (n = 8)	High dose methylpred- nisolone group (n = 8)	Control group (n = 6)	p		
				p ^a	p ^b	p ^c
Weight (g)	223 \pm 43.00	198 \pm 26.31	199 \pm 31.84	> 0.05	> 0.05	> 0.05
Serum MDA (nmol/mL)	2.11 \pm 0.54	0.38 \pm 0.10	1.24 \pm 0.67	< 0.01	< 0.01	< 0.01
Serum IMA	1.05 \pm 0.08	0.69 \pm 0.11	0.85 \pm 0.06	< 0.01	< 0.01	< 0.05
TAS	0.56 \pm 0.10	1.47 \pm 0.39	0.92 \pm 0.07	< 0.01	< 0.01	< 0.05
TOS	50.55 \pm 13.72	23.48 \pm 4.28	32.30 \pm 6.66	< 0.01	< 0.05	< 0.05
OSI	9.27 \pm 2.87	1.78 \pm 0.89	3.52 \pm 0.86	< 0.01	< 0.01	< 0.01
Tissue MDA of left ovary (nmol/mL · g)	177.27 \pm 51.83	70.98 \pm 25.40	111.62 \pm 37.61	< 0.01	< 0.05	< 0.05

Values are mean \pm SD.

MDA: malondialdehyde, IMA: ischemia-modified albumin, TAS: total antioxidant status, TOS: total oxidant status, OSI: oxidative stress index

p^a: Comparison of torsion group with high dose methylprednisolone group.

p^b: Comparison of torsion group with control group.

p^c: Comparison of high dose methylprednisolone group with control group.

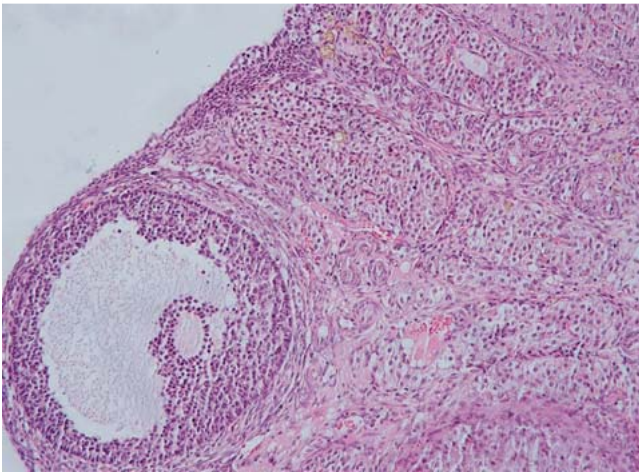


Fig. 1 In the control group, ovarian sections showed a normal ovarian structure. No pathological changes were noted in the ovarian sections (H & E $\times 200$).

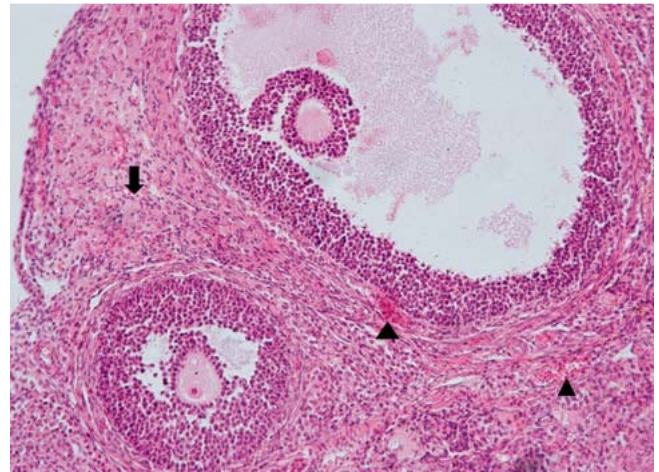


Fig. 3 In the high dose methylprednisolone group, ovarian sections showed mild hemorrhage (\downarrow) and moderate vascular congestion (\blacktriangle) (H & E $\times 200$).

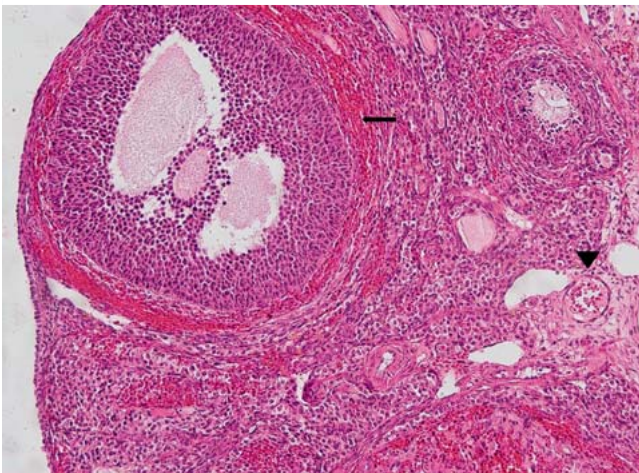


Fig. 2 In the torsion group, ovarian sections showed severe hemorrhage (\leftarrow), moderate vascular congestion (\blacktriangledown), follicular cell degeneration and inflammatory cell infiltration (H & E $\times 200$).

the membrane and forms toxic substances such as aldehydes [20]. The IMA-generating mechanism may be due to the reactive oxygen species produced during ischemia [3,4]. The anti-inflammatory effects of glucocorticoids are primarily resulted from glucocorticoid receptors by the reduction of inflammation-induced prostaglandin production through inhibition of the expression of phospholipase A₂ and cyclo-oxygenase-2 or from direct effects on vascular permeability and edema [10]. As was also in previous studies [7,8,19,20], the administration of high dose methylprednisolone significantly decreases levels of serum and tissue MDA, which in the present study indicated that methylprednisolone administration decreased the severity of lipid peroxidation and oxidative stress. In addition, in this study, high dose methylprednisolone was found to normalize serum TAS, TOS and IMA levels. We suggest that OSI was increased in the methylprednisolone group because of decreased TOS and increased TAS. Evaluation of histological parameters in the present study also showed that treatment with high dose methylprednisolone reduced the extent of ischemia/reperfusion tissue injury in rats. Our findings show that oxidative stress is an important element in ovarian torsion and high dose methylprednisolone may protect the ovary by reducing oxidative injury during ischemia/reperfusion. The protective effect of methylprednisolone may be attributable to its ability to upregulate the antioxidant capacity in rat ovaries.

Table 2 Semiquantitative scores for left ovarian damage of histological specimens.

	Torsion group (n = 8)	High dose methylpred- nisolone group (n = 8)	Control group (n = 6)	p		
				p ^a	p ^b	p ^c
Follicular cell degeneration	1.73 \pm 0.46	1.00 \pm 0.00	0.33 \pm 0.51	<0.05	<0.01	<0.05
Vascular congestion	2.63 \pm 0.51	1.25 \pm 0.46	0.33 \pm 0.51	<0.01	<0.01	<0.05
Hemorrhage	2.38 \pm 0.51	1.38 \pm 0.51	0.00 \pm 0.00	<0.01	<0.01	<0.01
Inflammatory cell infiltration	1.75 \pm 0.46	1.13 \pm 0.35	0.33 \pm 0.51	<0.05	<0.01	<0.05
Total	8.50 \pm 1.51	4.75 \pm 1.03	1.00 \pm 0.63	<0.01	<0.01	<0.01

Values are mean \pm SD.

p^a: Comparison of torsion group with high dose methylprednisolone group.

p^b: Comparison of torsion group with control group.

p^c: Comparison of high dose methylprednisolone group with control group.

In conclusion, high dose methylprednisolone treatment reduced the ischemia/reperfusion-induced oxidative injury and significantly increased the OSI. However, further studies are needed to determine the precise protective mechanism of high dose methylprednisolone on ischemia/reperfusion injury in ovarian tissue.

Acknowledgements

▼
We thank the Animal Research Center of Karadeniz Technical University for their technical assistance.

Conflict of Interest

▼
None.

References

- 1 Hibbard LT. Adnexal torsion. *Am J Obstet Gynecol* 1985; 152: 456–461
- 2 Chen M, Chen CD, Yang YS. Torsion of the previously normal uterine adnexa. Evaluation of the correlation between the pathological changes and the clinical characteristics. *Acta Obstet Gynecol Scand* 2001; 80: 58–61
- 3 Aran T, Guven S, Unsal MA et al. Serum ischemia-modified albumin as a novel marker of ovarian torsion: an experimental study. *Eur J Obstet Gynecol Reprod Biol* 2010; 150: 72–75
- 4 Çelik O, Turkoz Y, Hascalik S et al. The protective effect of caffeic acid phenethyl ester on ischemia-reperfusion injury in rat ovary. *Eur J Obstet Gynecol Reprod Biol* 2004; 117: 183–188
- 5 Akgur FM, Kılınç K, Aktug T. Reperfusion injury after detorsion of unilateral testicular torsion. *Urol Res* 1993; 21: 395–399
- 6 Li C, Jackson RM. Reactive species mechanisms of cellular hypoxia-reoxygenation injury. *Am J Physiol (Cell Physiol)* 2002; 282: 227–241
- 7 Kahraman S, Duz B, Kayali H et al. Effects of methylprednisolone and hyperbaric oxygen on oxidative status after experimental spinal cord injury: a comparative study in rats. *Neurochem Res* 2007; 32: 1547–1551
- 8 Braughler JM. Lipid peroxidation-induced inhibition of gamma-aminobutyric acid uptake in rat brain synaptosomes: protection by glucocorticoids. *J Neurochem* 1985; 44: 1282–1288
- 9 Hall ED. The neuroprotective pharmacology of methylprednisolone. *J Neurosurg* 1992; 76: 13–22
- 10 Goppelt-Strube M, Schaefer D, Habenicht AJR. Differential regulation of cyclo-oxygenase-2 and 5-lipoxygenase-activating protein (FLAP) expression by glucocorticoids in monocytic cells. *Br J Pharmacol* 1997; 122: 619–624
- 11 Guven S, Muci E, Unsal MA et al. The effects of carbon dioxide pneumoperitoneum on ovarian blood flow, oxidative stress markers, and morphology during laparoscopy: a rabbit model. *Fertil Steril* 2010; 93: 1327–1332
- 12 Yagi K. Lipid peroxides and related radicals in clinical medicine. In: Armstrong D, ed. *Free Radicals in Diagnostic Medicine*. New York: Plenum Press; 1994: 1–15
- 13 Bar-Or D, Lau E, Winkler JV. A novel assay for cobalt-albumin binding and its potential as a marker for myocardial ischemia – a preliminary report. *J Emerg Med* 2000; 19: 311–315
- 14 Erel O. A novel automated method to measure total antioxidant response against potent free radical reactions. *Clin Biochem* 2004; 37: 112–119
- 15 Erel O. A new automated colorimetric method for measuring total oxidant status. *Clin Biochem* 2005; 38: 1103–1111
- 16 Harma M, Harma M, Erel O. Increased oxidative stress in patients with hydatidiform mole. *Swiss Med Wkly* 2003; 133: 563–566
- 17 Uchiyama M, Mihara M. Determination of malonaldehyde precursor in tissues by thiobarbituric acid test. *Analytical Biochemistry* 1978; 86: 271–288
- 18 Yoshioka T, Kawada K, Shimada T et al. Lipid peroxidation in maternal and cord blood and protective mechanism against active-oxygen toxicity in the blood. *Am J Obstet Gynecol* 1979; 135: 372–376
- 19 Usul H, Arslan E, Cansever T et al. Effects of clotrimazole on experimental spinal cord ischemia/reperfusion injury in rats. *Spine* 2008; 33: 2863–2867
- 20 Vural H, Aksoy N, Özbilge H. Alteration of oxidative-antioxidative status in human cutaneous leishmaniasis. *Cell Biochem Funct* 2004; 22: 153–156