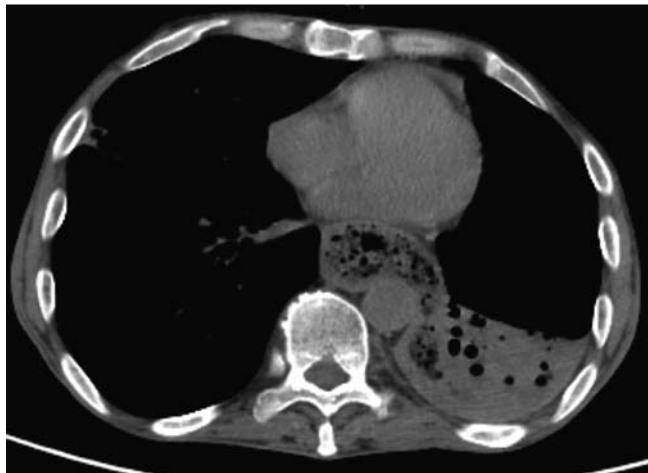
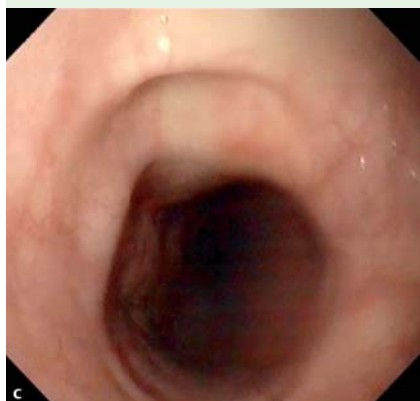
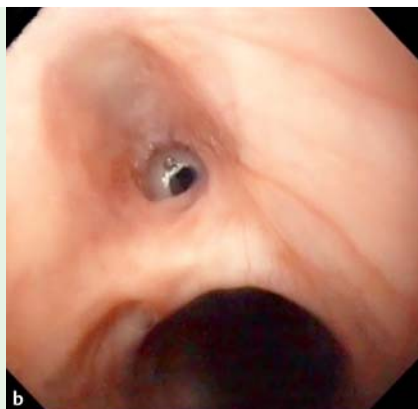
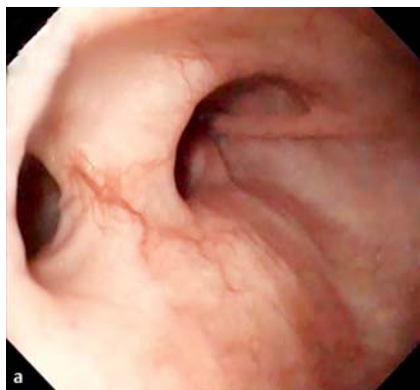

## Multiple esophagopleural and esophagobronchial fistulas in a patient with Crohn's disease



**Fig. 1** Thoracic computed tomography (CT) scan showing a full distended mid and distal esophagus, in continuity with an empyema in the left pleural space.

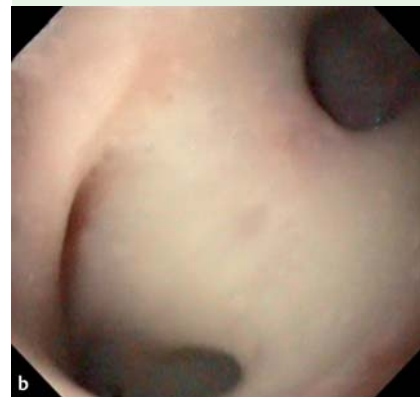
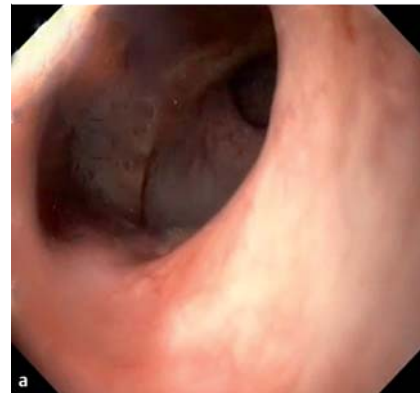
**Fig. 2** Upper gastrointestinal endoscopy revealed: **a** a fistula orifice in the esophagus at 39 cm from the incisors; **b** a fistula orifice with bronchial secretions at 30 cm from the incisors; **c** a fistula orifice with bronchial secretions at 25 cm from the incisors.

A 56-year-old man was admitted because of severe weight loss, anorexia, and dyspnea over a 2-month period. He had been diagnosed in 1985 with Crohn's colitis and in 2001 he was admitted and underwent a total colectomy with formation of an ileostomy because of a severe disease flare. Subsequently, he had missed several follow-up outpatient consultations and was not taking any medication.

On admission he had severe cachexia, anemia, leukocytosis, a low serum albumin, and an elevated C reactive protein level. A thoracic computed tomography (CT) scan showed a fully distended mid and distal esophagus, which was in continuity with an empyema in the left pleural space (▶ **Fig. 1**). Oral nutrition was stopped and antibiotic therapy was started.

An upper gastrointestinal endoscopy was performed (▶ **Video 1**), which revealed multiple esophageal fistulas with bronchoalveolar secretions (▶ **Fig. 2**). It was possible to pass the endoscope through



**Fig. 3** Images taken during upper gastrointestinal endoscopy showing: **a** the passage of the endoscope through one of the fistulas; **b** direct visualization of the bronchi via an esophagobronchial fistula.

these fistulas directly into the bronchi (▶ **Fig. 3**). Histology of a biopsy taken from the esophagus showed active chronic inflammation, without epithelioid granulomas and Ziehl–Nielsen staining was negative. Despite several attempts to improve his biological condition so that surgery might be possible, the patient died on day 7 of his admission, from sepsis and respiratory insufficiency. Fistulas to the bronchi or mediastinum in Crohn's disease are rare [1]. To date, there have been only 15 reported cases of

### Video 1

Upper gastrointestinal endoscopy showing the multiple esophageal fistulas with bronchoalveolar secretions and the endoscope being passed through an esophagobronchial fistula, with subsequent direct visualization of the bronchi.

esophagobronchial fistula in Crohn's disease [2] and to our knowledge the formation of multiple esophageal fistulas has not been previously reported in Crohn's disease. Esophagectomy is considered the definitive treatment, although there have been reports of a case successfully treated with infliximab [3] and another case treated with a synthetic polymer [4].

Endoscopy\_UCTN\_Code\_CCL\_1AB\_2AC\_3AH

**Competing interests:** None

**A. Albuquerque, R. Ramalho,  
G. Macedo**

Gastroenterology Department,  
Hospital de São João, Porto, Portugal

## References

- 1 *Cosme A, Bujanda L, Arriola JA et al.* Esophageal Crohn's disease with esophagopleural fistula. *Endoscopy* 1998; 30: S109
- 2 *Clarke BW, Cassara JE, Morgan DR.* Crohn's disease of the esophagus with esophagobronchial fistula formation: a case report and review of the literature. *Gastrointest Endosc* 2010; 71: 207–209
- 3 *Ho IK, Guarino DP, Pertsovsky Y et al.* Infliximab treatment of an esophagobronchial fistula in a patient with extensive Crohn's disease of the esophagus. *J Clin Gastroenterol* 2002; 34: 488–489
- 4 *Rieder F, Hamer O, Gelbmann C et al.* Crohn's disease of the esophagus: treatment of an esophagobronchial fistula with a novel liquid embolic polymer "onyx". *Z Gastroenterol* 2006; 44: 599–602

## Bibliography

**DOI** <http://dx.doi.org/10.1055/s-0031-1291671>  
*Endoscopy* 2012; 44: E114–E115  
© Georg Thieme Verlag KG  
Stuttgart · New York  
ISSN 0013-726X

## Corresponding author

**A. Albuquerque, MD**  
Gastroenterology Department  
Hospital de São João  
Alameda Professor Hernâni Monteiro  
4200-319 Porto  
Portugal  
Fax: +351-225-025766  
[a.albuquerque.dias@gmail.com](mailto:a.albuquerque.dias@gmail.com)