Band ligation of a T1 esophageal squamous cell cancer in a patient with multimorbidities

Endoscopic band ligation without resection is a technique reported in the literature for the treatment of subepithelial neuroendocrine tumors and Barrett's esophagus, but its use in the treatment of T1 cancer has not been reported [1–4]. We present a case of T1 esophageal cancer in a patient with contraindications for surgery treated endoscopically using banding without resection.

A 74-year-old man presented with anemia, and upper endoscopy revealed a nodular area with raised (10–15 mm), eroded mucosa at 28 cm from the incisors (**Fig. 1**).

Biopsy specimens were positive for squamous carcinoma. Computed tomography revealed no distant metastasis. Surgery was contraindicated owing to the presence of multimorbidities. Endoscopic ultrasound (EUS), using a radial echoendoscope (GF-UE160-AL5; Olympus, Hamburg, Germany), showed an isoechoic focal thickening of the surface layers, 4×10 mm in size. The lesion was compatible with mucosal-submucosal (m-sm) T1 tumor because it had not invaded the muscular propria layer (**Fig. 2**). No pathologic lymph nodes were observed. We decided to treat the lesion in the same EUS procedure. After marking it with indigo carmine and argon plasma coagulation (APC) (**Fig. 3 a**), we applied an elastic band (multiband EMR Duette; Cook Ireland Ltd, Limerick, Ireland) without carrying out resection (**Fig. 3 b**). At the last follow-up 12 months later, only a small scar was present at the site of the banding and biopsy specimens showed no evidence of malignancy (**Fig. 4**).

The drawback of this technique is not having a histological study, which would indicate the degree of T1 tumor involvement (m or sm), for which the lymph node risk is known to be 6% and 29%, respectively [5]. Presence of lymph node involvement is an indication for surgery with lymphadenectomy in T1-sm patients with no surgical risk. In our case, the treating team decided that owing to the patient's condition, either mucosal or submucosal involvement would not have changed the clinical management. In conclusion, management of a T1 esophageal cancer with endoscopic band ligation without resection may be a safe option in patients for whom surgery is contraindicated.

Endoscopy_UCTN_Code_TTT_1AO_2AF

Competing interests: None

Fig. 1 Endoscopic view of an esophageal tumor (T1) in a 74-year-old man with anemia.

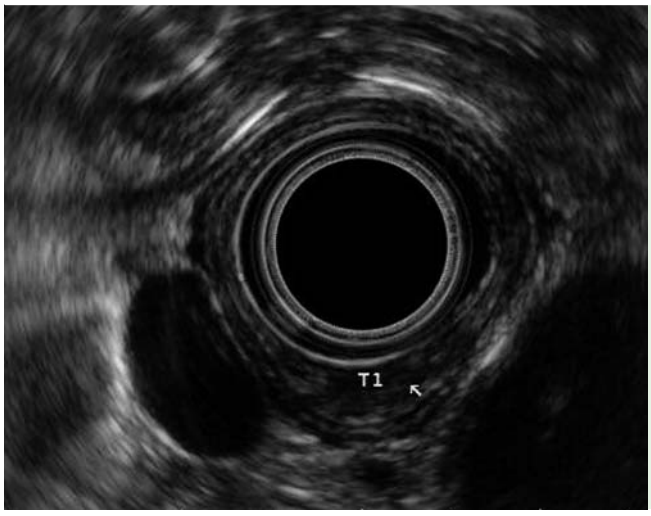

Fig. 2 Endoscopic ultrasound view of the esophageal tumor (T1).

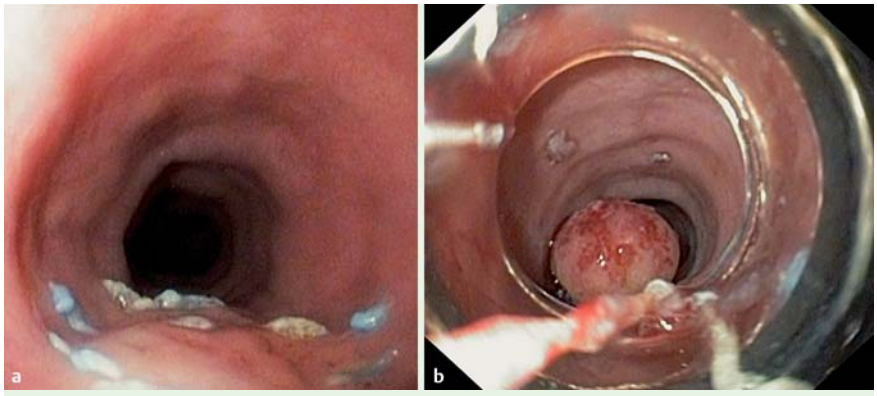

Fig. 3 Endoscopic treatment of the tumor. **a** The lesion marked with indigo carmine and argon plasma coagulation (APC). **b** An elastic band applied without any resection.

Fig. 4 The 12 months' follow-up endoscopic image showing a small scar at the site of banding.

This document was downloaded for personal use only. Unauthorized distribution is strictly prohibited.

S. Salord[1], J. Gornals[1], M. Galan[2], J. M. Botargues[1], J. M. Castellví[3], M. Miró[4]

[1] Department of Digestive Diseases, Hospital Universitari de Bellvitge, Idibell, Barcelona, Spain
[2] Department of Medical Oncology, Institut Català d'Oncologia DiR, Idibell, Barcelona, Spain
[3] Department of Digestive Diseases, Hospital de Mataró del Consorci Sanitari del Maresme, Mataró, Spain
[4] Department of Surgery, Hospital Universitari de Bellvitge, Idibell, Barcelona, Spain

References

1 *Sun S, Ge N, Wang S* et al. EUS-assisted band ligation of small duodenal stromal tumors and follow-up by EUS. Gastrointest Endosc 2009; 69: 492 – 496
2 *Lee SH, Hong YS, Lee JM* et al. Duodenal gastrinoma treated with endoscopic band ligation. Gastrointest Endosc 2009; 69: 964 – 967
3 *Diaz-Cervantes E, De-la-Torre-Bravo A, Jon-Spechler S* et al. Banding without resection (endoscopic mucosal ligation) as a novel approach of the ablation of short-segment Barrett's epithelium: results of a pilot study. Am J Gastroenterol 2007; 102: 1640 – 1645
4 *Sun S, Jin Y, Chang G* et al. Endoscopic band ligation without electrosurgery: a new technique for excision of small upper-GI leiomyoma. Gastrointest Endosc 2004; 60: 218 – 222
5 *Kim DU, Lee JH, Min BH* et al. Risk factors of lymph node metastasis in T1 esophageal squamous cell carcinoma. J Gastroenterol Hepatol 2008; 23: 619 – 625

Bibliography

DOI http://dx.doi.org/10.1055/s-0031-1291755
Endoscopy 2012; 44: E171–E172
© Georg Thieme Verlag KG
Stuttgart · New York
ISSN 0013-726X

Corresponding author

J. B. Gornals
Department of Digestive Diseases
Hospital Universitari de Bellvitge
Idibell (Bellvitge Biomedical Research Institute)
Feixa Llarga Str. s/n
08907 L'Hospitalet de Llobregat
Barcelona
Spain
Fax: +34 93 2607681
jgornals@bellvitgehospital.cat

This document was downloaded for personal use only. Unauthorized distribution is strictly prohibited.