

Pediatric atlanto-occipital dissociation: radiographic findings and clinical outcome

Authors Jean-Pierre du Plessis¹, Stewart Dix-Peek¹, Eduard Bernard Hoffman¹, Nicky Wieselthaler², Robert Neil Dunn¹

Institutions ¹ Division of Orthopaedic Surgery, University of Cape Town, South Africa

² Department of Radiology, Red Cross Children's Hospital, Cape Town, South Africa

ABSTRACT

Study design: Retrospective diagnostic feasibility study and clinical review.

Objectives: To evaluate the feasibility of making an initial atlanto-occipital dissociation (AOD) diagnosis from four radiological measurements of the craniocervical relationship on lateral cervical spine x-rays and to assess the AOD patients' clinical outcomes relative to their magnetic resonance imaging (MRI) findings.

Methods: The Powers ratio, Wackenheim line, basion-dens distance (BDD), and the C1/2:C2/3 interspinous ratio were measured in 58 pediatric controls and ten MRI-confirmed patients with AOD. The ability to identify the required anatomical landmarks and make the measurements was noted and sensitivity and specificity calculated. The correspondence between the clinical presentation and outcomes for patients with AOD and their MRI features was investigated.

Results: Clear landmarks for measuring interspinous ratio and Wackenheim line were confirmed by all x-rays. The BDD was measurable in 90% and the Powers ratio could be calculated in only possible in 59%. The interspinous ratio and BDD offered high sensitivities and specificity. Although the Wackenheim line was consistently measured, it conferred a low sensitivity but reasonable specificity. The Powers ratio offered high specificity with low sensitivity. On MRI, all patients with AOD had apical ligament disruption, with a high rate of interspinous ligamentous injury (8/9); prevertebral swelling (7/9); retroclival hematoma (6/9); and tectorial membrane injury (4/9). The only MRI feature associated with poor outcome was that of altered cord signal. Both patients who died had cord signal changes on T1- and T2-weighted images. The third patient with cord signal change was limited to T2 changes with a normal T1. He had a C5-L3 sensory deficit that resolved. The degree of tectorial membrane injury did not appear to influence outcome.

Conclusions: The BDD and interspinous ratio offer the best measures for initial x-ray diagnosis of AOD. This will alert the surgeon to the need for MRI. These patients often have a reduced level of consciousness, thus making clinical evaluation difficult. The MRI findings, although apparently indicative of severe abnormality, did not actually correspond to outcomes except for the presence of T1 cord signal changes that matched with severe neurological impairment and subsequent death.

Assessment of CoE for individual studies of diagnostic test evaluation.*	
Study design	
Prospective cohort design	
Retrospective cohort design	•
Case-control design	
Methods	
Broad spectrum of patients with expected condition	
Appropriate reference standard used	†
Adequate description of test and reference for replication	•
Blinded comparison with appropriate reference	
Reference standard performed independently of test	
Overall class of evidence	IV

*Blank box indicates criterion not met, could not be determined, or information not reported by author or was not reported.

†MRI was used as the reference but only 9 of 67 patients had MRIs available for review.

The definition for classes of evidence for diagnostic test evaluations is available in the Web Appendix at www.aospine.org/EBSJ.

The author has no conflict of interest for this study. No funding was received for research.

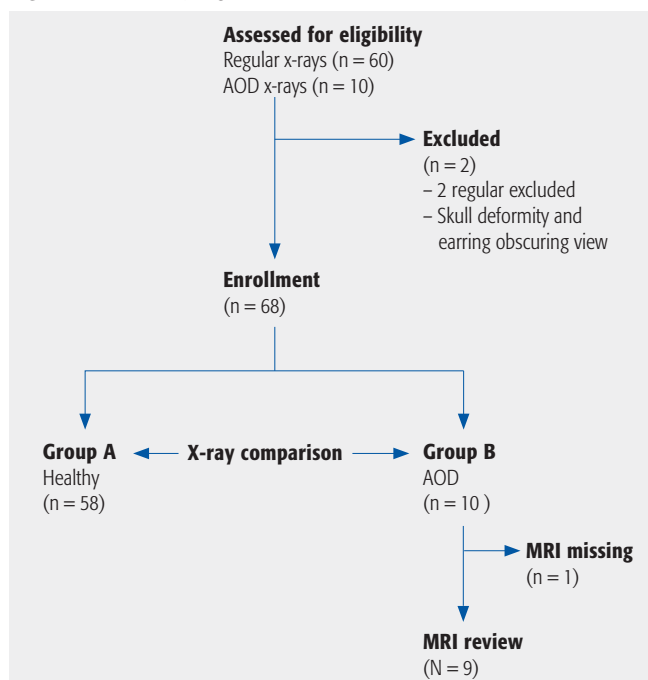
STUDY RATIONALE AND CONTEXT

Atlanto-occipital dissociation (AOD) implies functional instability at the occipitocervical junction caused by partial or complete disruption of the tectorial membrane (rostral inflexion of the posterior longitudinal ligament) and the bilateral alar ligaments [1]. This can be a devastating injury with a high incidence of severe neurological deficit and death. AOD is increasingly encountered due to improved roadside medical management and improved restraint mechanisms, especially in pediatric patients, resulting in more of these patients arriving in the trauma unit alive. Improved imaging and increased vigilance may play a role in the increased diagnosis of this condition [2–4]. Although magnetic resonance imaging (MRI) is effective to confirm ligamentous injury at the craniocervical junction, it is not commonly ordered as first-line imaging or is readily available for the initial diagnosis; therefore, reliance remains on initial cervical spine x-rays as screening tool [5–7].

OBJECTIVES

To evaluate the feasibility of making an initial AOD diagnosis from four radiological measurements of the cranio-cervical relationship on lateral cervical spine x-rays and to assess AOD patients' clinical outcomes relative to their MRI findings.

Fig 1 Patient sampling and selection.



AOD indicates atlanto-occipital dissociation;
MRI, magnetic resonance imaging.

METHODS

Study design:

- For the first part of the study, 58 consecutive regular cervical spine x-rays taken over a 3-month period (November 2006 through January 2007) were retrospectively reviewed and the measurements described below were taken. The ability to identify anatomical landmarks and perform the measurements was evaluated. X-rays were from patients presenting to the Red Cross Children's Hospital trauma unit, Cape Town, South Africa.
- The second part of the study involved the radiological and clinical assessment of ten patients with confirmed AOD presenting between 1999 and 2007. Initial lateral x-rays were reviewed and subjected to the four measurements. The ease of identification of the anatomical landmarks was assessed. Nine of these patients had MRI available for review and MRI features were compared with the x-ray and clinical findings.

Inclusion criteria:

- For standard spine x-rays, we selected only patients aged 12 years and younger due to our hospital admission policy. These patients had been clinically and radiologically assessed as having a regular cervical spine by the orthopaedic surgeon in attendance. The x-rays were obtained in keeping with routine protocol for blunt high-energy (traffic) trauma.

Exclusion criteria (Fig 1):

- Two x-rays from the healthy population were excluded; one due to a preexisting skull deformity and one because earrings obscured the landmarks.

Patient population and selection (Fig 1):

- X-ray and clinical data from 68 patients were available. Fifty-eight regular x-rays and ten x-rays from patients with confirmed AOD (all were pedestrians involved in motor vehicle injuries) were used for evaluation of landmarks and feasibility of measurements.
- For the evaluation of AOD, the patients' diagnosis was confirmed on clinical and MRI investigation. For one patient with AOD, the MRI was not available for analysis.

Radiographic measurements:

- The craniocervical junction was radiographically assessed using four methods of measurement: Powers ratio [8], Wackenheim line [9], basion-dens distance (BDD) [10, 11], and the C1/2:C2/3 interspinous ratio

[12]. The ability to identify the basion and the opisthion was also individually assessed in each x-ray.

- The Powers ratio is the distance measured from the tip of the basion to the posterior arch of C1 divided by the distance from the opisthion to the anterior arch of C1. A ratio of less than 1 is considered standard [8].
- The Wackenheimer line is drawn down the posterior aspect of the clivus, which should tangentially intersect with the tip of the dens [9].
- The BDD is the distance from the tip of the basion to the tip of the dens. Wholey et al [10] described a value of 10 mm or less to be standard. This measurement was also used by Harris et al [11–12] as one of two measures to assess the integrity of the cranio-cervical junction (BAI/BDI). We used Harris' value of 12 mm or less to be standard. This measurement discrepancy is due to the incomplete ossification of the dens tip in the pediatric group.
- Sun et al [13] proposed the use of the ratio of the interspinous distance between C1 and C2 divided by that between C2 and C3. A ratio of more than 2.5 is considered diagnostic of tectorial membrane rupture.
- Clinical data was collated by retrospectively reviewing patients' clinical records.

Outcomes:

- The ability to identify the anatomical x-ray landmarks to complete the measurements in healthy subjects and patients with known AOD as described under x-ray measurements.
- Sensitivity and specificity of Powers ratio, Wackenheimer line, basion-dens distance, and C1/2:C2/3 ratio in diagnosing AOD in MRI-confirmed patients.
- The MRI features of the AOD group in terms of presence of prevertebral soft-tissue swelling, apical ligament disruption, tectorial membrane elevation or tear, retroclival hematoma, posterior C1/2 atlanto-axial membrane injury, and cord signal were assessed by an orthopaedic consultant, registrar and radiology consultant, and agreement was achieved by consensus. Evaluations were not blinded to outcome.
- The neurological outcome and survival of patients with AOD were evaluated.

Analysis:

- The Fisher exact test for categorical data was used to evaluate differences between the healthy and AOD groups with regard to frequency of abnormality and normality based on those in whom measurement was possible for a given parameter. Sensitivity and specificity were calculated based on use of MRI-confirmed diagnosis of AOD.

RESULTS

Population characteristics (Table 1)

- Ages were similar in control group with median 6 years (4–11) and those with AOD with a median of 6 years (1–12).
- Of patients with AOD six were boys and four girls. The gender of the healthy group was not noted in the study.

Radiographic anatomy and measurement of all x-rays (Table 2)

- Of 68 x-rays, the basion could be clearly identified on lateral C-spine x-rays in 61 (90%) and the opisthion in 42 (62%). Thus, although the interspinous ratio and Wackenheimer line had clear landmarks in all x-rays, the BDD was determined in 54 (93%) controls and 7 (70%) patients with AOD, and the Powers ratio was possible in 35 of the controls and 5 of the AOD group.
- The interspinous ratio and BDD was applied in more than 90% of the x-rays and offered high sensitivities and specificity. Although the Wackenheimer line was visible on all x-rays, it conferred a low sensitivity but reasonable specificity. Powers ratio was obtained in only 59% of x-rays but offered a high specificity with low sensitivity (Tables 2–4 and Fig 2).

The number of patients with abnormal BDD and interspinous ratio in the AOD group was statistically greater compared with the healthy x-ray group ($P < .001$).

MRI results of the AOD group

- The MRI images of nine of the ten patients with AOD were available for review.
- Features of prevertebral soft-tissue swelling, apical ligament disruption, tectorial membrane elevation or tear, retroclival hematoma, posterior C1/2 interspinous ligamentous injury, and cord signal were noted as tabulated (Table 3). The apical ligament was never directly visualized, but the hematoma at the tip of the dens was considered indicative of ligament disruption at this level. The retroclival area was assessed for hematoma between the clivus and the tectorial membrane. The tectorial membrane was examined for loss of structural integrity that we defined as either disruption of continuity or elevation of the clivus by a retroclival hematoma (Figs 3–4).
- All had apical ligament disruption, with a high frequency of interspinous ligamentous injury (8/9), prevertebral swelling (7/9), retroclival hematoma (6/9), and tectorial membrane injury (4/9) (Table 5).
- Only three patients with AOD had evidence of spinal cord signal changes, two had both T1 and T2 changes and one T2 changes only.

Clinical features and outcome of patients with AOD

- The charts of the nine MRI-confirmed patients with AOD were reviewed. All were involved in motor vehicle injuries as pedestrians.
- Five were intubated on arrival, with two exhibiting cardiovascular instability. Six had neurological compromise on admission. Two patients who died were complete quadriplegics, while the other four had cranial nerve palsies with some incomplete spinal cord. Two of these four improved to normal neurological status based on clinical examination.
- The two patients who died had associated closed head injuries but no abdominal or chest trauma. One of these patients had a closed femoral shaft fracture. The patients with the less severe cervical spine injuries had associated injuries including blunt abdominal trauma with splenic rupture (two patients), lung contusion and humeral fracture.
- All patients had closed head injuries of varying severity.
- The only MRI feature associated with poor outcome was that of spinal cord signal. Both deaths had cord signal changes on T1- and T2-weighted images. The third patient with cord signal change was limited to T2 changes with a normal T1. He had a C5-L3 sensory deficit that resolved.
- The degree of tectorial membrane injury did not appear to influence outcome.

DISCUSSION

- The initial diagnosis of AOD relies on evaluation of the craniocervical anatomical relationships most commonly available for review on first lateral screening x-rays of the cervical spine using a number of accepted reference lines for assessment as described earlier in the text. Diagnosis relies on the experience of the trauma team and their communication and the quality of the x-rays to be able to identify the required landmarks [8–13]. Suboptimal positioning of x-ray results in variable magnification or obliquity that may render direct measurement inaccurate. Thus, a combination of absolute measurement and ratios would appear preferable [13].
- Having reliable reference lines and screening ratios is important to alert clinicians to potential AOD and lead to subsequent neuroimaging.
- The low sensitivity of the Powers ratio and the limited number of x-rays to which it could be applied, however, makes it a less useful measurement in clinical practice.
- The Wackenheim line, although easily measured, has a low sensitivity and specificity and was not a useful tool for the initial screening diagnosis. In addition, the original study [9] describing this method indicates that it is only applicable when measured on a weight-bearing x-ray (ie, in a seated patient), which is not practical in the severely injured trauma patient.

Fig 2 The percentage sensitivity, specificity and the ability to identify the anatomical landmarks required to perform the x-ray measurement. BDD indicates basion-dens distance.

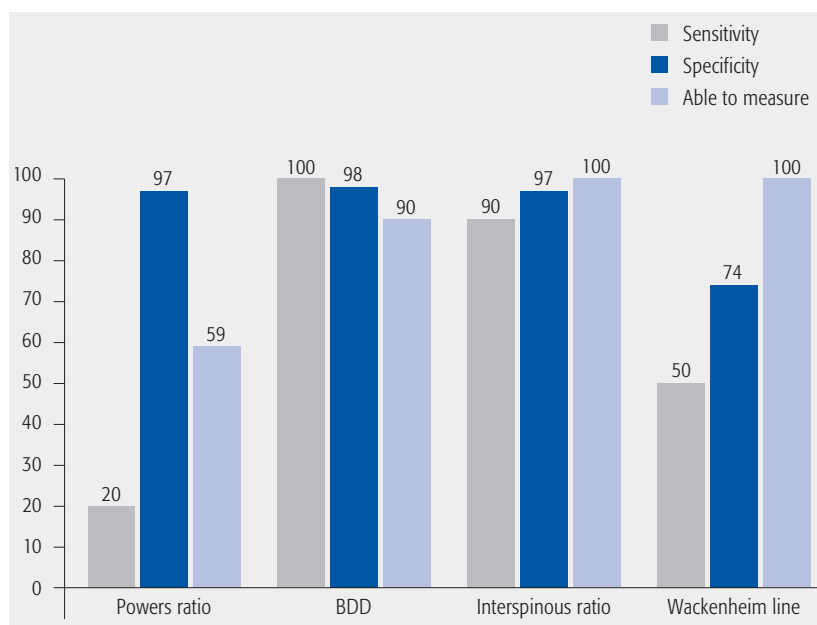


Table 1 Patient Characteristics and clinical factors.

	AOD cases N = 9	Normal N = 58
Patient Characteristics:		
Age, years (median)	6 (4–11)	6 (1–12)
Male, n (%)	67	Not reported
Clinical Factors:		
Head injury	9	
Glasgow coma scale <14	6	
Intubated	5	
Quadraplegic	2	
Cranial nerve injury	4	
Splenic rupture	2	
Limb fracture	2	

- In our study, the BDD and interspinous ratio were the most sensitive and specific methods of measurement. The basion was a more easily identifiable landmark on the lateral C-spine x-ray than the opisthion. The BDD was thus more consistently measurable due to identifiable anatomical landmarks than the Powers ratio. The landmarks for the interspinous ratio were always identifiable, making it the most consistently applicable method of measurement.
- These measures serve to alert trauma team members to the potential of AOD; however, MRI and CT remain vital for further evaluation of injured structures, especially the spinal cord.

Strengths

- A large control group of consecutive cervical x-rays allowed representation of the pediatric population group.
- Use of a single dedicated pediatric institution allowed standardization of the x-ray technique to maximize the quality of x-rays and despite this confirm the difficulties with such radiological measurements.

Limitations

- The small numbers in the AOD group due to rarity of condition may not represent the population fully, especially because of age differences. Outcomes are likely skewed by the primary injury severity of the cranio-cervical region and associated injuries.

Table 2 Results of x-ray measurements.

	Control x-rays (n=58)			AOD group x-rays (n=10)			P-value*
	Normal	Abnormal	Unable to measure	Normal	Abnormal	Unable to measure	
BDD	53	1	4	0	7	3	<.001
Powers ratio	34	1	23	4	1	5	.22
Wackenheimer line	43	15	0	5	5	0	.09
Interspinous ratio	56	2	0	1	9	0	<.001

* Based on Fischer's exact test comparing x-ray findings for the normal and AOD groups (among those for whom measurement was possible).

Table 3 Summary of data used to determine sensitivity and specificity.

Diagnostic Criterion	AOD present* (n = 10)	AOD absent* (n = 58)	Totals
Powers Ratio			
>1	1	1	2
<1	4	34	38
Totals	5	35	40
Wackenheimer Line			
not intersecting dens	5	15	18
intersecting dens	5	43	48
Totals	10	58	66
BDD			
>12 mm	7	1	8
≤ 12 mm	0	53	53
Totals	7	54	61
Interspinous ratio			
>2.5	9	2	11
≤ 2.5	1	56	57
Totals	10	58	68

* Based on MRI diagnosis of AOD in 10 patients with MRI. One patient's MRI was not available for review in study but reported at time of investigation as AOD. X-ray available for review

Table 4 Specificity and Sensitivity Calculations.

Test	Specificity Calculation*
Powers	$34 / (1 + 34) = 97\%$
Wackenheimer	$43 / (15 + 43) = 74\%$
BDD	$53 / (1 + 53) = 98\%$
Interspinous ratio	$= 56 / (2 + 56) = 97\%$
Test	Sensitivity Calculation†
Powers	$1 / (1 + 4) = 20\%$
Wackenheimer	$5 / (5 + 5) = 50\%$
BDD	$7 / (7 + 0) = 100\%$
Interspinous ratio	$9 / (9 + 1) = 90\%$

* Specificity = true negative / (False positive + true negative)

† Sensitivity = True positive / (True positive + False negative)

Table 5 MRI features of the 9 AOD MRI's available for review.

Prevertebral Soft tissue swelling	7
Apical ligament injury	9
Tectorial membrane elevated but intact	5
Tectorial membrane ruptured	4
Retroclival haematoma	6
Cord signal	3
Posterior interspinous ligament	8

- The radiology review, not blinded, may have led to bias when assessing integrity of ligaments and determining the x-ray measurements as they would be expected to be abnormal when the reviewer knew there was an established clinical AOD.
- The CT scan was not used in this series because of prevalent trauma imaging algorithm in our facility. Although this can be seen as a weakness, plain x-ray as primary trauma workup modality of choice has remained the principal measurement. Routine MRI scanning in our trauma population was indicated due to concerns for neurological and soft-tissue integrity.

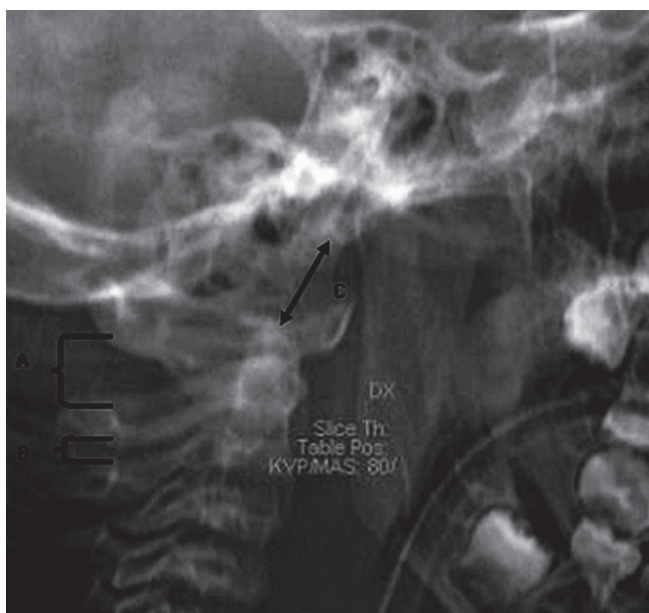
Clinical relevance and impact

The BDD and interspinous ratio appear to be the best measures for initial x-ray diagnosis of AOD. Abnormal findings will alert the surgeon to the need of an MRI. These patients often have a reduced level of consciousness and have limited capacity for cooperation, making clinical evaluation difficult.

The MRI findings of hematoma and ligamentous disruption suggest severe abnormality, in fact they did not appear to correspond with clinical/neurological outcomes except for the presence of T1 cord signal changes.

There is a need to confirm these findings and for reliability/reproducibility studies on the various measurements and the extent to which experience may influence them.

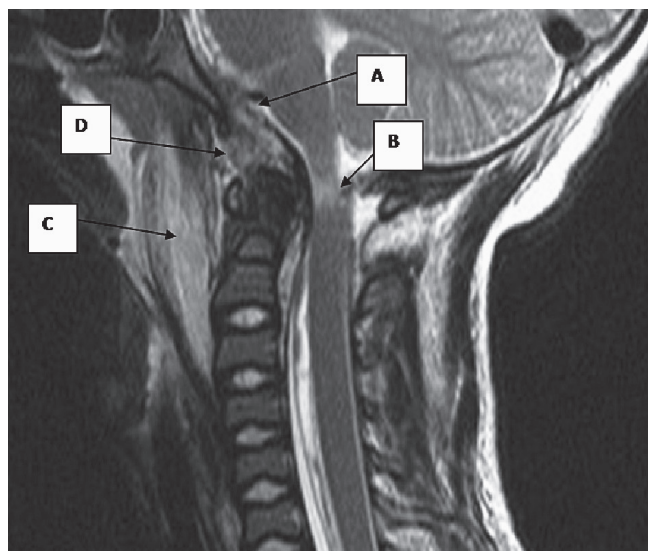
Fig 3 A lateral cervical spine x-ray showing an abnormal interspinous ratio $A/B > 2.5$ and increased basion-dens distance (arrow, C).



SUMMARY AND CONCLUSIONS

- Atlanto-occipital dissociation is an important finding and timely recognition of this injury can be a potentially life-saving or cord-saving action, especially in pediatric patients.
- While the number of our injured patient population was relatively small, we found lateral C-spine x-rays taken in the trauma unit to be diagnostic of AOD when a combination of measurements was used. The BDD and the interspinous ratio were both sensitive and specific screening tests for the assessment of the cranio-cervical relationship.
- When the anatomical landmarks are identifiable, the Powers ratio can also be useful.
- An MRI scanning is useful to confirm the diagnosis of injury at this level, to localize ligamentous structures injured through direct visualization of the soft tissues, and to directly visualize the cord as a primary outcome determinant.

Fig 4 T2-weighted image of a patient with atlanto-occipital dissociation who had a ruptured tectorial membrane (A), cord injury (B), prevertebral soft-tissue swelling (C), and hematoma at the tip of the dens (D).



REFERENCES

1. **Davis D, Bohlman H, Walker AE, et al** (1971) The pathological findings in fatal craniospinal injuries. *J Neurosurg*; 34(5):603–613.
2. **Traynelis VC, Marano GD, Dunker RO, et al** (1986) Traumatic atlanto-occipital dislocation: case report. *J Neurosurg*; 65(6):863–870.
3. **Papadopoulos SM, Dickman CA, Sonntag VKH, et al** (1991) Traumatic atlantooccipital dislocation with survival. *Neurosurgery*; 4:574–579.
4. **Bulas DI, Fitz CR, Johnson DL** (1993) Traumatic atlanto-occipital dislocation in children. *Radiology*; 188(1):155–158.
5. **Grabb BC, Frye TA, Hedlund GL, et al** (1999) MRI diagnosis of suspected atlanto-occipital dissociation in childhood. *Pediatr Radiol*; 29(4):275–281.
6. **Naso WB, Cure J, Cuddy BG** (1997) Retropharyngeal pseudomeningocele after atlanto-occipital dislocation: report of two cases. *Neurosurgery*; 40(6):1288–1290.
7. **Willauschus WG, Kladny B, Beyer WF, et al** (1995) Lesions of the alar ligaments: in vivo and in vitro studies with magnetic resonance imaging. *Spine (Phila Pa 1976)*; 20(23):2493–2498.
8. **Powers B, Miller MD, Kramer RS, et al** (1979) Traumatic anterior atlanto-occipital dislocation. *Neurosurgery*; 4(1):12–17.
9. **Wackenheim A** (1974) Angles and lines of measurement in the craniovertebral region. In: *Roentgen Diagnosis of the Cervical-Vertebral Region*. New York: Springer-Verlag; 81–86.
10. **Wholey MH, Bruwer AJ, Barker HL Jr** (1958) The lateral roentgenogram of the neck: with comments on the atlanto-odontoid-basion relationship. *Radiology*; 71(3):350–356.
11. **Harris JH Jr, Carson GC, Wagner LK, et al** (1994) Radiologic diagnosis of traumatic occipitovertebral dissociation: 2. Comparison of three methods of detecting occipitovertebral relationships on lateral radiographs of supine subjects. *Am J Roentgenol*; 162:887–892.
12. **Harris JH Jr, Carson GC, Wagner LK** (1994) Radiologic diagnosis of traumatic occipitovertebral dissociation: 1. Normal occipitovertebral relationships on lateral radiographs of supine subjects. *Am J Roentgenol*; 162:881–886.
13. **Sun P, Poffenbarger J, Durham S, et al** (2000) Spectrum of occipitoatlantoaxial injury in young children. *J Neurosurg*; 93(1 Suppl):28–39.

EDITORIAL PERSPECTIVE

The EBSJ reviewers congratulate the authors on tackling this important and often overlooked topic. This injury is difficult to deal with due to its relatively rare occurrence, and due to the danger of missing this injury with frequently catastrophic consequences. Discussion points pertaining to this article were raised as follows:

1. No CT-Scan? A preeminent point of concern was the use of plain x-rays and then switching to Magnetic resonance imaging (MRI) without using Computer Tomography (CT). In most North American and Central European emergency departments the preferred initial workup for patients with cranial trauma is that of helical type CT scanning with reformats, due to time and resource efficiencies. The main drawback of this rapid acquisition technique is an increased radiation burden to the patient. Plain x-rays are accordingly less commonly obtained. Reference studies without CT data have decreased relevance in a more CT-based algorithm.
2. One reviewer suggested reporting the positive predictive value (PPV) or negative predictive value (NPV). Given the small numbers of patients with the condition used for validation, and uncertainty that the prevalence in this study represents the true prevalence in the population, these measures of accuracy may be misleading. For a brief review of PPV/ NPV calculation please consider the following:

First consider the usual 2x2 table:

- True positive (TP) results (cell a) = number of individuals with a disease who test positive
- False positive (FP) results (cell b) = number of individuals without a disease who test positive
- False negative (FN) results (cell c) = number of individuals with a disease who test negative
- True negative (TN) results (cell d) = number of individuals without a disease who test negative

Diagnostic test	True classification	
	Disease present (+)	Disease absent (-)
Disease present (+)	a = TP	b = FP
Disease absent (-)	c = FN	d = TN
	a + c	b + d

The number of patients who truly have the disease is given by $a + c$ and the number who truly do not have disease is given by $b + d$.

When a true gold standard or appropriate reference standard is used and the study population has a frequency of disease that approximates the frequency of disease in the population to which the results are to be applied (or the frequency of the disease in the population to which the test is to be applied is known), two additional measures of test accuracy can be used. These are the predictive value of a positive test (PPV) and the predictive value of a negative test (NPV) and are described as follows:

Term	Definition	Calculation
PPV =	% of patients with a positive test who have the disease	$= a/(a + b) \times 100$
NPV =	% of patents with a negative test who do NOT have the disease	$= d/(c + d) \times 100$

The number of patients who truly have the disease is given by $a + c$ and the number who truly do not have disease is given by $b + d$.

Alternatively:

$$PPV = \frac{\text{(sensitivity) (prevalence)}}{\text{(sensitivity) (prevalence) + (1 - specificity) (1 - prevalence)}}$$

$$NPV = \frac{\text{(sensitivity) (1 - prevalence)}}{\text{(sensitivity) (1 - prevalence) + (1 - specificity) (prevalence)}}$$

The PPV and NPV estimates are only accurate and meaningful if the actual proportion of true positives in the relevant population is represented by $(a + c)/n$. In other words, the actual prevalence of disease in the relevant population must be accurately estimated by the study population or it must be known for the population that is to be tested; otherwise, the predictive values are misleading [1,3]. If the test is done in a population with a very low frequency of disease, for example, the PPV is quite low, even if the sensitivity and specificity are high.

3. Reliability: metrics – the human factor: Why was inter-rater or intra-rater reliability not assessed? It appears that images were reviewed by consensus. In assessing validity of diagnostic tools and techniques of any sort inter and intra observer, reliability has become a valuable tool for evaluation of strengths and shortcomings of individual modalities and techniques.

4. Bimodal MRI: The reviewers identified that the MRI measurements described appear subjective and were likely Boolean in nature (ie, yes/no, intact/disrupted). Do the authors see a role for objective, standardized measures for MRI findings in cranio-cervical trauma, which could be used instead?

5. BDI or BDD? What’s in an acronym? The Basion-Dens distance described by the authors seems to be identical to the Basion-Dens interval (BDI) used by Harris in the past. The reviewers were wondering why the name change had been performed. In principle it is desirable to use established terms unless there are flaws in those and avoid adding to the clutter of overlapping terms. New terms require specific definitions and possibly further validation studies.

6. But what happened to the patients? The present study emphasizes imaging and is relatively light on patient outcomes. The reviewers suggested a follow-up clinical outcomes study with review of missed injuries, and neurologic evolution through injury, first, intermediate and final presentation as well as the care modalities applied. Since this is a pediatric cohort of reasonable size this is actually a reasonably relevant case series, especially if a denominator and a consecutive nature of care can be established.

1. Weiss NS (2006) *Clinical Epidemiology: The study of the outcome of illness* / Noel S. Weiss. 3rd ed. New York: Oxford University Press.

2. Armstrong B, White E, Saracci R (1992) *Principles of Exposure Measurement in Epidemiology*: Oxford University Press.

3. Koepsell T, Weiss N (2003) *Epidemiologic methods: studying the occurrence of illness*. New York: Oxford University Press, Inc.