

53–56

---

# C1-C2 fusion: postoperative C2 nerve impingement—is it a problem?

---

Authors Kurt D Myers, Emily M Lindley, Evalina L Burger, Vikas V Patel

Institution The Spine Center, Department of Orthopaedics, University of Colorado, Denver, CO, USA

---

## ABSTRACT

**Objective:** The purpose of this comparison case study is to show a potential complication associated with atlantoaxial fusion, and the preoperative evaluation that could help to avoid it.

**Background data:** The use of lateral mass screw fixation in atlantoaxial fusion has provided surgeons the ability to create rigid fixation, with a high success rate of fusion. While the use of screws for fixation is relatively easy to adopt, the risk of causing neurological damage to the patient is ever present. Many major structures, such as the vertebral artery, carotid artery, and spinal cord, must all be considered during surgery.

**Methods:** A comparison of two patients who underwent the same procedure was reviewed—the first had no complications from surgery and the second underwent revision surgery because of the C1 screw impinging on the C1 nerve exiting the foramen.

**Results:** After removal of the C1 screw and converting to a cable technique, the patient made a full recovery and neurological function was restored.

**Conclusions:** When considering C1-C2 lateral mass screw fixation for atlantoaxial fusion, the size of the foramen should be considered. If the foramen is significantly narrowed, alternate fixation should be selected.

---

No funding was received for this work, nor are there any conflicts of interest.

## INTRODUCTION

Atlantoaxial arthrodesis is inherently a difficult procedure with several surgical options for attaining fusion. Aside from cable fixation, upper C-spine screw fixation techniques include posterior transarticular screw fixation, pars screw placement, pedicle screw placement, and translaminar screw placement [1]. Before screw fixation became a popular technique for arthrodesis, wiring techniques developed by Gallie, Brooks and Jenkins were most commonly used [1]. Later, Magerl developed an instrumentation technique using transarticular screws [2, 3]. Various challenges to this technique lead to the gradual evolution of segmental fixation. Lateral mass screw placement with pedicle screw fixation was probably described first by Goel et al in 1994, with Harms and Melcher [4] describing clear landmarks and use of polyaxial screws and rods for fixation. A further variation of posterior upper cervical fixation was developed by Wright out of concern for possible violation of the vertebral artery at C2 by crossing two intralaminar screws to achieve fixation [5, 6]. Any upper cervical spine fixation technique is technically demanding, with some risk of injury to the vertebral artery, carotid artery, spinal cord, and exiting cervical nerve roots. Posterior C1 lateral mass screw placement can be especially challenging because of the location of the C2 exiting root relative to the most commonly suggested starting point located below the C1 laminar ridge on the posterior aspect of the inferior C1 lateral mass.

This comparison case study presents the impingement of a C2 root in its foraminal exit zone through C1 lateral mass screw placement.

## CASE REPORTS

### Case 1

A 69-year-old woman presented with a primary complaint of neck pain and radiculopathy, existing for the previous 11 months, which radiated from the base of her neck into her occiput. After failing nonoperative care and temporarily responding favorably to selective C2 root injections, it was determined that C1-C2 facet had become significantly degenerated and a posterior fusion was offered to the patient (Fig 1).

### Surgical procedure

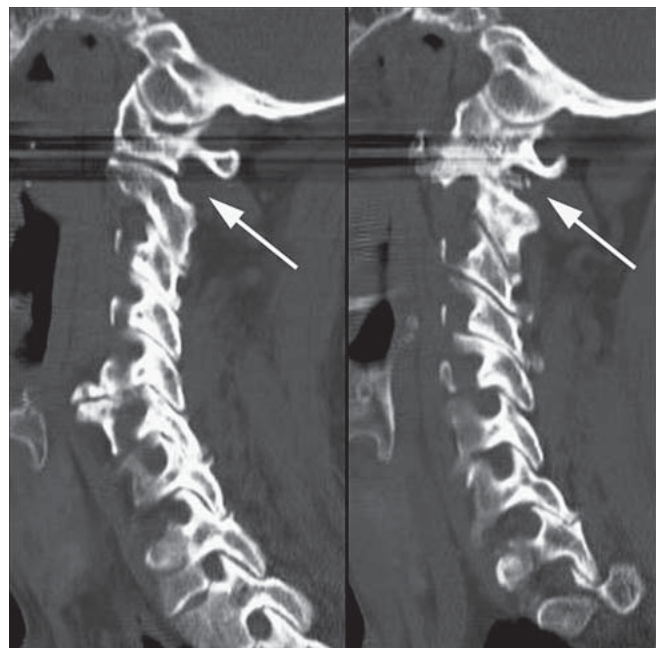
The surgery was performed with the patient prone in a Mayfield head holder on a Jackson OSI table. Uneventful posterior midline exposure of the C1 and C2 segments was carried out. The left and right C2 nerve roots were dis-

sected. The C2 nerve root on the right side was found to be prominent and substantially thickened, which blocked the retraction of that nerve root. After identifying the medial border of the posterior arch of the C1, small holes were drilled to facilitate access to the C1 lateral mass. Two 22 mm screws were inserted at a 15-degree angle. Two trans-laminar screws were placed in the lamina of C2, both on the left and right sides. The screws were then connected by 3.5 mm rods between C1 and C2, using a torque driver to lock them into place. The patient remained stable throughout the entire surgery, which was completed without any obvious complication. Six weeks postoperatively she stated that she was totally pain free.

### Case 2

A 75-year-old woman with a history of rheumatoid arthritis was evaluated because of dominant neck pain that had been present for 8 months. There was no history of trauma, or significant episodes of prior neck pain. The pain was localized on the right side of her neck and radiated cranially. Conservative treatment modalities including activity modification, physical therapy, and medications did not improve the symptoms. Computed tomographic (CT) scans showed degenerative changes of the discs at C5-C6, autofusion at C2-C3, and right facet arthropathy at C1-C2 (Fig 2). Before the procedure, she received an

**Fig 1** Computed tomographic images of patient 1 showing adequate foraminal space on the left and foraminal impingement on the right due to facet arthropathy.



The arrow on the left points to the C2 nerve root, which runs through a patent foramen. On the right the arrow shows a large posterior osteophyte impinging upon the C2 nerve root.

injection at the C2-C3 facet to help confirm if the pain was coming from the joint. After she had received no relief from the injection, but with confirmed significant relief from a prior C2 root injection, it was decided that the pain was localized to the degenerated C1-C2 articulation. The patient elected to proceed with C1-C2 arthrodesis to relieve her pain.

### Surgical procedure

With the patient prone in a Mayfield head holder on a Jackson table, posterior exposure of the C1 and C2 segments was carried out and the C2 roots were bilaterally exposed. Then, 30 mm C1 lateral mass screws were placed under image intensifier guidance using standard technique of identification of local landmarks. Partial laminectomy was performed at C2 and the spinous process of C2 was identified as the drilling point. Next, 30 mm translaminar screws were placed at C2 directed by blunt probe diagonally across, between the two layers of the lamina. The construct was locked together with the rod system and set screws. A torque driver was used to solidly lock the rods and screws together. The procedure was completed without obvious complications.

### Postoperative course

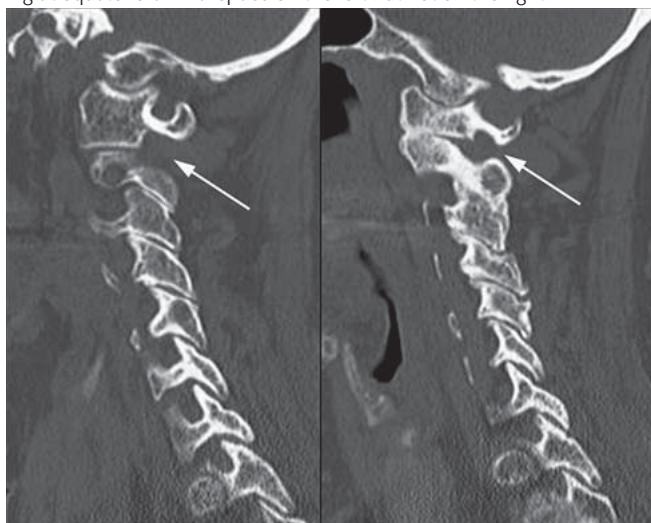
On postoperative day 1, the patient started rehabilitation but was limited because of a new onset of severe positional headaches occurring on the right side of her head. She also complained of multiple episodes of nausea and vomiting, which were initially believed to be caused by the anesthesia. However, she continued to report persistent headaches on postoperative days 2 and 3. On postoperative day 3, CT scans showed an encroachment on the nerve root by the surgical screws into the foramen of C1-C2 (**Fig 3**). To

correct this problem, on postoperative day 4, the patient underwent a second operative procedure in which the right C1 screw was removed, and a sublaminar cable was placed around the C1 arch and fixated with the head of the C2 laminar screw. She was discharged 4 days later from the hospital and returned home in a cervical collar. On postoperative day 10, after the second surgery, the patient began rehabilitation and reported that her pain was under control and the recurring headaches had stopped. At the 3-month postoperative visit, she stated her neck pain had completely resolved. The patient's 3-month postoperative CT scan showed early fusion, and stable instrumentation. She continued to do well at her 6-month and 1-year visits.

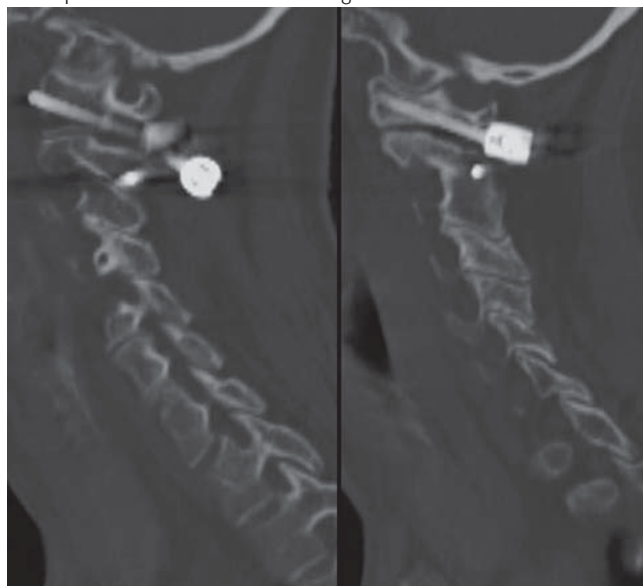
### DISCUSSION

Indications for atlantoaxial fusion include congenital abnormality of the dens, atlantoaxial rotatory subluxation, fracture of the dens, and rheumatoid arthritis [1]. Patients with congenital abnormality of the dens, atlantoaxial rotatory subluxation, fracture of the dens, and rheumatoid arthritis all may benefit from C1-C2 arthrodesis with segmental instrumentation. In general, patients with rheumatoid arthritis seem to be affected by increased complications because of comorbidities and loss of normal anatomy caused by destructive changes [7]. Atlantoaxial arthrodesis has evolved from cable and wiring methods to the use of contemporary rigid segmental screw fixation techniques. These advancements of technique have allowed for better fusion rates with increasing stabiliza-

**Fig 2** Left and right computed tomographic images of patient 2 showing adequate foraminal space on the left but not on the right.



**Fig 3** Left and right computed tomographic images of patient 2 after screw placement. The screw on the right fills the foramen.



tion of C1-C2 while maintaining desirable alignment and avoiding postoperative halo-vest immobilization [2, 3]. Grob et al [2] demonstrated in a case study of 161 patients that the technique developed by Magerl et al for atlantoaxial fusion through transarticular screw fixation is possible with relative safety. Case series by Wang et al [8] and Bransford [9] showed safe placement of lateral mass screws to be possible. With these improvements, segmental screw fixation of the atlantoaxial joint seems to be more widely used [9].

As shown in our case 2, screw impingement in the presence of altered anatomy likely contributed to the patient's symptoms. Once the offending screw was removed, her pain improved dramatically. Based on her rapid symptom resolution we believed that this was due to C1 lateral mass screw impingement on the C2 nerve root. The subject of screw impingement on C2 roots has been described as a more theoretical worry with little or no clinical consequence. In case of controversy, neurolysis or intentional neurotomy of the C2 root had been suggested as a method to avoid root irritation, but we found no clear guidance in the literature on this subject [4].

## REFERENCES

1. **Menendez JA, Wright NM** (2007) Techniques of posterior C1-C2 stabilization. *Neurosurgery*; 60(Suppl 1):S103–111.
2. **Grob D, Jeanneret B, Aebi M, et al** (1991) Atlanto-axial fusion with transarticular screw fixation. *J Bone Joint Surg Br*; 73(6):972–976.
3. **Finn MA, Apfelbaum RI** (2010) Atlantoaxial transarticular screw fixation: update on technique and outcomes in 269 patients. *Neurosurgery*; 66(3 Suppl):184–192.
4. **Harms J, Melcher RP** (2001) Posterior C1-C2 fusion with polyaxial screw and rod fixation. *Spine (Phila Pa 1976)*; 26(22):2467–2471.
5. **Wright NM** (2004) Posterior C2 fixation using bilateral, crossing C2 laminar screws: case series and technical note. *J Spinal Disord Tech*; 17(2):158–162.
6. **Ma W, Feng L, Xu R, et al** (2010) Clinical application of C2 laminar screw technique. *Eur Spine J*; 19(8):1312–1317.
7. **Hirano K, Matsuyama Y, Sakai Y, et al** (2010) Surgical complications and management of occipitocervical fusion for cervical destructive lesions in RA patients. *J Spinal Disord Tech*; 23(2):121–126.
8. **Wang S, Wang C, Wood KB, et al** (2010) Radiographic evaluation of the technique for C1 lateral mass and C2 pedicle screw fixation in three hundred nineteen cases. *Spine (Phila Pa 1976)*; 36(1):3–8.
9. **Bransford RJ, Russo AJ, Freeborn M, et al** (2011) Posterior C2 instrumentation: accuracy and complications associated with four techniques. *Spine (Phila Pa 1976)*; 36(14):E936–943.

Given this limited case experience and our review of the literature, we are less clear about ideal management of patients intended for posterior segmental C1-C2 fixation. In case of a shallow inferior C1 lateral mass, seen in Fig 2, alternate fixation such as transarticular screw placement or cable-based arthrodesis might be preferable. Based on our review of the literature, management of a C2 root caused by screw impingement seems less than clear.

## CONCLUSION

Currently, there seems to be no agreement in the literature as to management of a C2 root being impinged intraoperatively. Is it acceptable to allow for screw impingement on the C2 root and can it be watched expectantly or can the C2 root be cut without undue consequences to the patient? Based on our limited experience, we prefer using alternative techniques for fixation in such cases and avoid either scenario.

## EDITORIAL PERSPECTIVE

*Posterior segmental fixation of the atlanto-axial motion segment has become a very sophisticated procedure with increasing popularity of C1 lateral mass fixation having become quite popular. As identified by the article's authors and Dr. Massicotte, successful completion of such a procedure is dependent upon intricate knowledge of the anatomy by the operating surgeon. The issue of variability of posterior arch anatomy of C1 emerges as an important factor in surgical planning. Posterior C1 lateral mass screw placement can be performed from a lower inferior articular process starting point (Harms technique) or in a more rostral location with a starting point close to or within the posterior lamina ridge. A lower lateral mass starting point has the advantage of staying away from the vertebral artery – an instinctively appealing option. However, this screw placement may require displacement of the C2 root. The effects of screw based C2 nerve root impingement remain poorly understood – as is the outcome from the other option – transection of the C2 root.*

*Based on this case report and the insights offered by Dr. Massicotte we suggest using sagittally and coronally reformatted CT scans to plan for the safest and most predictable C1 screw placement. Of course, the utmost care should be exercised to avoid vertebral artery injury with either technique. We suggest that the discussed variables of C2 root passage after C1 lateral mass screw placement be assessed prospectively in relation to a number of listed variables. (Option 1: No root impingement; Option 2: Impingement with threaded screw; Option 3: Impingement with nonthreaded 'shaft' screw; Option 4: C2 nerve root transection.)*