Endoscopic ultrasound-guided transgastric biliary metal stent placement after dilation with tapered-tip Teflon catheters and marking with a clip

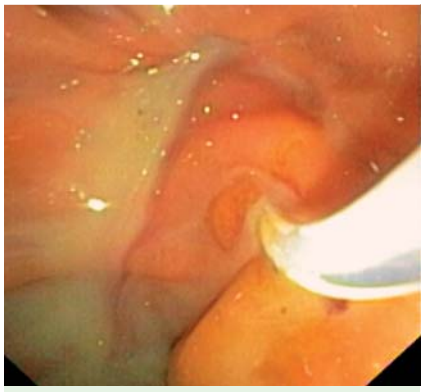

Fig. 1 View during endoscopic retrograde cholangiopancreatography (ERCP) for biliary drainage performed in a 73-year-old man with suspected gallbladder cancer showing a large amount of purulent discharge being released on deep cannulation of the common bile duct.

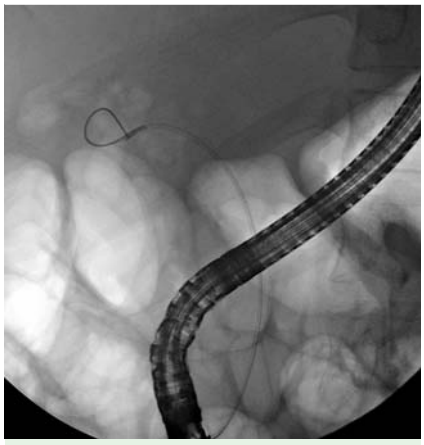

Fig. 2 Radiographic image during endoscopic retrograde cholangiopancreatography (ERCP) showing that the guide wire could not be passed across the tumor site.

Fig. 3 Endoscopic view showing a metal clip that had been placed through the duodenoscope positioned next to the ampulla to assist with localization.

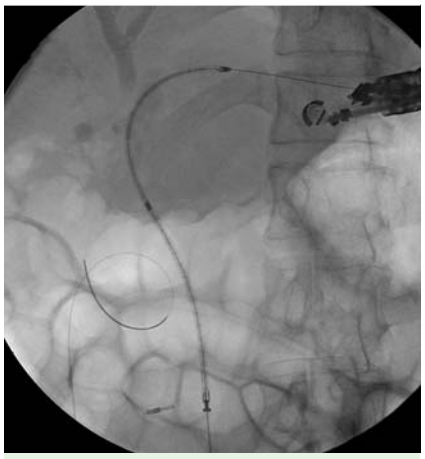

Fig. 4 Radiographic image showing insertion of the stent in an antegrade fashion using an endoscopic ultrasound (EUS)-guided rendezvous technique.

Fig. 5 Radiographic view showing the position of the stent following insertion into the common bile duct.

Fig. 6 Endoscopic view of the stent following successful insertion into the common bile duct.

We report the case of a 74-year-old man with known type 2 diabetes mellitus, hypertension, and retinal detachment who was referred for endoscopic retrograde cholangiopancreatography (ERCP) because of a fever and severe upper abdominal pain for a few days. An ultrasound of his upper abdomen showed a 4 × 5-cm heterogeneous hypoechoic area in the gallbladder fossa with intrahepatic bile duct dilatation, which it was suspected was due to gallbladder cancer. He therefore proceeded to ERCP for biliary drainage.

The patient was given intravenous sedation and was placed in the left lateral decubitus position. After duodenal intubation, cannulation of the common bile duct (CBD) was performed with the release of a large amount of purulent discharge (▶ **Fig. 1**). We were unable to pass the guide wire into the intrahepatic ducts because of intracavitary tumor (▶ **Fig. 2**). Therefore, we decided to perform endoscopic ultrasound (EUS)-guided antegrade stent placement using the rendezvous technique.

A metal clip (Quick Clip HX-201UR-135; Olympus Medical Systems, Tokyo, Japan) was placed through the duodenoscope just beside the ampulla for localization (▶ **Fig. 3**). We then punctured segment 2 of the left lobe of the liver using a 19-gauge needle guided by a curvilinear echoendoscope (GF-UE140P; Olympus, Tokyo, Japan) with color Doppler to avoid intervening vascular structures. A 0.035-inch guide wire was passed down to the ampulla and the tract was dilated using tapered-tip Teflon catheters of size 7 Fr,

Dieses Dokument wurde zum persönlichen Gebrauch heruntergeladen. Vervielfältigung nur mit Zustimmung des Verlages.

then 8.5 Fr, and finally 10 Fr. An uncovered self-expanding metal stent (SEMS; D-type Niti-S biliary stent; TaeWoong Medical, Gyeunggi-do, Korea) was inserted over the wire through the tract and down to the level of metal clip (**Fig. 4**) and deployed in a good position (**Fig. 5** and **Fig. 6**). The patient was observed for 2 weeks in the hospital and discharged without any complications.

To date there are only a few reports of EUS-guided antegrade stent insertion with few complications. Most of the procedures have been performed using balloon dilation techniques [1–3]. For this particular patient, we used tapered-tip Teflon catheters that we had made ourselves for "sequential dilatation", as previously reported [4], and marked the ampullary area using a metal clip to achieve accurate positioning of the stent. We found this alternative technique was also feasible.

Endoscopy_UCTN_Code_TTT_1AR_2AK

Competing interests: None

V. Prachayakul, P. Aswakul, S. Leelakusovong

Endoscopy Center, Siriraj Hospital, Bangkok, Thailand

References

1 *Artifon ELA, Safatle-Ribeiro V, Ferreira FCF* et al. EUS-guided antegrade transhepatic placement of a self-expandable metal stent in hepatico-jejunal anastomosis. JOP 2011; 12: 610–613

2 *Nguyen-Tang T, Binmoeller KF, Sanchez-Yague A* et al. Endoscopic ultrasound (EUS)-guided transhepatic antegrade self-expandable metal stent (SEMS) placement across malignant biliary obstruction. Endoscopy 2010; 42: 232–236

3 *Shah JN, Marson F, Weilert F* et al. Single-operator, single session EUS-guided antegrade cholangiopancreatography in failed ERCP or inaccessible papilla. Gastrointest Endosc 2012; 75: 56–64

4 *Prachayakul V, Aswakul P, Kachinthorn U.* Tapered-tip Teflon catheter: another device for sequential dilation in endoscopic ultrasound-guided hepaticogastrostomy. Endoscopy 2011; 43: E213–E214

Bibliography

DOI http://dx.doi.org/10.1055/s-0032-1309857

Endoscopy 2012; 44: E329–E330

© Georg Thieme Verlag KG

Stuttgart · New York

ISSN 0013-726X

Corresponding author

V. Prachayakul, MD

Siriraj Endoscopy Center

Siriraj Hospital – Internal medicine

Prannok Road

Bangkok 10700

Thailand

Fax: +66-2411-5013

psprvaks@gmail.com

Dieses Dokument wurde zum persönlichen Gebrauch heruntergeladen. Vervielfältigung nur mit Zustimmung des Verlages.