

Therapeutic endoscopic retrograde cholangiography and cholangioscopy (ERCC) combining a single-balloon enteroscope and an ultraslim endoscope in altered gastrointestinal anatomy

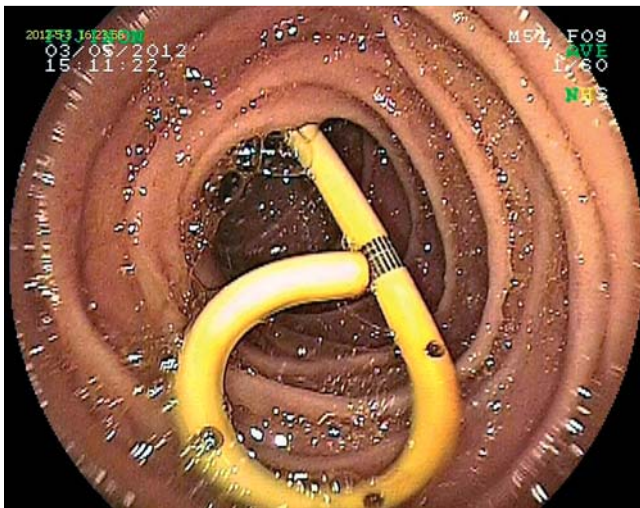


Fig. 1 Plastic stent exiting the papilla of Vater located in the afferent limb.

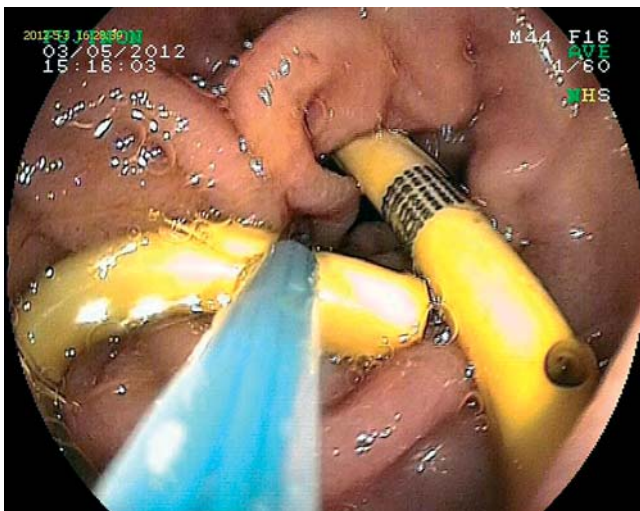


Fig. 2 The stent was grabbed with a basket and retrieved while the overtube was left in place.

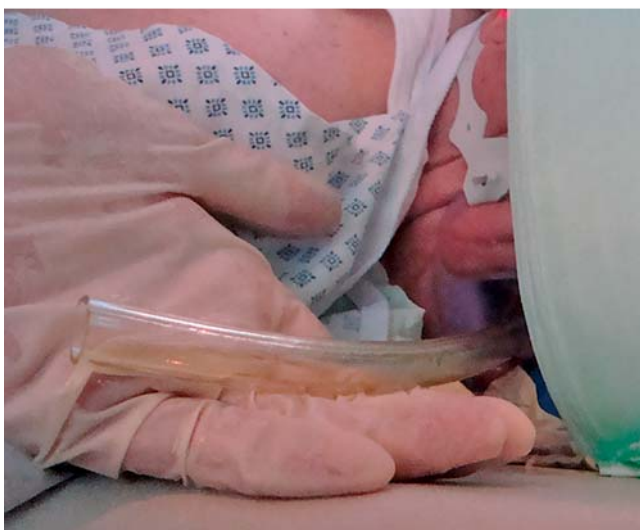

Fig. 3 An approximately 60-cm segment of the overtube was cut, leaving about 20 cm out of the patient's mouth.

An 84-year-old man with coronary artery disease, hypertension, diabetes mellitus, and previous Billroth II gastrojejunostomy presented with purulent cholangitis. He underwent endoscopic retrograde cholangiopancreatography (ERCP) with sphincterotomy and placement of a 10-cm 10-Fr double-pigtail stent. During the second ERCP it was not possible to access the afferent limb. Thus we performed single-balloon ERCP using a therapeutic enteroscope (DBE-EN-450T5, 13.5-mm outer diameter, working channel 2.8 mm; TS13140 overtube, outer diameter 13.2 mm, inner diameter 10.8 mm, working length 1350 mm, total length 1450 mm; Fujifilm, Tokyo, Japan). The stabilizing effect of the overtube facilitated the enteroscope to enter into the afferent limb and reach the papilla, from which an exiting double-pigtail stent was seen (▶ **Fig. 1**). The stent was grabbed with a basket (25-mm nitinol basket, Teflon outer coating, with 5-Fr diameter; Fujifilm, Willich, Germany) and retrieved while the overtube was left in place (▶ **Fig. 2**). Then the scope was reinserted through the overtube. The cholangiogram revealed a tortuously dilated common bile duct (CBD) and multiple filling defects, including a large stone and aerobilia. Because direct cholangioscopy using the enteroscope was not possible because of the relatively small papillary opening, a decision to use the ultrathin (transnasal) gastroscope (EVIS EXERA II video gastroscope GIF-XP-180N; 110-cm working length, 5.5-mm outer diameter, 2.0-mm working channel; Olympus, Hamburg, Germany) was taken. Because the ultrathin gastroscope had a total length of 110 cm, it could not be advanced through the longer enteroscopy overtube. Therefore, an approximately 60-cm segment of the overtube was cut, leaving about 20 cm out of the patient's mouth (▶ **Fig. 3**). Then the ultrathin scope was advanced through the overtube into the afferent limb, and the papillary orifice was again recognized and easily intubated. After intubation of the CBD, a large stone was visualized (▶ **Fig. 4**). Scope-guided cholangiography showed a dilated CBD with stones (▶ **Fig. 5**). An over-the-wire balloon (0.025 guide wire, MTW, Wesel, Germany; 12-mm, 5-Fr catheter balloon, MTW, Wesel, Germany) was used to pull the stone into the distal part of the CBD. Here it was grabbed with the basket and retrieved. After stone extraction, a full cholangioscopy was performed using the ultraslim gastroscope (▶ **Fig. 6**). ERCP in patients with surgically altered upper gastrointestinal anatomy is chal-

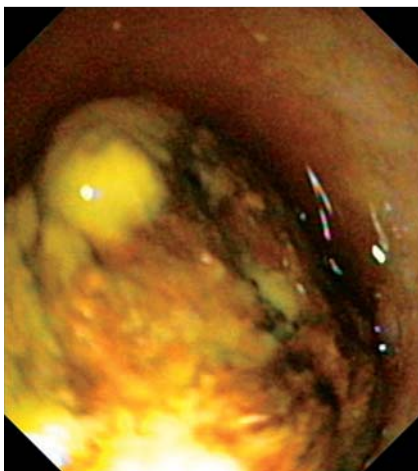


Fig. 4 Large common bile duct (CBD) stone.

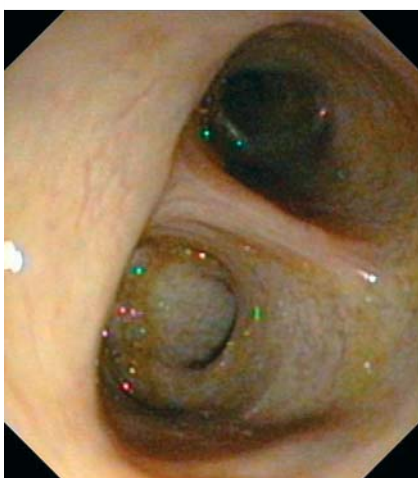

Fig. 6 Left intrahepatic bile ducts during direct cholangioscopy.

lenging [1–3]. Here we provide several additional useful tips for such a situation. First, the overtube left in situ allowed us to move both scopes in and out several times to intubate the bile duct and perform diagnostic and therapeutic interventions. Although the overtube was too long for the shorter ultraslim gastroscope, the problem was solved by cutting the tube in two at about 20 cm distal from the mouth. In essence, the overtube provided further stability during the procedure, allowing us to negotiate our way through difficult bowel turns. Secondly, the over-

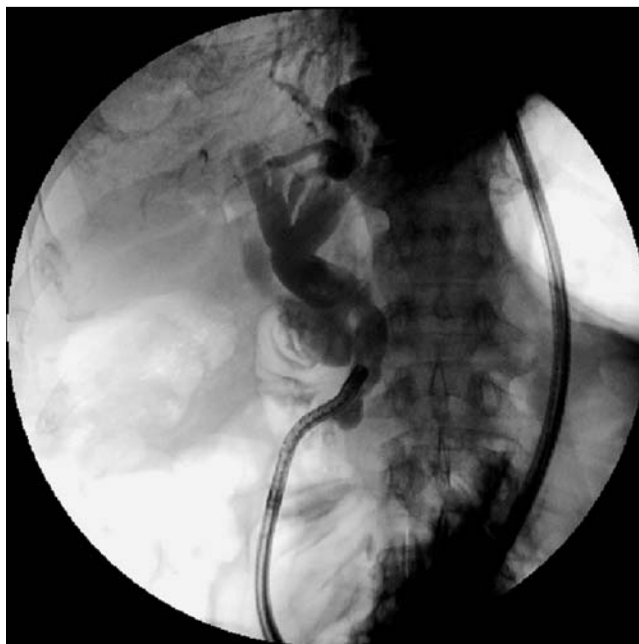

Fig. 5 Cholangiography showing a dilated common bile duct (CBD) with stones.

tube became a larger “working channel” for therapeutic ERCP, transforming the ultraslim gastroscope (i.e. “cholangioscope”) into the main instrument to navigate through the biliary tract, to visualize the inside of the bile duct, to perform cholangiography directly by injecting contrast through its working channel or through a catheter, and to perform biliary endoscopic interventions. We propose that this type of procedure be named ERCC (endoscopic retrograde cholangiography and cholangioscopy).

Endoscopy_UCTN_Code_TTT_1AR_2AH

Competing interests: None

K. Mönkemüller^{1,2}, J. Toshniwal¹, M. Zabielski¹

¹ Department of Internal Medicine, Gastroenterology and Infectious Diseases, Marienhospital Bottrop, Bottrop, Germany

² Division of Gastroenterology, Hepatology and Infectious Diseases, Otto-von-Guericke University, Magdeburg, Germany

References

- 1 Dellon ES, Kohn GP, Morgan DR, Grimm IS. Endoscopic retrograde cholangiopancreatography with single-balloon enteroscopy is feasible in patients with a prior Roux-en-Y anastomosis. *Dig Dis Sci* 2009; 4: 1798–1803
- 2 Saleem A, Baron TH, Gostout CJ et al. Endoscopic retrograde cholangiopancreatography using a single-balloon enteroscope in patients with altered Roux-en-Y anatomy. *Endoscopy* 2010; 42: 656–660
- 3 Neumann H, Fry LC, Meyer F et al. Endoscopic retrograde cholangiopancreatography using the single balloon enteroscope technique in patients with Roux-en-Y anastomosis. *Digestion* 2009; 80: 52–57

Bibliography

DOI <http://dx.doi.org/10.1055/s-0032-1310032>
Endoscopy 2012; 44: E349–E350
 © Georg Thieme Verlag KG
 Stuttgart · New York
 ISSN 0013-726X

Corresponding author

K. Mönkemüller, MD, PhD
 Department of Internal Medicine,
 Gastroenterology and Infectious Diseases
 Marienhospital Bottrop
 Josef-Albers-Straße 70
 46236 Bottrop
 Germany
 Fax: +49-2041-1061019
moenkemueller@yahoo.com