Varicella zoster gastritis in an immunocompetent adult woman

Fig. 1 Trunk appearance showing a generalized papular rash that had crusted over.

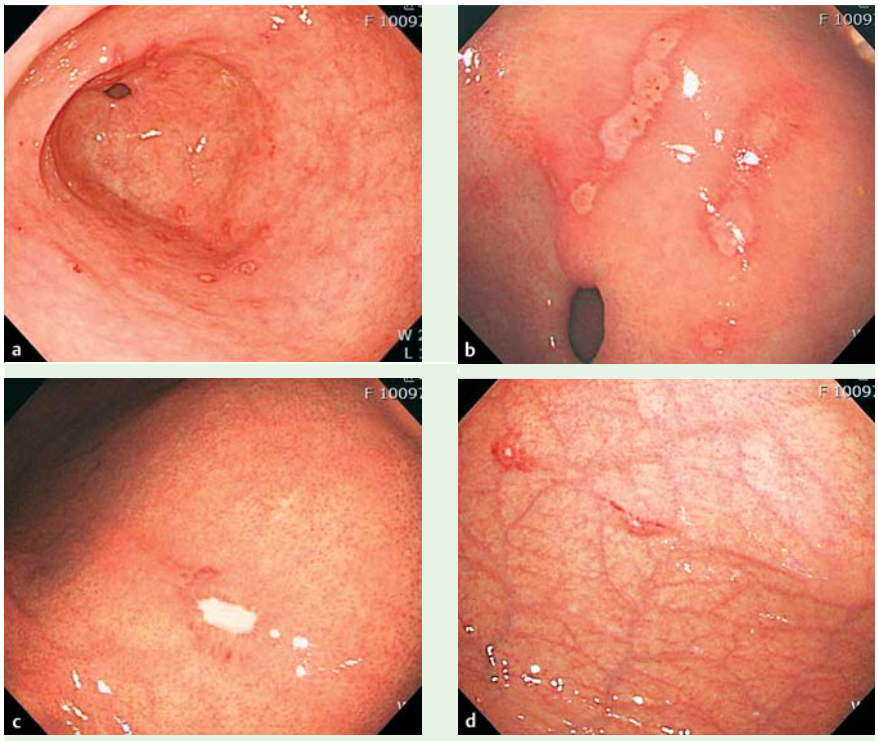

Fig. 2 Endoscopic findings showing: **a** multiple round to oval discrete erosive lesions, approximately 0.5 cm in size, with erythematous margins, involving the whole antrum; **b** multiple round to oval confluent erosive lesions, approximately 0.8 cm in size, with erythematous margins, on the lesser curvature side of the distal antrum; **c** an approximately 0.3 × 0.8-cm, ovoid, discrete erosive lesion with slightly raised erythematous margins, on the lesser curvature side of the mid-body; **d** two approximately 0.3 × 0.5-cm, ovoid, discrete erosive lesions with slightly raised erythematous margins, at the fundus.

A 42-year-old Korean woman presented to the emergency room with severe epigastric pain and anorexia lasting for 7 days. She had developed a papulovesicular skin rash that began on the trunk and then spread to the face and limbs, accompanied by 3 days of fever and myalgia, 7 days prior to presentation. The woman had been diagnosed with chickenpox and treated with intravenous acyclovir (started on the first day of skin eruption) for 7 days at an outside clinic. Her medical history was not significant for immune abnormalities, disruption of mucosal integrity, or immunosuppressant medication, including non-steroidal anti-inflammatory drugs. Her vital signs were stable and an abdominal and chest examination normal except for the generalized papular rash that had crusted over (**Fig. 1**). Laboratory tests and a simple abdominal X-ray were normal. Upper gastrointestinal endoscopy revealed multiple round to oval discrete or confluent erosive lesions, approximately 0.3 – 0.8 cm in size, with slightly raised erythematous margins, involving the whole antrum, the lesser curvature side of the mid-body, and the fundus (**Fig. 2**). A rapid urease test for *Helicobacter pylori* was negative.

The patient was treated only with an oral proton pump inhibitor, and the acyclovir was discontinued. Histopathological examination of the biopsy specimen was suggestive of non-specific acute gastritis without inclusion bodies (**Fig. 3**). However, polymerase chain reaction (PCR) for varicella zoster virus was positive, but culture was negative (**Fig. 4**). Follow-up endoscopy performed 1 week later showed marked improvement compared with the initially examined lesions, with symptom resolution. Follow-up endoscopy performed 2 months later showed normalization of the gastric mucosa.

Varicella zoster gastritis in immunocompromised patients is rare, and has never before been reported in an immunocompetent adult. This is the first reported case of PCR-proven varicella zoster gastritis in an immunocompetent adult woman [1 – 3].

Endoscopy_UCTN_Code_CCL_1AB_2AD_3AF

Competing interests: None

D. G. Kim, W. Moon, C. S. Lim

Department of Internal Medicine, Kosin University College of Medicine, Busan, Korea

This document was downloaded for personal use only. Unauthorized distribution is strictly prohibited.

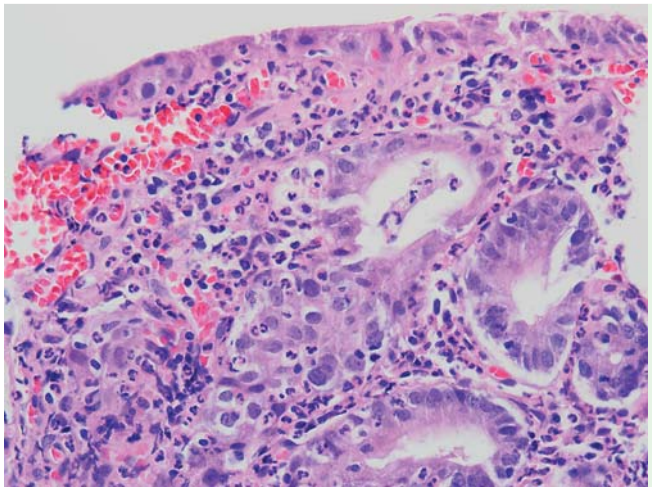

Fig. 3 Histological findings for the gastric erosive lesions, showing non-specific acute gastritis without inclusion bodies (×400).

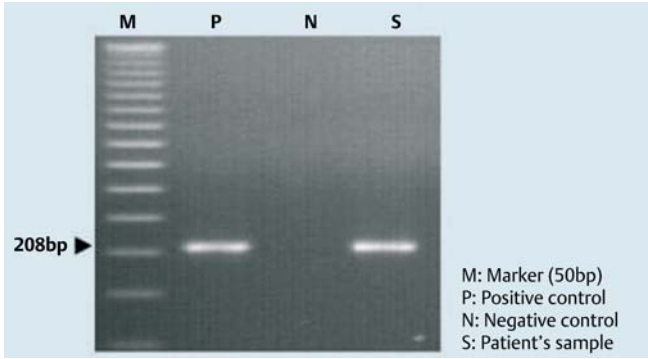

Fig. 4 Polymerase chain reaction (PCR) of the endoscopic gastric biopsy specimen, showing positivity for varicella zoster virus.

References

1 *Rivera-Vaquerizo PA, Gómez-Garrido J, Vicente-Gutiérrez M* et al. Varicella zoster gastritis 3 years after bone marrow transplantation for treatment of acute leukemia. Gastrointest Endosc 2001; 53: 809–810
2 *Scholl S, Hocke M, Hoffken K, Sayer HG*. Acute abdomen by varicella zoster virus induced gastritis after autologous peripheral blood stem cell transplantation in a patient with non-Hodgkin's lymphoma. Acta Haematol 2006; 116: 58–61
3 *Baker CJ, Gilsdorf JR, South MA, Singleton EB*. Gastritis as a complication of varicella. South Med J 1973; 66: 539–541

Bibliography

DOI http://dx.doi.org/10.1055/s-0032-1310035
Endoscopy 2012; 44: E381–E382
© Georg Thieme Verlag KG
Stuttgart · New York
ISSN 0013-726X

Corresponding author

W. Moon, MD
Department of Internal Medicine
Kosin University College of Medicine
34 Amnam-dong
Seo-gu
Busan 602-702
Korea
Fax: +82-51-9903005
moonone70@hanmail.net

This document was downloaded for personal use only. Unauthorized distribution is strictly prohibited.