

Cannulotome introduced via a percutaneous endoscopic gastrostomy (PEG) tube – new technique for release of a buried bumper

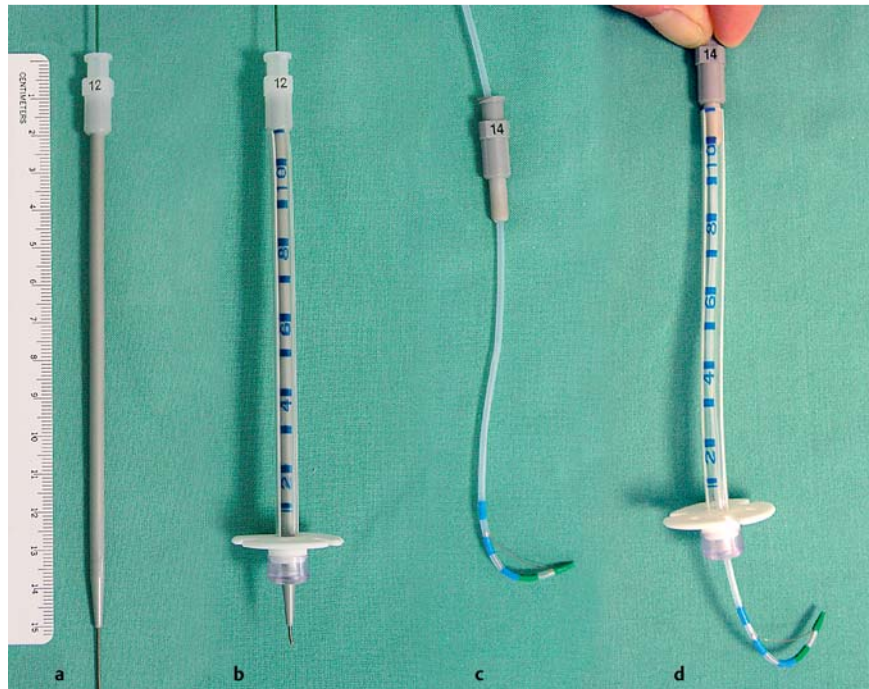


Fig. 1 Instruments required for releasing a buried percutaneous endoscopic gastrostomy (PEG) bumper using the novel technique described here. **a** Dilator with a guide wire. **b** Dilator with a guide wire introduced into the PEG cannula. **c** Cannulotome with a bushing part. **d** Cannulotome introduced through a PEG cannula.

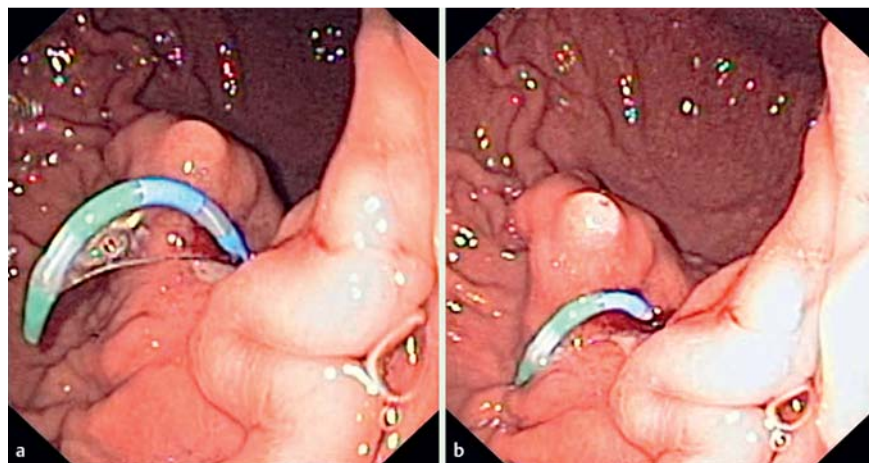


Fig. 2 Endoscopic view of a cannulotome inserted through a percutaneous endoscopic gastrostomy (PEG) tube, bending (**a**) and cutting the bulge over the buried bumper (**b**).

Buried bumper syndrome is a major complication of percutaneous endoscopic gastrostomy (PEG), in which the inner bumper of the PEG tube migrates to become embedded in the stomach wall. Several endoscopic strategies have been proposed

for releasing the bumper, based on: external traction [1], endoscopic traction [2], external pressure [3] and dissection of the overgrowing tissue using a needle-knife [4], argon plasma coagulation, or a dilation balloon [5].

Between January 2000 and March 2012, 1226 PEG procedures were carried out in our endoscopy unit. A total of 35 cases of buried bumper syndrome (2.85%) occurred in 32 patients during this period, 22 of which were suitable for endoscopic treatment. Based on this experience, we recommend the following treatment for buried bumper syndrome: insertion of a guide wire from the outside followed by dissection of the overgrowing tissue, and then pushing a PEG tube stiffened with a dilator into the stomach (▶ **Fig. 1**) and retrieving the bumper with a snare.

Dissection of the overgrowing tissue seems to be crucial and there is a risk of complication. We usually use a needle-knife and argon plasma coagulator for this part of the procedure, but in five cases we used a novel technique in which we introduce a cannulotome via a PEG tube. That is, under endoscopic control provided by the first operator, the second operator inserts a cannulotome over the wire from the outside into the stomach through a shortened PEG tube. Leakage of air between the PEG tube and the cannulotome is sealed using a modified part of a dilator, which acts like a bushing (▶ **Fig. 1**). While the cannulotome is bent and pulled slightly from the outside, the cutting wire dissects the tissue growing over the bumper (▶ **Fig. 2** and ▶ **Fig. 3**; ▶ **Video 1**). Dissection proceeds from the centre of the buried bumper and traction is directed along the long axis of the cannula (which is not always perpendicular to the stomach wall); the length of the cuts should not exceed the radius of the bumper. Incisions should be carried out at the most prominent bulges, and three to five cuts are usually sufficient. With this technique, a buried PEG bumper can be released more rapidly and more safely compared with other currently used techniques.

Endoscopy_UCTN_Code_TTT_1AO_2AK

Competing interests: None

Video 1

A cannulotome is inserted through the percutaneous endoscopic gastrostomy (PEG) tube and then bent, and the tissue growing over the embedded inner bumper is cut (two of four cuts are shown). The PEG tube stiffened with a dilator is pushed inside and the inner bumper is released.

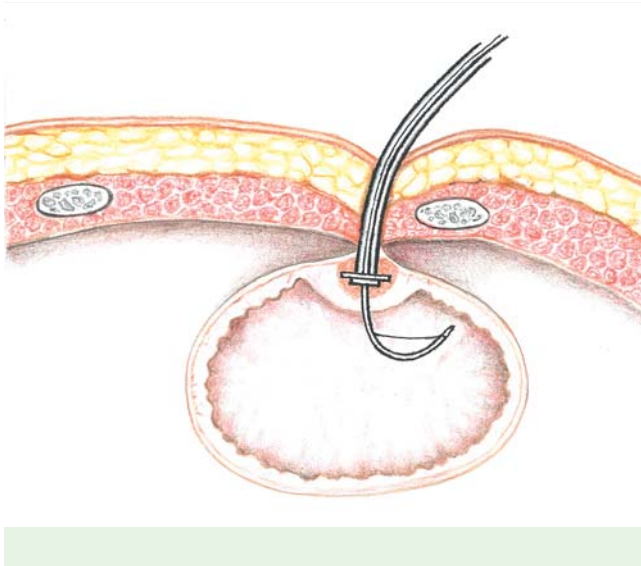


Fig. 3 Diagrammatic illustration of the transverse section of the abdomen at the level of a percutaneous endoscopic gastrostomy (PEG) with a migrated inner bumper. The cannulotome, introduced from outside via a PEG tube, is being prepared for cutting the overgrowing, bulging tissue. (Diagram courtesy of Josef Bavor, Department of Anatomy, Charles University in Prague, Faculty of Medicine Hradec Kralove, Czech Republic.)

J. Cyrany, R. Repak, T. Douda, T. Fejfar, S. Rejchrt

2nd Department of Internal Medicine, Charles University in Prague, Faculty of Medicine and University Hospital, Hradec Kralove, Czech Republic

Acknowledgment

▼ This study was supported by research grant IGA NT/13414 from the Ministry of Health (Czech Republic).

References

- 1 Lee TH, Lin JT. Clinical manifestations and management of buried bumper syndrome in patients with percutaneous endoscopic gastrostomy. *Gastrointest Endosc* 2008; 68 (Suppl. 03): 580–584
- 2 Furlano RI, Sidler M, Haack H. The push-pull T technique: an easy and safe procedure in children with the buried bumper syndrome. *Nutr Clin Pract* 2009; 23 (Suppl. 06): 655–657
- 3 Binnebosel M, Klink CD, Otto J et al. A safe and simple method for removal and replacement of a percutaneous endoscopic gastrostomy tube after 'buried bumper syndrome'. *Endoscopy* 2010; 42: E17–18
- 4 Ma MM, Semlacher EA, Fedorak RN et al. The buried gastrostomy bumper syndrome: prevention and endoscopic approaches to removal. *Gastrointest Endosc* 1995; 41 (Suppl. 05): 505–508
- 5 Strock P, Weber J. Buried bumper syndrome: endoscopic management using a balloon dilator. *Endoscopy* 2005; 37 (Suppl. 03): 279

Bibliography

DOI <http://dx.doi.org/10.1055/s-0032-1310137>
Endoscopy 2012; 44: E422–E423
 © Georg Thieme Verlag KG
 Stuttgart · New York
 ISSN 0013-726X

Corresponding author

J. Cyrany
 2nd Department of Internal Medicine
 Charles University in Prague
 Faculty of Medicine and University Hospital
 Hradec Kralove
 Czech Republic
 Fax: +420495834785
jiri.cyrany@email.cz