Endoscopic ultrasound (EUS)-guided fine needle aspiration (FNA) of the right adrenal gland

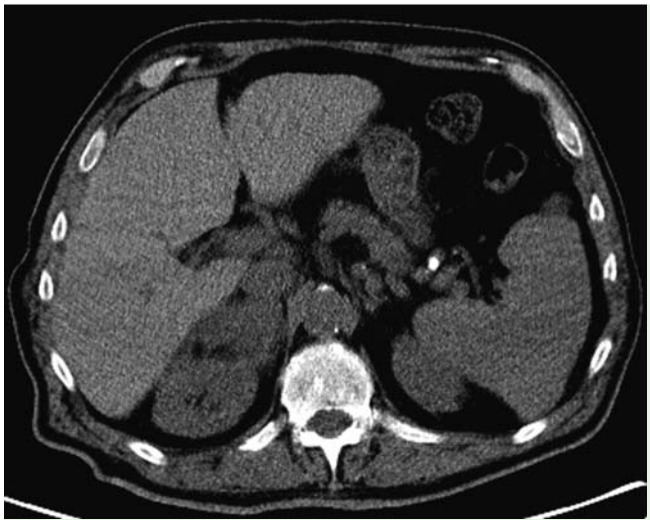

Fig. 1 Patient 1: computed tomography (CT) scan showing right adrenal mass.

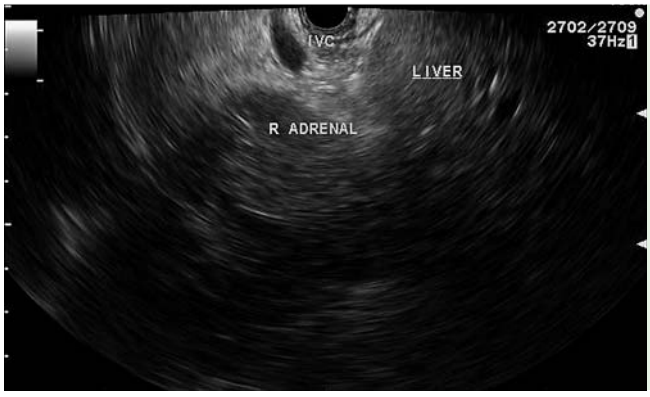

Fig. 2 Patient 1: right adrenal mass seen during endoscopic ultrasound (EUS). Due to its retrocaval location, the right adrenal gland is difficult to visualize and target for fine needle aspiration (FNA).

Fig. 3 Patient 1: post fine needle aspiration (FNA) image of the right adrenal showing no evidence of hemorrhage.

There are few reported series of endoscopic ultrasound-guided fine needle aspiration (EUS-FNA) of the right adrenal gland, probably because sampling of this gland at EUS is technically more difficult, given its retrocaval location and long endoscope position [1–4]. Here, we describe two successful cases of EUS-FNA of the right adrenal gland without any immediate or delayed complications. Prior to EUS-FNA, pheochromocytoma was ruled out in both cases.

Patient 1 was a 77-year-old man who was found to have a 3-cm right lung mass and a 6-cm mass in the right adrenal gland on computed tomography (CT)/positron emission tomography (PET) (**Fig. 1**). Bronchoscopy was nondiagnostic. Due to concern for metastases, the patient was referred for EUS-FNA. Linear echoendoscope showed a hypoechoic, centrally cystic 6-cm mass in the right adrenal gland, located between the inferior vena cava and the liver. Six FNA passes were made from the duodenal sweep with a 22-gauge needle (**Fig. 2** and **Fig. 3**). Cytopathology was consistent with papillary-type pulmonary adenocarcinoma and palliative chemotherapy is underway.

Patient 2 was a 44-year-old woman with metastatic intraductal breast carcinoma (status post mastectomy and chemotherapy) who was found to have an enlarging right adrenal gland mass on CT, which was done for suspected metastatic disease (**Fig. 4**). From the duodenal sweep station, a 3.4 cm × 2.7 cm right adrenal gland mass was visualized (**Fig. 5**). Four FNA passes were made with a 25-gauge needle. Cytopathology was consistent with the patient's previous breast carcinoma, and palliative radiation and chemotherapy are underway.

Despite being technically challenging, EUS-FNA of the right adrenal gland is feasible and safe. The low complication rate is possibly because no organ except the wall of the stomach/duodenum is traversed, and because of the ability to gain tissue diagnosis with a smaller needle (22, 25 gauge) and use of real-time Doppler guidance. Even though a case of left adrenal hemorrhage (post EUS-FNA) has been reported [5], overall, EUS-FNA of the adrenal gland is a safe procedure with no major serious complications reported to date.

Endoscopy_UCTN_Code_TTT_1AS_2AC

Competing interests: None

R. Sharma[1], S. Ou[2], A. Ullah[1], V. Kaul[1]

[1] Division of Gastroenterology, University of Rochester Medical Center, Strong Memorial Hospital, Rochester, New York, USA

[2] University of California Irvine Medical Center, Department of Internal Medicine, Irvine, California, USA

This document was downloaded for personal use only. Unauthorized distribution is strictly prohibited.

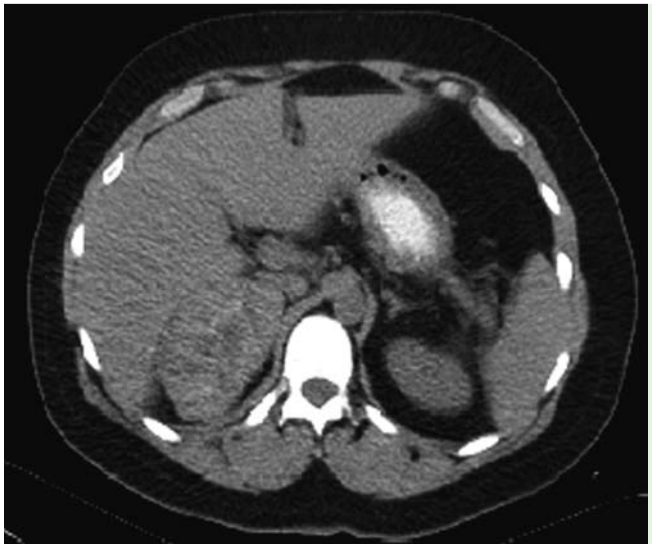

Fig. 4 Patient 2: computed tomography (CT) scan showing right adrenal gland mass.

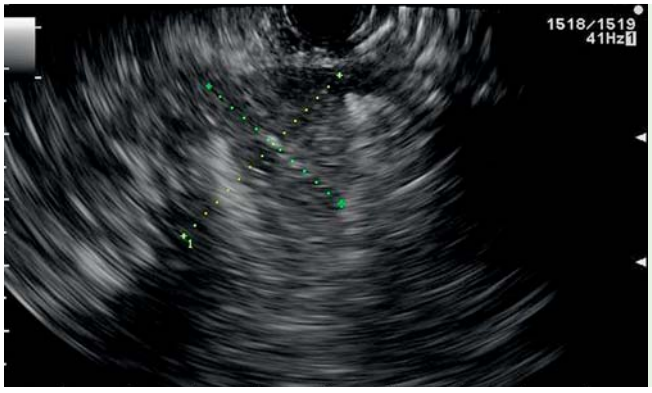

Fig. 5 Patient 2: right adrenal gland mass prior to fine needle aspiration (FNA).

References

1 *DeWitt JM*. Endoscopic ultrasound-guided fine-needle aspiration of right adrenal masses: Report of 2 cases. J Ultrasound Med 2008; 27 (Suppl. 02): 261 – 267

2 *Eloubeidi MA*, *Beydoun M*, *Jurdi N*, *Husari A*. Transduodenal EUS-guided FNA of the right adrenal gland to diagnose lung cancer where percutaneous approach was not possible. J Med Liban 2011; 59 (Suppl. 03): 173 – 175

3 *Dietrich CF*, *Wehrmann T*, *Hoffmann C* et al. Detection of the adrenal glands by endoscopic or transabdominal ultrasound. Endoscopy 1997; 29 (Suppl. 09): 859 – 864

4 *Eloubeidi MA*, *Black KR*, *Tamhane A* et al. A large single-center experience of EUS-guided FNA of the left and right adrenal glands: Diagnostic utility and impact on patient management. Gastrointest Endosc 2010; 71 (Suppl. 04): 745 – 753

5 *Haseganu LE*, *Diehl DL*. Left adrenal gland hemorrhage as a complication of EUS-FNA. Gastrointest Endosc 2009; 69 (Suppl. 06): e51 – 52

Bibliography

DOI http://dx.doi.org/10.1055/s-0032-1310145
Endoscopy 2012; 44: E385–E386

© Georg Thieme Verlag KG
Stuttgart · New York

ISSN 0013-726X

Corresponding author

R. Sharma
Division of Gastroenterology
University of Rochester Medical Center
Strong Memorial Hospital
Rochester
New York
USA
sharmadr24@yahoo.com

This document was downloaded for personal use only. Unauthorized distribution is strictly prohibited.