

A new large-diameter overtube for endoscopic submucosal dissection in the colon

The single-balloon overtube was initially developed for deeper insertion of the scope into the small bowel [1]. Ohya et al. [2] reported that use of the balloon overtube improved access to the lesion and facilitated scope manipulation in colorectal endoscopic submucosal dissection (ESD). Here we report our experience with a newly developed balloon overtube for colorectal ESD, especially in the right colon.

The novel balloon overtube designed for colonoscopy (ST-Y0001-3C1, Olympus, Tokyo, Japan) has an outer diameter of 15.6mm, inner diameter of 13.2mm, and total length 770mm. The inflated balloon is 52mm long and has a diameter of 42.4mm. A colonoscope with water-jet function is preloaded into the overtube prior to ESD (● Fig. 1). After reaching the target lesion (● Fig. 2), the overtube is inserted under fluoroscopic guidance, enabling repeated insertion and removal of the endoscope. After a circumferential mucosal incision of the lesion has been made, the endoscope is retrieved and a short, disposable, transparent hood is attached to the endoscopic tip to make the submucosal layer more visible. The hood-mounted colonoscope is reinserted through the overtube up to the lesion. Then the overtube balloon is inflated, followed by simultaneous stretching of the scope and the overtube, which prevents inadvertent slippage of the scope (● Fig. 3).

The average diameter of the specimens retrieved in our case series was 38.7mm, with an average tumor diameter of 32.4mm. The mean procedure time were 110 minutes. Both the complete resection rate and the *en bloc* resection rate was 100%. One perforation occurred during the ESD, but this was managed successfully with intravenous antibiotics (● Table 1). Although further studies are required to validate our findings, the newly developed overtube allowed us to use instruments such as a magnifying colonoscope with water-jet function and hood devices, all of which facilitated the colorectal ESD.



Fig. 1 Balloon overtube preloaded to the therapeutic colonoscope.

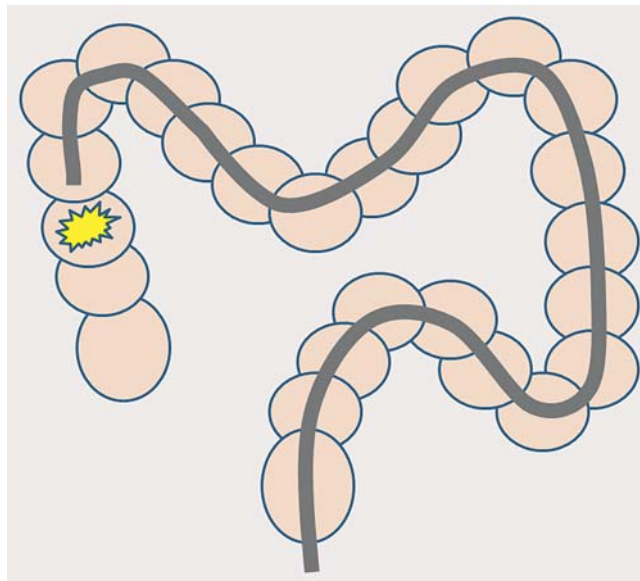


Fig. 2 Diagrammatic illustration of the initial shape of the colonoscope when inserted into the right colon.

Endoscopy_UCTN_Code_TTT_1AQ_2AD

Competing interests: None

K. Okamoto, N. Muguruma, S. Kitamura, Y. Fujino, T. Goji, H. Yano, T. Kimura, H. Miyamoto, T. Okahisa, T. Takayama

Department of Gastroenterology and Oncology, Institute of Health Biosciences, University of Tokushima Graduate School, Tokushima City, Japan

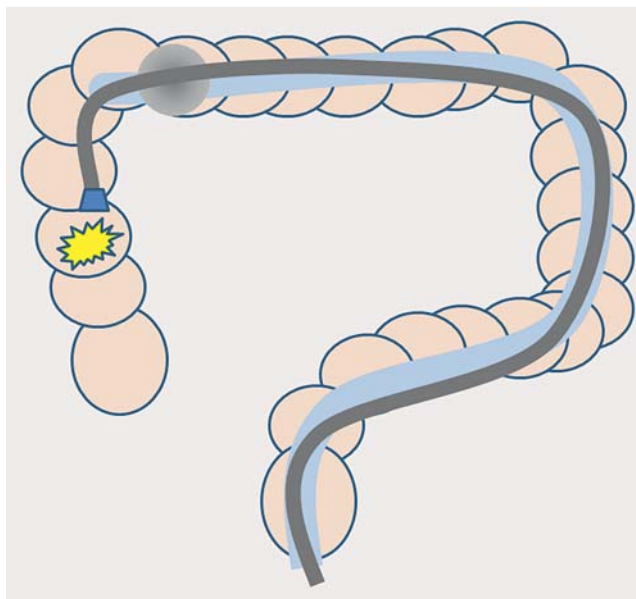


Fig. 3 Diagrammatic illustration of the straightened colon with the single balloon overtube and reinserted colonoscope attached with a hood.

References

- 1 Kawamura T, Yasuda K, Tanaka K et al. Clinical evaluation of a newly developed single-balloon enteroscope. *Gastrointest Endosc* 2008; 68: 1112–1116
- 2 Ohya T, Ohata K, Sumiyama K et al. Balloon overtube-guided colorectal endoscopic submucosal dissection. *World J Gastroenterol* 2009; 15: 6086–6090

Bibliography

DOI <http://dx.doi.org/10.1055/s-0032-1310249>
Endoscopy 2012; 44: E395–E396
 © Georg Thieme Verlag KG
 Stuttgart · New York
 ISSN 0013-726X

Corresponding author

N. MUGURUMA

Department of Gastroenterology and Oncology
 Institute of Health Biosciences
 University of Tokushima Graduate School
 3-18-15, Kuramoto-cho
 Tokushima City 770-8503
 Japan
 Fax: +81-88-6339235
muguruma.clin.med@gmail.com

Table 1 Patient characteristics and results of endoscopic submucosal dissection using an overtube. All the lesions were completely resected.

Patient	Sex	Age (years)	Location of the lesion	Specimen size (mm)	Lesion size (mm)	Length of procedure (min)	Bleeding	Perforation	Histological diagnosis
1	F	72	Ascending colon	27	25	60	–	–	Carcinoma in adenoma
2	M	62	Cecum	30	28	120	–	+	Serrated adenoma
3	F	64	Ascending colon	50	42	120	–	–	Adenoma
4	M	65	Ascending colon	40	37	100	–	–	Carcinoma in adenoma
5	F	77	Transverse colon	30	21	70	–	–	Carcinoma
6	M	63	Ascending colon	55	50	100	–	–	Serrated adenoma
7	M	75	Cecum	58	24	120	–	–	Carcinoma
8	M	76	Transverse colon	40	35	100	–	–	Carcinoma in adenoma
9	M	79	Splenic flexure	50	45	120	–	–	Carcinoma in adenoma
10	M	62	Transverse colon	40	35	100	–	–	Adenoma
11	F	85	Cecum	30	25	110	–	–	Adenoma
12	M	80	Splenic flexure	30	25	120	–	–	Adenoma
13	M	56	Ascending colon	22	20	110	–	–	Adenoma
14	F	72	Ascending colon	50	45	210	–	–	Adenoma
15	M	71	Cecum	15	13	90	–	–	Carcinoma in adenoma
16	M	76	Ascending colon	50	45	120	–	–	Carcinoma in adenoma
17	M	59	Splenic flexure	40	35	100	–	–	Carcinoma in adenoma