

# Tailgut Cyst Prolapsing through the Anus

Nina Hoejer Hansen<sup>1</sup> Niels Qvist<sup>1</sup>

<sup>1</sup> Surgical Department A, Odense University Hospital, Odense, Denmark

**Address for correspondence** Nina Hoejer Hansen, MD, Surgical Department A, Odense University Hospital, Sdr. Boulevard 29, Odense 5000, Denmark (e-mail: ninahoejerhansen@gmail.com).

Eur J Pediatr Surg 2013;23:e3–e4.

## Introduction

The tailgut cyst is a rare congenital malformation. It is a remnant of the postanal part of the hindgut, which normally regresses totally during the embryonic period. Most cases are asymptomatic and are diagnosed by incident as a presacral mass, other cases may present with different and unspecific symptoms.<sup>1–5</sup> This case presenting as a prolapse through the anus has, to our knowledge, not been reported previously.

## Case Report

A 4.5-year-old girl had a history rectal prolapse during each defecation with a spontaneous reposition. An underlying constipation was treated with macrogol. In addition, she suffered from a mild chronic juvenile arthritis, which was treated conservatively. A photo taken at home by the parents after defecation showed a prolapsing mass through the anus, however, not typical for a rectal prolapse (→Fig. 1). Rectal examination during general anesthesia revealed a presacral mass, which by traction could be everted through the anus together with the posterior rectal wall mimicking a rectal prolapse. A subsequent magnetic resonance (MR) scanning showed a cystic presacral mass compressing the rectum and urinary bladder anteriorly (→Figs. 2 and 3). Adherence to the sacrum could be demonstrated but there was no sign of spinal communication. The cyst was removed through a posterior sagittal incision. It was adherent to the muscle layer in posterior aspect of the rectum. The muscular layer was included in the excision, and a running suture closed the defect. There was no perforation of the mucosa. The postoperative course was uncomplicated. At follow-up, 1 year after operation, a normal bowel function was reported. Histopathological examination revealed a cystic process with a wall thickness of ~1 mm. The inner layer of the cyst was covered with columnar epithelia with cilia consistent with a tailgut cyst. There were no signs of mesenchymal or skin-derived cells, and there were no malignant changes.

## Discussion

A presacral cyst is in most cases a congenital cyst. The histopathologic appearance defines the type of origin and divides them into epidermoid cysts, dermoid cysts, enteric cysts, and neurenteric cysts.<sup>6</sup>

A tailgut cyst belongs to the enteric type together with cystic rectal duplication. The tailgut cyst can be multicystic and are filled with mucin. The wall has many different types of epithelia, for example, ciliated columnar cells, squamous cells, and transitional cells in combination. But no smooth muscle cells are seen in the wall. This is in contrast to the cystic rectal duplication, where three criteria must be present: continuity with the rectal wall, the wall must be built by two layers of smooth muscle cells, and finally lined by rectal mucosa, sometimes with islands of ectopic tissue, for example, from pancreas, gastric mucosa, or urothelial mucosa.

There are lesions belonging to the other groups in the presacral space which are important differential diagnosis. Sacrococcygeal teratoma is the most frequently discovered lesion in the presacral space, the pediatric population. It is a dermoid cyst and contains all three germ layers. They should, such as tailgut cysts, be removed because of the increasing risk through life for malignant transformation, even if it is asymptomatic at the time of diagnosis.

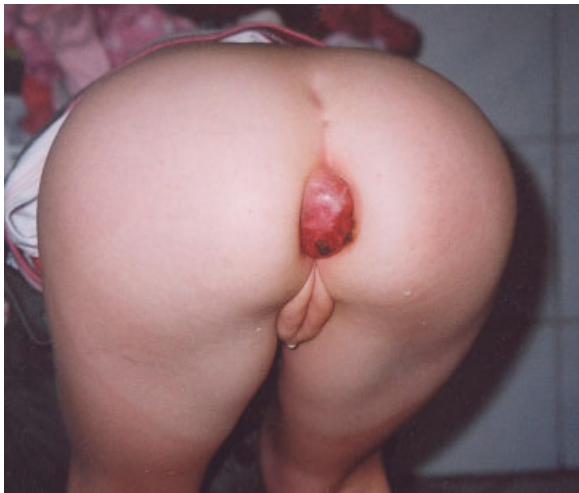Anterior sacral meningocele is another differential diagnosis. The lesion is very rare and is a cyst containing spinal fluid of the neck communicating with the subarachnoid space through a defect in the sacrum. Because of the communication with the central nervous system, meningitis can be a debut symptom besides the mass effect itself.

A prolapse through the anus is mainly caused by a prolapse of rectum or a hamartomatous polyp. Most cases occur during defecation with a spontaneous reposition. In these cases, the diagnosis has to rely on patient history because it is often difficult to identify the prolapse by conventional physical examination. In our hands homemade photos of the prolapsing condition give important information. In the present case, the prolapse was not typical for either a rectal prolapse or a

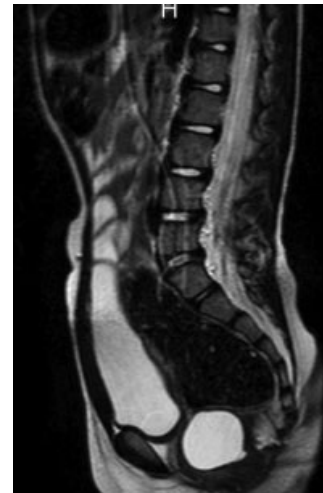
received  
November 28, 2011  
accepted after revision  
March 31, 2012  
published online  
July 7, 2012

© 2013 Georg Thieme Verlag KG  
Stuttgart · New York

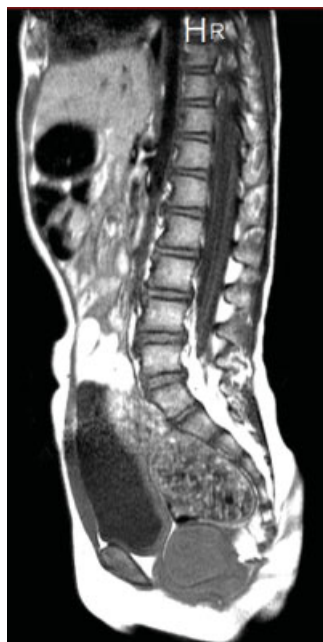DOI <http://dx.doi.org/10.1055/s-0032-1315814>.  
ISSN 0939-7248.



**Fig. 1** The tailgut cyst prolapsing through the anus.



**Fig. 3** The homogenous fluid-filled tailgut cyst.



**Fig. 2** Tailgut cyst displacing the bladder anteriorly and causing constipation.

polyp. The photo documentation led to more extensive preoperative examination including rectal examination during general anesthesia and a MR scan. The process was easily accessible through a suprasphincteric sagittal incision. Others

have reported removal transabdominal, either via conventional laparotomy or laparoscopy. The preferred access may depend on the extension of the cystic process. Close proximity to the rectal wall is common. Rectal resection will only be necessary in cases with suspicion on malignant changes, which has been described in adults, only.<sup>1,3</sup>

**Conflict of Interest**

None

**References**

- 1 Hjermstad BM, Helwig EB. Tailgut cysts. Report of 53 cases. *Am J Clin Pathol* 1988;89(2):139–147
- 2 Antao B, Lee AC, Gannon C, Arthur R, Sugarman ID. Tailgut cyst in a neonate with anal stenosis. *Eur J Pediatr Surg* 2004;14(3):212–214
- 3 Mathis KL, Dozois EJ, Grewal MS, Metzger P, Larson DW, Devine RM. Malignant risk and surgical outcomes of presacral tailgut cysts. *Br J Surg* 2010;97(4):575–579
- 4 Oh JT, Son SW, Kim MJ, Kim L, Kim H, Hwang EH. Tailgut cyst in a neonate. *J Pediatr Surg* 2000;35(12):1833–1835
- 5 Podberesky DJ, Falcone RA, Emery KH, et al. Tailgut cyst in a child. *Pediatr Radiol* 2005;35(2):194–197
- 6 Dahan H, Arrivé L, Wendum D, Docou le Pointe H, Djouhri H, Tubiana JM. Retrorectal developmental cysts in adults: clinical and radiologic-histopathologic review, differential diagnosis, and treatment. *Radiographics* 2001;21(3):575–584