

# Urachal Carcinoid—A New Presentation

Farhan Tareen<sup>1</sup> Dermot Thomas McDowell<sup>1</sup> Maureen O’Sullivan<sup>2</sup> Alan Mortell<sup>1</sup>

<sup>1</sup>Department of Paediatric Surgery, Our Lady’s Children’s Hospital, Crumlin, Dublin, Ireland

<sup>2</sup>Department of Histopathology, Our Lady’s Children’s Hospital, Crumlin, Dublin, Ireland

**Address for correspondence** Dermot Thomas McDowell, MRCS, Department of Paediatric Surgery, Our Lady’s Children’s Hospital, Crumlin, Dublin 7, Ireland (e-mail: dermcd@yahoo.com).

Eur J Pediatr Surg 2013;23:e1–e2.

## Introduction

Carcinoid tumors are APUDomas arising from the cells of the amine precursor uptake and decarboxylation system (APUD).<sup>1</sup> Pediatric carcinoid tumors are often indolent, asymptomatic tumors. They may occur in the gut as well as extra-gastrointestinal sites such as lung, bronchus, mediastinum, thymus, pancreas, and gonads.<sup>2</sup> Herein, we report a case of carcinoid tumor originating in the urachus that was managed successfully by surgery alone.

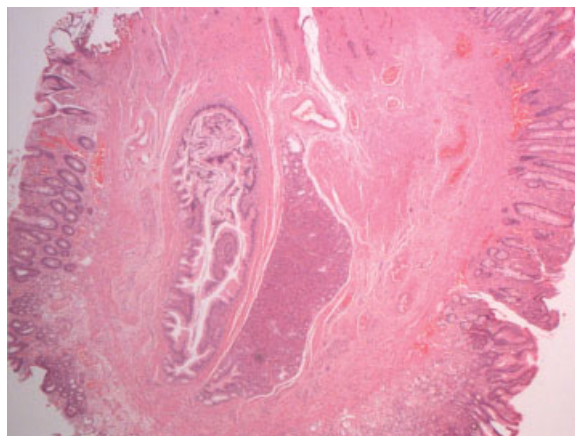
## Presentation

A 4-month-old male infant presented with a persistent umbilical discharge that had been present since birth. Clinical examination suggested an umbilical granuloma, which was excised. The histopathological assessment revealed a vitellointestinal duct remnant containing pancreatic, gastric, and small intestinal tissue (→Fig. 1). The wound healed and there were no postoperative complications. After 2 months, the patient electively underwent exploration through an infraumbilical incision to ensure complete excision of this vitellointestinal duct remnant. Surprisingly, a cord-like structure connecting the umbilicus to the superior bladder wall was found. There was no evidence of a vitellointestinal duct. Inspection of the distal small bowel up to cecum revealed no abnormality. The urachus was ligated and transected at the level of the bladder. Histopathological examination showed that this muscularized, cord-like structure was in fact urachus. Microscopic carcinoid tumor was present in the specimen (→Fig. 2). The carcinoid tumor was less than 0.5 cm in maximum dimension and did not reach the edge of the urachus. The child made an uneventful recovery and was discharged from the outpatient clinic after 6 months of follow-up.

## Discussion

Umbilical discharge in an infant is usually due to granulation tissue, retained umbilical cord elements, infection, omphalomesenteric (vitellointestinal) duct, or patent urachus.<sup>3</sup> The urachus (or median umbilical ligament) is a remnant of the allantois which extends from the bladder portion of the cloaca to the umbilicus. The innermost layer is lined by transitional epithelium in 70% of cases and by columnar epithelium in 30%.<sup>4</sup> Abnormal epithelium, including colonic, small intestinal and squamous cells may be present in urachal remnants, and many different tumors have been reported to originate from the urachus including tumors classically of childhood, such as rhabdomyosarcoma and neuroblastoma.<sup>5,6</sup>

Neuroendocrine tumors of predominantly enterochromaffin cell origin (Kulchitsky cells) appear mostly in the gastrointestinal tract (90%), and the appendix is the most commonly

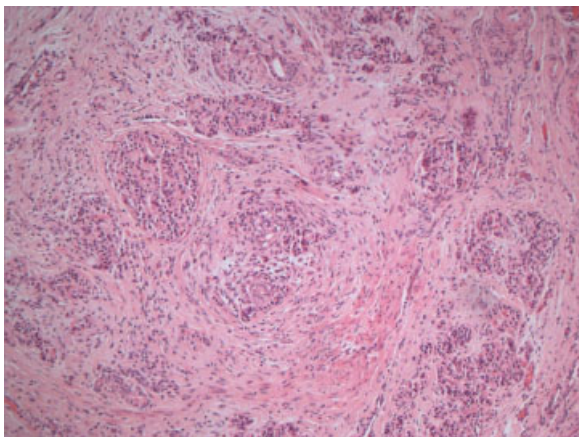


**Fig. 1** Umbilical polyp (“granuloma”) showing small intestinal mucosa covering the polyp with ectopic pancreatic parenchyma and a large ductal structure centrally located.

received  
April 2, 2012  
accepted after revision  
July 18, 2012  
published online  
October 23, 2012

© 2013 Georg Thieme Verlag KG  
Stuttgart · New York

DOI <http://dx.doi.org/10.1055/s-0032-1324797>  
ISSN 0939-7248.



**Fig. 2** Hematoxylin- and eosin-stained section showing cohesive islands of neuroendocrine cells within the urachal remnant. The cells have moderate amounts of eosinophilic cytoplasm and bland, regular-appearing nuclei. An occasional tubular profile is appreciated also.

involved location (35%).<sup>7,8</sup> Carcinoid tumors are often indolent, asymptomatic tumors. Treatment varies greatly from simple excision (as in our case) to radical surgery, with or without chemotherapy and biotherapy (somatostatin analogues and  $\alpha$ -interferon).<sup>9</sup>

There are sporadic case reports in the literature regarding dual patency of vitellointestinal duct and urachus.<sup>3</sup> In our case, the histological analysis of the excised umbilical granulation tissue was thought to be consistent with a vitellointestinal duct remnant. However, there was no evidence of this at surgery.

Although there are isolated case reports of carcinoid tumor arising in a Meckel's diverticulum, to our knowledge this is the first case of a carcinoid tumor originating from the

urachus. As this was a small tumor, a well-differentiated and an incidental finding, the prognosis is excellent for this patient.

#### Conflict of Interest

None

#### References

- 1 Van Gompel JJ, Sippel RS, Warner TF, Chen H. Gastrointestinal carcinoid tumors: factors that predict outcome. *World J Surg* 2004;28(4):387–392
- 2 Caplin ME, Buscombe JR, Hilson AJ, Jones AL, Watkinson AF, Burroughs AK. Carcinoid tumour. *Lancet* 1998;352(9130):799–805
- 3 Lizerbram EK, Mahour GH, Gilsanz V. Dual patency of the omphalomesenteric duct and urachus. *Pediatr Radiol* 1997;27(3):244–246
- 4 Schmittenebecher PP. Carcinoid tumours of the appendix in children—epidemiology, clinical aspects and procedures. *Eur J Pediatr Surg* 2001;11(6):428
- 5 Yokoyama S, Hayashida Y, Nagahama J, et al. Rhabdomyosarcoma of the urachus. A case report. *Acta Cytol* 1997;41(4, Suppl):1293–1298
- 6 Clapuyt P, Saint-Martin C, De Batselier P, Brichard B, Wese FX, Gosseye S. Urachal neuroblastoma: first case report. *Pediatr Radiol* 1999;29(5):320–321
- 7 Pelizzo G, La Riccia A, Bouvier R, Chappuis JP, Franchella A. Carcinoid tumors of the appendix in children. *Pediatr Surg Int* 2001;17(5–6):399–402
- 8 Cilley RE. Disorders of the umbilicus. In: O'Neill JA Jr, Fonkalsrud EW, Coran AG, eds. *Pediatric Surgery*. 6th ed. Philadelphia: Mosby Elsevier; 2006:1148–1149
- 9 Oberg K. Chemotherapy and biotherapy in the treatment of neuroendocrine tumours. *Ann Oncol* 2001;12(Suppl 2):S111–S114