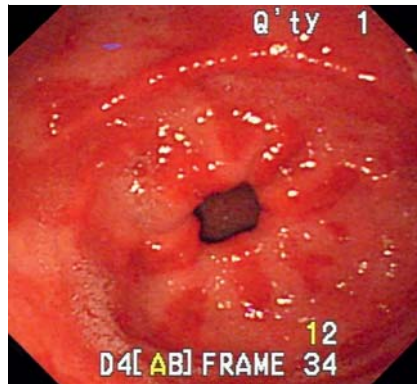


## Watermelon stomach in dengue hemorrhagic fever

A previously healthy 69-year-old man came to our emergency room with complaints of melena, abdominal pain, poor appetite, and general myalgia. Fever had occurred four days earlier, for which a nonsteroidal anti-inflammatory drug was prescribed. Physical examination revealed normal findings. Laboratory studies showed a white blood cell count of  $11.3 \times 10^9/L$ , hemoglobin 140 g/L, and thrombocytopenia with platelet count  $15 \times 10^9/L$ . The prothrombin time and activated partial thromboplastin times were 10.8 seconds (control: 11.0 seconds) and 36.6 seconds (control: 29.1 seconds), respectively. Elevated liver function results (aspartate aminotransferase 271 U/L, alanine aminotransferase 246 U/L) were also noted. Urgent endoscopy revealed linear strips of erythematous mucosa radiating from the pylorus to the antrum, mimicking gastric antral vascular ectasia (also called watermelon stomach; **Fig. 1**). Active oozing was seen, and endoscopic hemostasis with argon plasma coagulation was performed successfully (**Video 1**). Tracing back his history, the patient remembered having suffered mosquito bites before the fever occurred. Serology results were positive for dengue-specific IgG and IgM. Supportive care was given and the patient's platelet count recovered to



**Fig. 1** Endoscopy shows linear strips of erythematous mucosa radiating from the pylorus to the antrum, mimicking gastric antral vascular ectasia (also called watermelon stomach) in a patient with dengue hemorrhagic fever.

$208 \times 10^9/L$  4 days later. He was then discharged without recurrent bleeding episodes. However, he refused a follow-up endoscopic exam with biopsy to confirm the finding.

Typical endoscopic features of gastric antral vascular ectasia are usually seen in patients with liver cirrhosis, uremia, or autoimmune diseases, but have not been reported in dengue hemorrhagic fever. It is hypothesized that the vascular ectasia comes from intermittent obstruction of the submucosal vasculature due to partial prolapse of the loosely attached gastric mucosa of the antrum induced by vigorous peristalsis [1]. The experience from our patient is a reminder to physicians that, in addition to hemorrhagic gastritis and ulcers, watermelon stomach can appear in dengue fever.

### Video 1

Endoscopic hemostasis with argon plasma coagulation in watermelon stomach in a patient with dengue hemorrhagic fever.

Endoscopy\_UCTN\_Code\_CCL\_1AB\_2AD\_3AZ

**Competing interests:** None

**W.-H. Hsu<sup>1</sup>, I.-C. Wu<sup>1,2</sup>**

<sup>1</sup> Division of Gastroenterology, Department of Internal Medicine, Kaohsiung Medical University Hospital, Kaohsiung, Taiwan

<sup>2</sup> Department of Medicine, Faculty of Medicine, College of Medicine, Kaohsiung Medical University, Kaohsiung, Taiwan

### References

- 1 Jabbari M, Cherry R, Lough JO et al. Gastric antral vascular ectasia: the watermelon stomach. *Gastroenterology* 1984; 87: 1165–1170

### Bibliography

**DOI** <http://dx.doi.org/10.1055/s-0032-1325887>  
 Endoscopy 2013; 45: E35  
 © Georg Thieme Verlag KG  
 Stuttgart · New York  
 ISSN 0013-726X

### Corresponding author

**I.-C. Wu, MD, PhD**  
 Division of Gastroenterology  
 Kaohsiung Medical University Hospital  
 #100 Tz-Yu 1st Road  
 Kaohsiung City  
 807 Taiwan  
 Fax: +886-7-3135612  
 minica@kmu.edu.tw