

Duodenal *Mycobacterium genavense* infection in a patient with acquired immunodeficiency syndrome

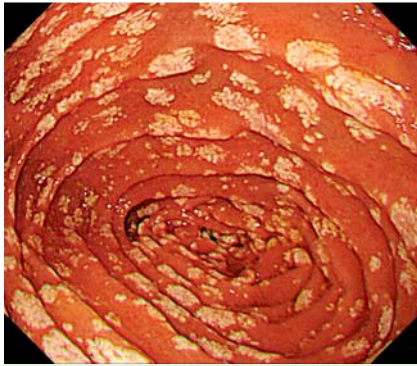


Fig. 1 Endoscopic view in the second portion of the duodenum in a 23-year-old man with known human immunodeficiency virus (HIV) infection showing widespread yellowish white nodules like xanthelasma.

Mycobacterial infection is sometimes fatal in patients with acquired immunodeficiency syndrome (AIDS). *Mycobacterium genavense*, a rare pathogen identified in 1992, causes about 10% of disseminated nontuberculous mycobacterial infections in patients with AIDS and mainly involves the small intestine [1–3]. The endoscopic findings of intestinal *M. genavense* infection are known to be nodules with a velvety appearance that is similar to that seen with *Mycobacterium avium-intracellulare* (*M. avium* complex [MAC]) [4].

A 23-year-old homosexual man with known human immunodeficiency virus (HIV) infection and a past history of hepatitis B and syphilis infections was referred to our hospital. Laboratory tests revealed his HIV RNA level to be 1.6×10^5 copies/mL and his CD4 count to be 11 cells/ μ L. He was admitted 2 months later with intermittent fever, general fatigue, and dry cough. A computed tomography (CT) scan of his chest showed a ground-glass appearance, suggestive of pulmonary infection.

A routine esophagogastroduodenoscopy performed 2 days after admission revealed widespread yellowish white nodules like xanthelasma in the second portion of the duodenum (Fig. 1). Pathological exami-

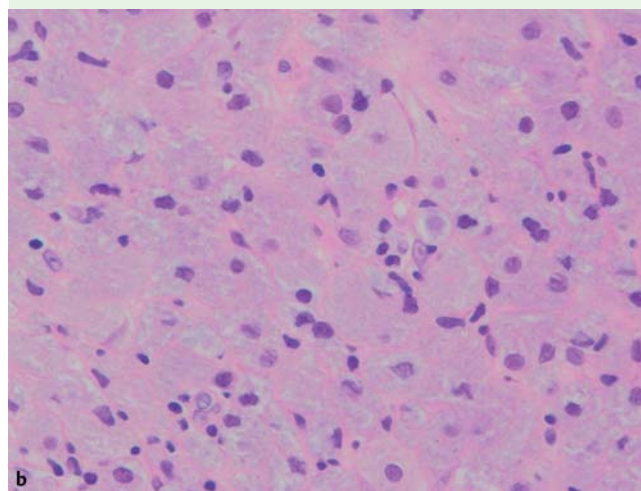
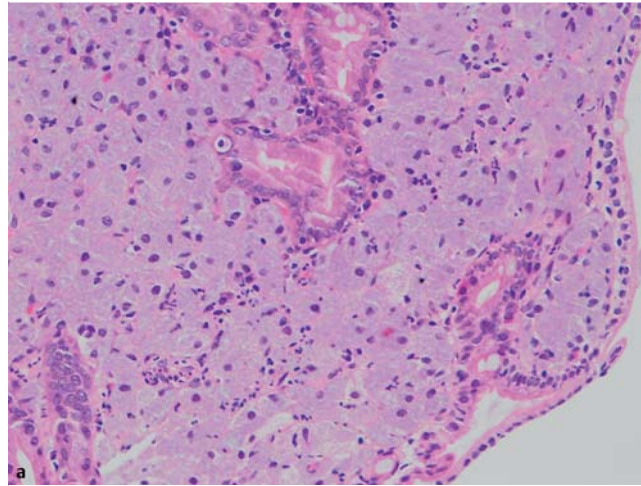


Fig. 2 Pathological appearance after hematoxylin and eosin (H&E) staining of the duodenal biopsy specimen showing an accumulation of macrophages in the lamina propria and submucosal layer: **a** in a low-power field; **b** in a high-power field.

nation of the biopsy specimen showed an accumulation of macrophages in the lamina propria and submucosal layer (Fig. 2). Ziehl–Neelsen staining demonstrated numerous acid-fast bacteria being phagocytosed by macrophages (Fig. 3). Cultures of bronchoalveolar lavage fluid and blood also detected acid-fast bacteria, which were finally identified as *M. genavense* by DNA amplification techniques. On the basis of these results, the patient was diagnosed as having disseminated *M. genavense* infection. Despite treatment with azithromycin, ethambutol, and levofloxacin, he died of respiratory failure.

Endoscopy_UCTN_Code_CCL_1AB_2AZ_3AZ

Competing interests: None

K. Abe, T. Yamamoto, T. Ishii, Y. Kuyama, I. Koga, Y. Ota

Department of Internal Medicine, Teikyo University School of Medicine, Tokyo, Japan

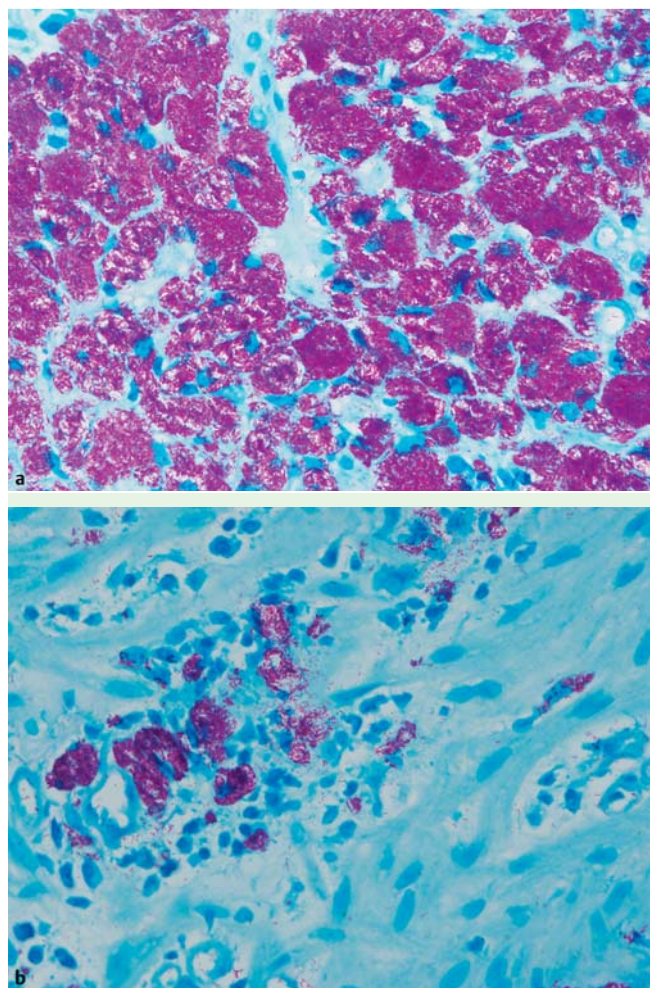


Fig. 3 Pathological appearance after Ziehl-Neelsen staining of the duodenal biopsy specimen showing numerous acid-fast bacteria being phagocytosed by the macrophages: **a** in a low-power field; **b** in a high-power field.

References

- 1 Böttger EC, Teske A, Kirschner P et al. Disseminated "Mycobacterium genavense" infection in patients with AIDS. *Lancet* 1992; 340: 76–80
- 2 Pechère M, Opravil M, Wald A et al. Clinical and epidemiologic features of infection with *Mycobacterium genavense*. Swiss HIV Cohort Study. *Arch Intern Med* 1995; 155: 400–404
- 3 Maschek H, Georgii A, Schmidt RE et al. *Mycobacterium genavense*. Autopsy findings in three patients. *Am J Clin Pathol* 1994; 101: 95–99
- 4 Koehler M, Chak A, Setrakian S et al. Endoscopic appearance of *Mycobacterium genavense*: case report and review of the literature. *Gastrointest Endosc* 1996; 44: 331–333

Bibliography

DOI <http://dx.doi.org/10.1055/s-0032-1326105>
Endoscopy 2013; 45: E27–E28
 © Georg Thieme Verlag KG
 Stuttgart · New York
 ISSN 0013-726X

Corresponding author

K. Abe, MD, PhD
 Department of Internal Medicine
 Teikyo University School of Medicine
 Tokyo 173-8605
 Japan
 Fax: +81-3-53751308
abe@med.teikyo-u.ac.jp