

Successful management using endoclips of rectal perforation during retroflexion in a patient with radiation proctitis

A 73-year-old man with a history of prostate cancer and radiation proctitis presented for a surveillance colonoscopy. Radiation proctopathy was found and was treated with argon plasma coagulation. A retroflexion was performed with some difficulty. A 2-cm linear tear was noted at the rectum junction (● Fig. 1), showing exposure of the muscularis layer of the rectum with oozing blood. Three endoclips were successfully applied to approximate the epithelial margins of the tear (● Fig. 2). The patient remained asymptomatic and hemodynamically stable after the procedure. Computed tomography (CT) scan after the procedure revealed a full-thickness posterior mid-line rectal perforation with free air extending into the retroperitoneal space, right pelvic sidewall, and surrounding the aorta and iliac vessels (● Fig. 3). There was no evidence of intraperitoneal free air. The patient was managed conservatively with nil by mouth, intravenous fluids, and intravenous antibiotics. A follow-up CT scan on day 3 revealed closure of the rectal defect posterior to the endoscopic clips and a decrease in the retroperitoneal free air (● Fig. 4). Liquid diet was started on day 3 and advanced over the next 2 days. The patient was discharged home on day 5. Endoscopists should use caution while performing retroflexion in patients with radiation proctitis. Rectal perforations limited to the retroperitoneum can be managed conservatively with endoscopic clipping.

Endoscopy_UCTN_Code_CPL_1AJ_2AH

Competing interests: None

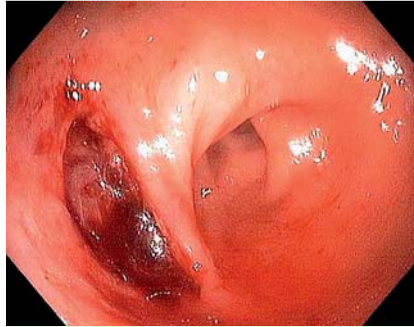


Fig. 1 A 2-cm linear tear noted at the rectosigmoid junction after colonoscope retroflexion in a 73-year-old man with a history of prostate cancer and radiation proctitis.

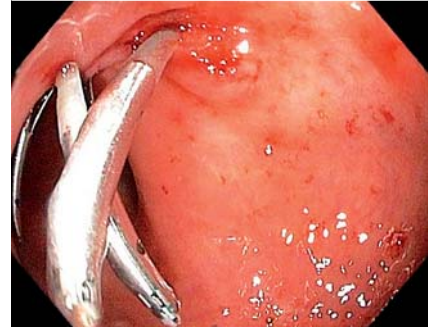


Fig. 2 Successful approximation of the rectal tear using three endoclips.

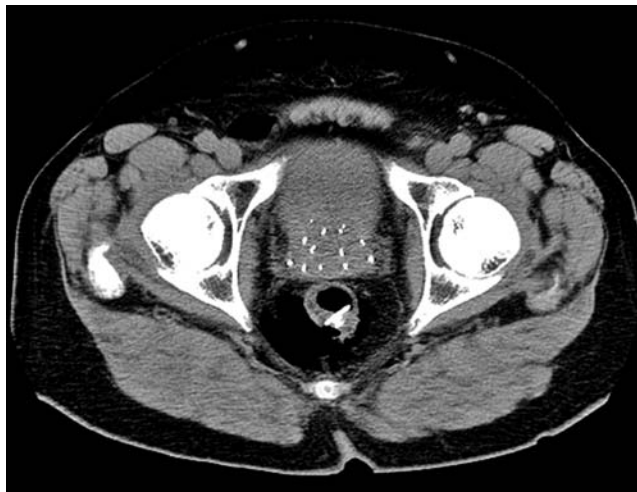


Fig. 3 CT scan on day 1 showing a full-thickness posterior rectal perforation with free air extending to the retroperitoneal space.

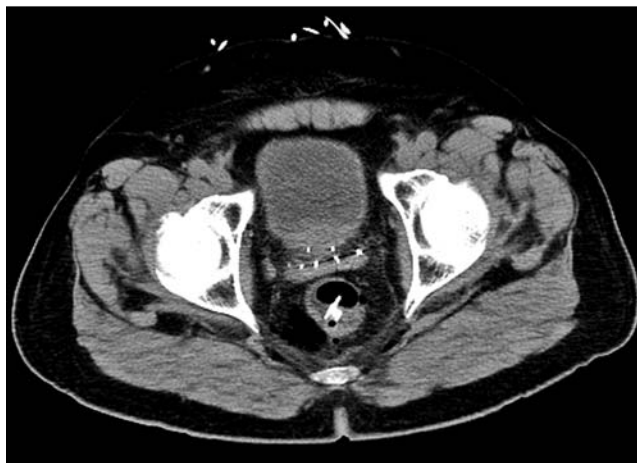

Fig. 4 CT scan on day 3 showing successful closure of the rectal defect with endoclips, with a decrease in retroperitoneal free air.

S. Singhal¹, K. Changela¹, H. Lopez-Morra¹, T. Bhatia¹, A. L. Cayton², S. Anand¹

¹ Division of Gastroenterology, Department of Internal Medicine, The Brooklyn Hospital Center, New York Presbyterian Healthcare System, Brooklyn, New York, USA

² Department of Surgery, The Brooklyn Hospital Center, New York Presbyterian Healthcare System, Brooklyn, New York, USA

Bibliography

DOI <http://dx.doi.org/10.1055/s-0032-1326114>
Endoscopy 2013; 45: E72–E73
© Georg Thieme Verlag KG
Stuttgart · New York
ISSN 0013-726X

Corresponding author

S. Singhal, MD
Division of Gastroenterology
The Brooklyn Hospital Center
121 Dekalb Ave
Brooklyn
NY 11201
USA
sdsinghal@gmail.com