

55–59

Surgical management of giant multilevel aneurysmal bone cyst of cervical spine in a 10-year-old boy: case report with review of literature

Authors Hitesh Kumar Gurjar, Avijit Sarkari, P Sarat Chandra

Institution Department of Neurosurgery, CN Centre, All India Institute of Medical Sciences, New Delhi, India

ABSTRACT

Background: Aneurysmal bone cysts are rare occurrences in the cervical spine. Surgical treatment in pediatric patients is a challenge. Complete tumor resection offers the best chance for cure.

Description: Diagnosis and surgical management of an expansile aneurysmal bone cyst of the cervical spine involving all three spinal columns in a 10-year-old boy.

Results: Surgical treatment included tumor excision and circumferential fusion, and produced no neurological or vascular sequelae. This approach minimizes the risk of recurrence and the possibility of postoperative spinal instability.

Conclusion: Spinal instability is preferably addressed with reconstruction and stabilization. Cervical aneurysmal bone cyst lesions are ideally treated with complete resection to minimize the chance of recurrence. In pediatric cases, defects created by resection should be corrected by fusion to minimize the risk of postoperative instability and growth abnormality.

The authors have no conflict of interest.
No funding was provided for this study.

INTRODUCTION

Aneurysmal bone cysts (ABC) are benign, non-neoplastic, proliferative lesions. They account for only 1%–2% of all primary bone tumors with an annual incidence of 0.14 per 105. Overall, women are more often affected than men, with a ratio of 1.04:1 [1]. Most lesions appear in children and young adults with 60% of patients younger than 20 years. The peak incidence is during the second decade of life [2]. They usually arise from long bones, but about 12%–30% of cases involve the spine [3, 4]. The lumbar spine is the most frequent site; followed by the thoracic spine, with cysts typically involving the posterior elements. Only 2% of ABCs occur in the cervical spine [5].

In 1942, Jaffe and Lichtenstein [6] coined the name “aneurysmal bone cysts” when they described a lesion that appeared to be a blood-filled cavity with a “blow out” radiographic appearance analogous to a saccular aneurysm. The expansile osteolytic capita with thin cortices, showing a bubbly appearance on radiology, gives the lesion its name of aneurysmal bone cyst [7]. More than one vertebral level is often affected. Of all ABCs, 60% occur in the pedicles, laminae, and spinous processes [2]. Most patients present symptoms of ill-defined somatic pain, stiffness, and swelling. On average, symptoms persist for 12 months before definitive diagnosis [8]. Fusion and stabilization with instrumentation have often been avoided in children due to concerns over instability following future spine growth. We report the clinical, radiological, and therapeutic aspects of one giant aneurysmal cyst of the cervical spine in a child that was operated on by anteroposterior approaches. The evolution of the case and the current treatment options are discussed.

REPORT OF A CASE

A 10-year-old boy was presented with complaints of swelling in the left lower part of his neck for 5 months and of dull, aching pain for the same duration, with radiation to the left upper limb for 1 month. The patient had progressive quadriparesis with bladder and bowel involvement. On examination, the child had a 4 x 5 cm bony, tender, immobile swelling on the left posterior triangle of the neck.

Neurological examination showed that general tone was decreased in both upper limbs and increased in both lower limbs. Power in the left upper limb was 4/5 in the shoulder and elbow, 2/5 in the wrist, and a grip of about 20% with prominent wasting of hand muscles. Power in the rest of the limbs was 4/5.

Cervical spine x-rays showed destruction of the C6 vertebra (**Fig 1**). Fine needle aspiration cytology of swelling revealed blood and hemosiderin-laden macrophages. Noncontrast computed tomography of cervical spine showed near total destruction of body and posterior elements (on left side) of C6 vertebra with partial destruction of body and posterior elements predominantly on the left side of C5 and C7 vertebrae (**Fig 2**). Magnetic resonance imaging of the cervical spine revealed a bony cystic tumor of hypo-intense signal characteristics on T1-weighted images, heterogeneous hyperintense signal on T2 and also showed heterogenous enhancement of its solid component with adjacent soft-tissue mass and cord compression (**Fig 3**). On computed tomographic angiography, the left common carotid was displaced anteriorly and the left vertebral artery was encased by a tumor without luminal narrowing of either vessel (**Fig 4**). There were no feeders found amenable for embolization.

The patient underwent two-staged surgery with intention of excision and 360° fusion. In stage 1 with the anterior approach, C5, 6, 7 corpectomy with fibular strut graft placement and anterior cervical plating from C4 to T1 were completed. The blood loss was about 800 mL. Intraoperatively, a pinkish moderately vascular firm tumor was found and gross total excision was performed (including part reaching posterior elements) and cord decompression achieved. During surgery, there was inadvertent injury to the left vertebral artery as it was encased in tumor and this artery vessel was coagulated and formally divided. The primary procedure was followed by stage 2 surgery after 3 days with

the planned posterior approach. There, laminectomy and posterior fixation was performed; C3, C4 lateral mass, and T1, T2 pedicle screws and rod fixation were accomplished (**Fig 5**). The blood loss during the posterior procedure was about 900 mL, thus total blood loss was about 1700 mL. There was no neurological deterioration in the postoperative period. The patient was uneventfully mobilized with a soft neck-collar for 4 weeks. Follow-up x-rays show good bony fusion and improvement in power in all four limbs.

Fig 1 X-ray showing lytic lesion of C6 leading to collapse of C6 body (vertebra plana).

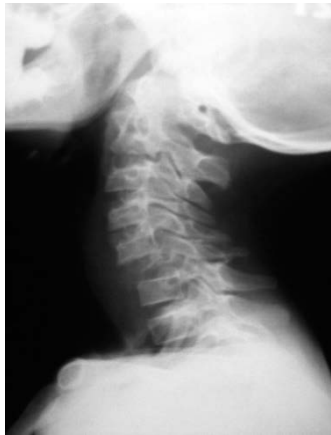

Fig 2 Noncontrast computed tomography of cervical spine showing lytic lesion involving body, pedicle, lamina, and spinous process of C5, 6, 7. Sclerotic margin around margin of lesion is clearly seen.

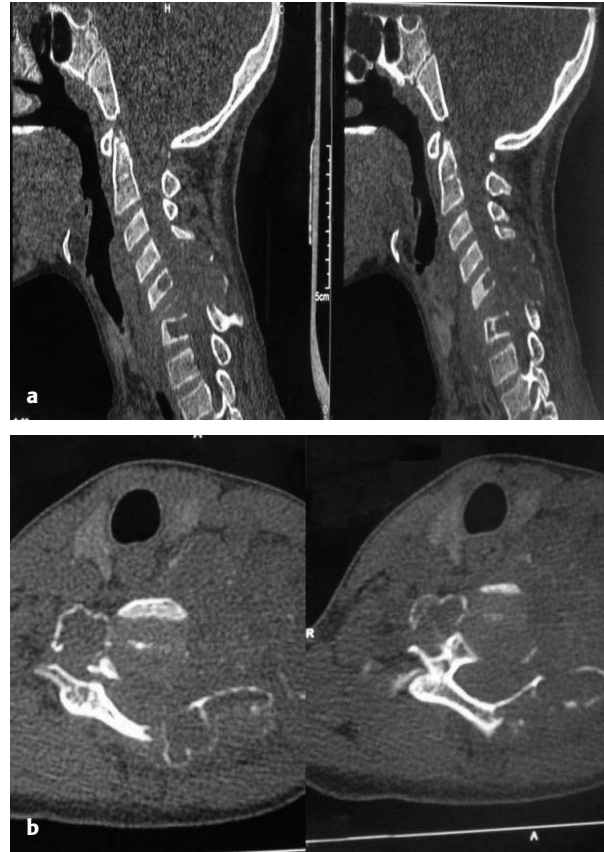

Fig 3 Contrast magnetic resonance imaging showing lesion which is heterogeneously hyperintense on T2 images and shows cystic part with heterogeneous enhancement of solid part of mass with prevertebral soft-tissue component. Compression on spinal cord is seen.

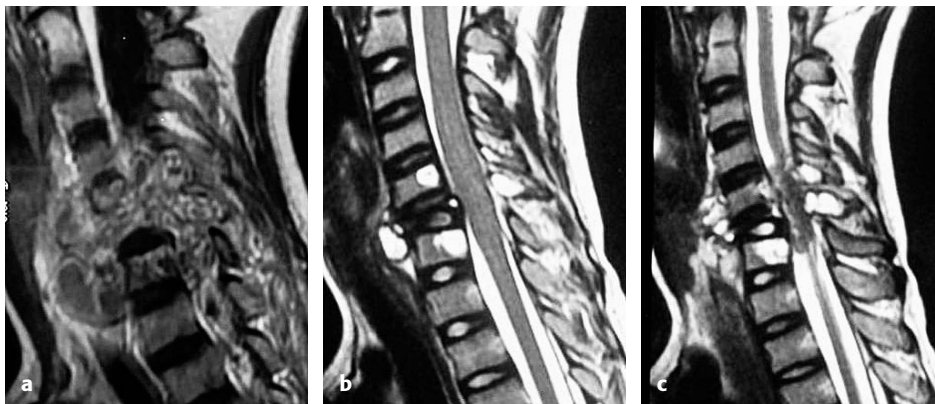


Fig 4 Computed tomographic angiography showing ventrally displaced left common carotid artery and encased vertebral artery, although there is no luminal narrowing of either vessel.

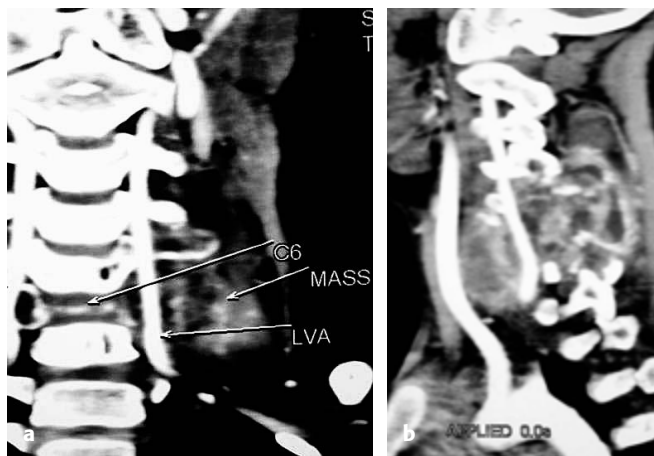
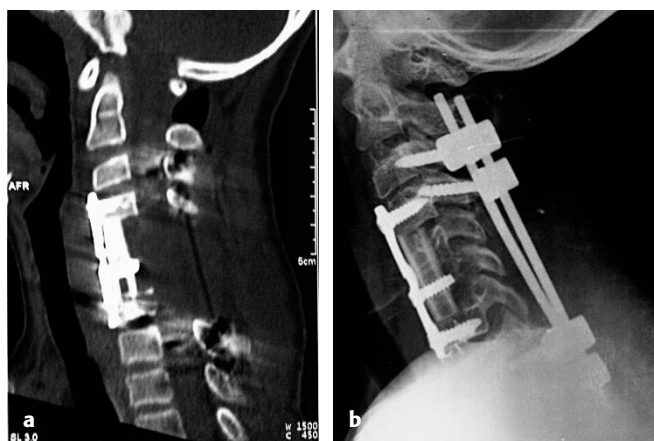


Fig 5 Postoperative x-ray showing complete tumor excision, fibulae strut graft in situ and circumferential fixation with plate and screws used anteriorly, and lateral mass and pedicle screws used posteriorly.



DISCUSSION

Aneurysmal bone cysts are expansile, non-neoplastic tumor-like lesions. While they most commonly occur around the knee, they also are reported to have relatively rare manifestations in the vertebral column [9]. According to current theory it is a reactive condition, which is aggressive in its ability to destroy and expand bone. The etiology, however, remains frustratingly uncertain. The three main hypotheses suggest that this development is the result of one of the following processes: improper repair of a traumatic subperiosteal hemorrhage; a vascular disturbance of the bone; or hemorrhage into a preexisting lesion [3]. It may occur in bone as a solitary lesion or can be found in association with other tumors, such as in proximity to giant cell tumors, chondroblastoma, chondromyxoid fibroma, and fibrous dysplasia, or in association with a malignant process [10].

Pathological fracture or partial vertebral body collapse are common findings; rarely is complete collapse seen [11]. Most of these cases are small lesions and only one segment of the column is affected [12]. Most ABCs in the spine originate in the posterior elements of the spine. Usually, the vertebral arch, pedicle, or transverse process is affected. Capanna et al [12] were able to confirm posterior involvement in each of 22 examined spinal ABCs, with asymmetrical involvement of the vertebral body in twelve cases and symmetrical involvement in two cases, and the posterior vertebral arch solely involved in eight of these cases. Preoperative CT imaging is helpful for assessing pedicle and vertebral body integrity pre-instrumentation [13]. The finding of multilocular cysts with fluid-fluid interfaces on T2-weighted images is highly suggestive of ABC [13]. Inside the tumor, there are multiple cysts, commonly with fluid levels and varying signal intensity in T1- and T2-weighted images. These signal differences are caused by different oxidation levels of blood and blood breakdown products in the cyst fluid [14].

Identification of feeding vessels can be helpful in preoperative embolization [13]. Boriani et al [3] were able to induce complete tumor regression in three of four cases by arterial tumor embolization, and for cost reasons this was preferred as a first-line therapy in that study. However, the success of these therapeutic procedures depends on the tumor's size and the degree of osseous destruction. For larger tumors, in which there are numerous supply vessels to embolize, complete devascularization of the tumor is often impossible. Three patients underwent radiation therapy alone, and 15 patients (eleven of whom had incomplete resection) underwent radiation as an adjuvant therapy. The radiation therapy was performed at doses of 30–52 Gy. There was

complete remission in all cases. No local recurrence was detected in any of these patients [3]. However for young patients radiation therapy is relatively indicated near the spine because of the risk of myelopathy developing as well as the potential for radiation-induced spinal deformity [15].

Thus, surgical resection is frequently considered the treatment of choice. Intralesional excision is followed by a 30% incidence of recurrence [16]. Selective preoperative embolization is advised to minimize intraoperative blood loss [13]. In cases of spinal cord involvement, decompression is recommended to be pursued rapidly, with the greatest possible tumor removal. Reconstruction and stabilization of the spine must be complete using bone graft with or without instrumentation [12]. Children have the highest incidence of postlaminectomy kyphosis of about 37% because of wedging of the anterior vertebral bodies caused by compression of the cartilaginous end plates [17]. These deformities progress during the adolescent growth phase, rather than spontaneously correcting; hence, instrumentation must be considered.

CONCLUSION

Surgery of benign ABCs constitutes a feasible means of reducing the compression of neural structures despite a risk of intraoperative bleeding. Complete resection of ABCs is associated with an excellent prognosis for cure. Careful preoperative instrumentation planning is important for management of post-resection spinal instability. Circumferential fusion is required in extensive tumors with involvement of both body and posterior elements.

REFERENCES

1. **Leithner A, Windhager R, Lang S, et al** (1999) Aneurysmal bone cyst: a population based epidemiologic study and literature review. *Clin Orthop Relat Res*; 363:176–179.
2. **Hay MC, Paterson D, Taylor TK** (1978) Aneurysmal bone cysts of the spine. *J Bone Joint Surg Br*; 60B(3):406–411.
3. **Boriani S, De Iure F, Campanacci L, et al** (2001) Aneurysmal bone cyst of the mobile spine: report on 41 cases. *Spine*; 26(1):27–35.
4. **Cottalorda J, Kohler R, Sales de Gauzy J, et al** (2004) Epidemiology of aneurysmal bone cyst in children: a multicenter study and literature review. *J Pediatr Orthop B*; 13(6):389–394.
5. **Mankin HJ, Hornicek FJ, Ortiz-Cruz E, et al** (2005) Aneurysmal bone cyst: a review of 150 patients. *J Clin Oncol*; 23(27):6756–6762.
6. **Jaffe H, Lichtenstein L** (1942) Solitary unicameral bone cyst with emphasis on the roentgen picture, the pathologic appearance and the pathogenesis. *Arch Surg*; 44:1004–1025.
7. **Codd PJ, Riesenburger RI, Klimo P Jr, et al** (2006) Vertebra plana due to an aneurysmal bone cyst of the lumbar spine: case report and review of the literature. *J Neurosurg*; 105 Suppl 6:490–495.
8. **Mehlman CT, Crawford AH, McMath JA** (1999) Pediatric vertebral and spinal cord tumors: a retrospective study of musculoskeletal aspects of presentation, treatment, and complications. *Orthopedics*; 22(1):49–56.
9. **Dorfman HD, Czerniak B** (1998) *Bone Tumors*. St Louis: Mosby, 855–912.
10. **Brinker MR, Whitecloud TS 3rd, James PT, et al** (1991) Vertebral aneurysmal bone cyst: a case report and review. *Orthop Rev*; 20(1):42–46.
11. **Chan MS, Wong YC, Yuen MK, et al** (2002) Spinal aneurysmal bone cyst causing acute cord compression without vertebral collapse: CT and MRI findings. *Pediatr Radiol*; 32(8):601–604.
12. **Capanna R, Albisinni U, Picci P, et al** (1985) Aneurysmal bone cyst of the spine. *J Bone Joint Surg Am*; 67(4):527–531.
13. **Liu JK, Brockmeyer DL, Dailey AT, et al** (2003) Surgical management of aneurysmal bone cysts of the spine. *Neurosurg Focus*; 15(5):E4.
14. **Caro PA, Mandell GA, Stanton RP** (1991) Aneurysmal bone cyst of the spine in children: MRI imaging at 0.5 tesla. *Pediatr Radiol*; 21(2):114–116.
15. **Mayfield JK, Riesborough EJ, Jaffe N, et al** (1981) Spinal deformity in children treated for neuroblastoma. *J Bone J Surg Am*; 63(2):183–193.
16. **Schaffer L, Kranzler LI, Siqueira EB** (1985) Aneurysmal bone cyst of the spine: a case report. *Spine*; 10(4):390–393.
17. **Bell DF, Walker JL, O'Connor G, et al** (1994) Spinal deformity after multiple-level cervical laminectomy in children. *Spine*; 19(4):406–411.