

Congenital Acinar Dysplasia: Report of a Case and Review of Literature

Mary Langenstroer, MD¹ S.J. Carlan, MD¹ Na'im Fanaian, MD² Suzanna Attia, MD³

¹Department of Obstetrics and Gynecology, Winnie Palmer Hospital, Orlando Regional Healthcare, Orlando, Florida

²Department of Pathology, Orlando Regional Healthcare, Orlando, Florida

³Department of Pediatrics, Orlando Regional Healthcare, Orlando, Florida

Address for correspondence S.J. Carlan, MD, 105 West Miller St., Orlando, FL 32806 (e-mail: stevecarlan@gmail.com).

Am J Perinatol Rep 2013;3:9–12.

Abstract

Objective Describe a case of congenital acinar dysplasia and review the literature.

Study Design Retrospective chart review and literature search.

Results Congenital acinar dysplasia is a rare malformation of growth arrest of the lower respiratory tract resulting in critical respiratory insufficiency at birth. It is a form of pulmonary hypoplasia that is characterized by diffuse maldevelopment and derangement of the acinar and alveolar architecture of the lungs, resulting in the complete absence of gas exchanging units. The growth-arrested lung tissue resembles the pseudoglandular phase of 16 weeks' gestation. The etiology is unknown. It is diagnosed by exclusion of all other causes of pulmonary hypoplasia and a summation of clinical, imaging, and histopathologic findings.

Conclusion There is no cure and clinical treatment is supportive until death of the infant. We present a case of congenital acinar dysplasia in a male infant who lived 20 days with intensive support.

Keywords

- ▶ pulmonary hypoplasia
- ▶ respiratory insufficiency
- ▶ lung maldevelopment
- ▶ congenital anomaly

Congenital acinar dysplasia (CAD) is a very rare form of primary interstitial lung disease characterized by diffuse bilateral impairment of pulmonary acini (the respiratory bronchioles, alveolar ducts, and alveoli) development.¹ Histologically the appearance of lung at term resembles the 16-week pseudoglandular phase with no alveolar spaces for gas exchange. Although there is probably a genetic component, the exact etiology is unknown. The prognosis of known cases is fatal with most children dying within days of birth from respiratory insufficiency. Along with congenital alveolar dysplasia and alveolar capillary dysplasia with misalignment of pulmonary veins, CAD belongs to a group of poorly understood diffuse developmental disorders of the lung unique to infants and together account for a very small percent of diffuse lung disease in children.²

We present an unusual case of a male infant with CAD that lived for 20 days after birth.

Case Report

A 31-year-old G1 was referred at 27.4 weeks' gestation with ultrasound evidence of intrauterine growth restriction (IUGR) and thoracic circumference consistent with 24 weeks' gestation. Other than a cardiac-to-thoracic ratio exceeding 50%, there were no other abnormalities noted on the fetal ultrasound including amniotic fluid, Doppler, or anatomy. There were no imaging, historical or clinical findings to explain the sonographic observations, and the patient was started on routine fetal surveillance and asked to follow up. She was given betamethasone injections for fetal lung maturation enhancement at 28 weeks, and serial ultrasounds continued to show delayed fetal growth with normal amniotic fluid measurements and normal umbilical and intracranial artery Doppler results.

At 37.1 weeks, the patient underwent a scheduled primary Cesarean delivery for IUGR obtaining a 2174-g small-for-

received

April 17, 2012

accepted after revision

June 25, 2012

published online

December 10, 2012

Copyright © 2013 by Thieme Medical Publishers, Inc., 333 Seventh Avenue, New York, NY 10001, USA.
Tel: +1(212) 584-4662.

DOI <http://dx.doi.org/10.1055/s-0032-1329126>.
ISSN 2157-6998.

gestational-age male infant with Apgar scores of 8 at 1 minute and 8 at 5 minutes. The umbilical artery pH was normal at 7.34. The placenta was small at 373 g. The newborn's condition deteriorated quickly with severe cardiorespiratory failure with pulmonary hypertension. He required cardiopulmonary resuscitation and was placed on extracorporeal membrane oxygenation (ECMO) at 12 hours of life. The ventilator settings prior to ECMO included a positive end-expiratory pressure of 5 cm H₂O and peak inspired pressure of 23 cm H₂O.

The working diagnosis was pulmonary hypoplasia of unknown etiology. His chest X-ray revealed small lung volumes, and an echocardiogram showed the right-sided pressures were suprasystemic with right-to-left shunt across a restrictive patent ductus arteriosus, but no congenital structural cardiac lesion. There were no alveolar or interstitial infiltrates indicative of parenchymal lung disease on chest X-ray. He developed a left frontal lobe cerebral infarct, and his condition continued to deteriorate despite resuscitation efforts. At 20 days of life, support efforts were withdrawn at parental request and the baby died.

At autopsy, there were no dysmorphic features or cardiac malformations. The right lung weighed 29.8 g and the left weighed 20.6 g (normal combined 44.6 ± 22.7 g). The lungs appeared small, firm, and hypoplastic. Histologically, the liver showed extramedullary hematopoiesis and the brain showed cystic degeneration with associated gliosis and subdural hematoma. Histological examination of the lungs showed evidence of CAD as well as acute bronchitis and bronchiolitis. The acini were irregular and dilated with diffuse growth arrest without alveolar development (►Fig. 1). The bronchi were well developed with appropriate accompanying vessels. Many bronchioles were dilated and irregularly shaped, some with abnormal stratified epithelium. Most of these bronchioles did not have accompanying arteries. The lymphatics were normally formed. The interstitium was widened and fibrotic. Movat and reticulin stains highlighted the loss of accompanying arteries with distal airways.

Discussion

The incidence of CAD is unknown and seemingly under recognized. From 1986 to 2004 only seven cases have been

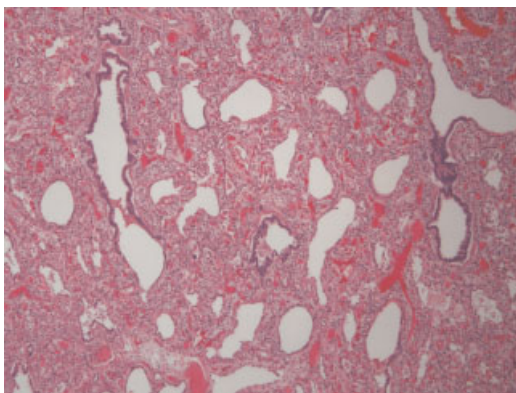


Fig. 1 Low-power view of lung parenchyma demonstrating dilated, tortuous acini without alveolar development, and thickened interstitium (hematoxylin-eosin).

reported with a definitive diagnosis of CAD, and most died within hours or days of birth from respiratory failure (►Table 1).⁷ Of those, six were female, and the longest survivor lived 2 months.^{6,7} This case is the second reported description of a male infant with CAD.

The etiology of CAD is not well understood. A genetic component seems likely, but a definite pattern is not apparent from the small number of documented cases. In 1998, a report of two sisters diagnosed with acinar dysplasia suggested an autosomal-recessive mode of inheritance for a gene critical for normal lung parenchymal development.⁵ The mother's next pregnancy ended with the birth of a son with normal lung development, thus a later article proposed that, given this familial finding along with the majority of reported cases being in female infants, there is possibility of X-linked dominant type of inheritance.⁶ Although it is a likely possibility that there is an inherited component of this condition, the proposal of X-linked dominance seems unlikely given the early fatality of this condition.

The pathology of CAD represents arrest of lung development bilaterally during the pseudoglandular stage of embryonic development. Between 8 and 16 weeks of gestation, the air-conducting bronchial tree up to the terminal bronchioli are formed. In normal development, there is organized, sequential branching of the bronchial buds, and the end of each terminal bronchiole leads to development of surrounding mesenchyme. This epithelial-mesenchymal interaction leads to respiratory units. The air-conducting bronchial tree is initially coated by cuboidal epithelium, which serves as the precursor of ciliated epithelium and secretory cells. Also, at this point, the conducting airway and "glandlike" buds become surrounded by capillaries. If the lung development arrests at this phase, the lungs will show an absence of development of the acinar components with airways distal to the bronchi composed of ciliated lined epithelium within irregularly branching bronchiolar structures. This results clinically in the inability to sustain functional gas exchange even with advanced artificial respiratory support. The other two conditions that belong to the group of diffuse developmental disorders of the infant lung, congenital alveolar dysplasia and alveolar capillary dysplasia with misalignment of pulmonary veins, result in arrest of lung development in the canalicular stage, between 18 and 24 weeks of gestation. Clinically these disorders are indistinguishable from CAD (►Table 2).

The typical antepartum clinical presentation of CAD is nonspecific. There are no outstanding, unique, consistent obstetric variables that have been recorded other than second- and third-trimester ultrasound findings. Delayed fetal size for gestational age appears to be a frequent but not universal sonographic finding. An elevated cardiothoracic ratio seen in our case probably reflects the underdeveloped acinar apparatus of the lungs, although it could also represent a skeletal rib dysplasia. Amniotic fluid volume findings have reportedly been inconsistent. Polyhydramnios, oligohydramnios, and normal fluid have all been described. There are no apparent changes in the echogenic properties of the lung that might suggest a prenatal diagnosis of CAD is possible by fetal

Table 1 Summary of findings of case reports of congenital acinar dysplasia

Author	Year	Gender	Maternal comorbidities	Ultrasound findings	Siblings	Age died
Rutledge ¹	1986	F	None	Not done	1 sibling, not discussed	7 h
Chambers ³	1991	F	Ovarian cysts	Normal	1 normal brother	Hours
Davidson ⁴	1998	F	None	Oligohydramnios	1 normal brother, 1 normal sister	Not reported
Moerman ⁵	1998	F	None	Mild growth retardation	Not reported	2 d
Moerman ⁵	1998	F	None	Mild growth retardation	1 sister died of respiratory distress on day 1 of life; 1 healthy brother	1 d
Al-Senan ⁶	2003	F	None	Mild oligohydramnios	1 sister died of respiratory distress on month 2 of life; 1 sister died of respiratory distress on day 75 of life on ventilator	2 mo
Gillespie ⁷	2004	M	None reported	Large renal mass, polyhydramnios	None	4 h
Current report	2010	M	None	Mild growth retardation, small chest circumference	None	20 d

Table 2 Comparative features of the three diffuse developmental lung disorders

	Congenital alveolar dysplasia	Alveolar capillary dysplasia	Acinar dysplasia
Clinical features	<ul style="list-style-type: none"> • Cyanosis • Respiratory difficulty • Flatness to percussion on chest exam • Chronic severe pulmonary hypertension 	<ul style="list-style-type: none"> • Persistent pulmonary hypertension • Cyanosis • Respiratory distress • Can be associated with gastrointestinal tract anomalies (Hirschsprung's, malrotation, absent gallbladder, liver arteriovenous malformation, duodenal atresia) 	<ul style="list-style-type: none"> • Persistent pulmonary hypertension • Cyanosis • Respiratory distress • Normal Apgar scores at birth • Chest X-ray with hazy lungs (nonspecific finding) • Pneumothorax found in some cases
Pathology	<ul style="list-style-type: none"> • Very large capillary bed • Alveolar epithelium resembling mature lung • Bronchial epithelium well developed • Alveolar walls very wide and composed of primitive mesenchyme without mature collagen fibers 	<ul style="list-style-type: none"> • Capillary misalignment • Medial muscular thickening of the small pulmonary arterioles • Dilated lymphatics 	<ul style="list-style-type: none"> • Almost complete absence of mature alveoli • Large increase in amount of interstitial connective tissue • Dysplastic bronchial cartilage plates
Etiology	<ul style="list-style-type: none"> • Extreme retardation in alveolar development • Arrest of canalicular stage of lung development (17–24 wk) 	<ul style="list-style-type: none"> • Arrest of canalicular stage of lung development (17–24 wk) 	<ul style="list-style-type: none"> • Arrest of pseudoglandular stage of lung development (8–16 wk) • Poor to no development of acinar structures

sonogram. This is interesting considering that the histology of type 3 congenital cystic adenomatoid malformation (CCAM) also consists of terminal bronchiole-like air spaces separated by vascular mesenchymal tissue⁸ and CCAM has identifiable fetal ultrasound features. The fact that CAD is a diffuse panparenchymal disease and CCAM segmental and without cartilage should not affect the ultrasound properties of the

tissue. Nonetheless, diagnosing CAD prior to birth is not possible at this time with imaging. There are no reports to this point on the magnetic resonance imaging appearance of the fetal chest, but this possibly may be a helpful technology.

Only two previous reports describe an associated structural fetal anomaly. In 2004 Gillespie et al⁷ described a male infant born with concurrent CAD and renal dysplasia. The fact

that the process of both lung and kidney development are normally characterized by branching morphogenesis suggests the two anomalies may share a genetic link. In 1986 Rutledge and Jensen¹ reported a concurrent right-sided aortic arch in an infant who died at 7 hours of life. No other concurrent structural organ system abnormalities have been reported. Likewise, there are no reports of shared familial features present with consistency. There are no known specific diagnostic antenatal tests and fetal karyotype is of no help. The recurrence risk is unknown, and there are no evidence-based management protocols for subsequent pregnancies.

The condition should be considered in the differential diagnosis when a pregnant woman presents with delayed fetal growth by ultrasound, possibly an amniotic fluid abnormality and possibly a slightly smaller than expected thoracic circumference, which would increase the cardiothoracic ratio. At birth the baby with CAD initially appears normal, but develops severe respiratory distress and abnormalities on chest X-ray soon after birth. All of the neonates require ventilation. These infants tend to deteriorate almost immediately after withdrawal from ventilation assistance unless they are on ECMO support.

After birth CAD is diagnosed by exclusion of all other causes of pulmonary hypoplasia and a summation of clinical, imaging, and histopathologic findings. It should be considered in infants with unexplained severe respiratory distress immediately after birth. Unfortunately, the only definitive method of diagnosing CAD is by autopsy. This condition can be missed easily without autopsy because it does not present differently clinically from congenital alveolar dysplasia and ACD.

There are no definitive cures at this point. Infants with CAD can live for a short time with supportive treatment, mechanical ventilation, and ECMO but deteriorate rapidly when support is withdrawn.

Recently, microdeletions of the FOX gene cluster at 16q24.1 were reported to cause alveolar capillary dysplasia along with other genetic disorders.⁹ Neither this test nor tests for genetic surfactant disorders¹⁰ were performed on the infant. Genetic surfactant abnormalities can also present with early respiratory failure and may be associated with absent or abnormal lamellar bodies as evaluated by electron microscopy. Electron microscopy was not performed by our laboratory, and tissue samples were not frozen. Moreover, because IUGR is frequently associated with a spectrum of genetic disorders, a comparative genetic hybridization study could have been obtained to identify an underlying genetic syndrome.

Most importantly, comprehensive genetic counseling was not given. The slides were shared with outside consultants who performed additional immunostaining of the lung epithelium for smooth muscle actin (1A4, Dako, Carpinteria, CA), CD31/endothelial cell (JC/70A, Dako), and cytokeratin 7 (OV-TL 12/30, Dako) and agreed on the diagnosis of CAD. Unfortunately, by the time the definitive diagnosis was confirmed, the patient and her partner had relocated. Consequently comprehensive genetic counseling was not given to this couple. They have been contacted and have declined. They have had a normal full-term male infant together since the CAD infant.

Our case was unusual in that it represents the longest living male known to have been born with autopsy-proven CAD. The length of this infant's life was undoubtedly a result of ECMO. If a method to identify a fetus with CAD was developed, genetic and grief counseling could be implemented, options given, and possibly operative delivery and expensive neonatal intensive care unit stays avoided.

References

- 1 Rutledge JC, Jensen P. Acinar dysplasia: a new form of pulmonary maldevelopment. *Hum Pathol* 1986;17:1290-1293
- 2 Deutsch GH, Young LR, Deterding RR, et al; Pathology Cooperative Group; ChILD Research Co-operative. Diffuse lung disease in young children: application of a novel classification scheme. *Am J Respir Crit Care Med* 2007;176:1120-1128
- 3 Chambers HM. Congenital acinar aplasia: an extreme form of pulmonary maldevelopment. *Pathology* 1991;23:69-71
- 4 Davidson LA, Batman P, Fagan DG. Congenital acinar dysplasia: a rare cause of pulmonary hypoplasia. *Histopathology* 1998;32:57-59
- 5 Moerman P, Vanhole C, Devlieger H, Fryns JP. Severe primary pulmonary hypoplasia ("acinar dysplasia") in sibs: a genetically determined mesodermal defect? *J Med Genet* 1998;35:964-965
- 6 Al-Senan KA, Kattan AK, Al-Dayel FH. Congenital acinar dysplasia. Familial cause of a fatal respiratory failure in a neonate. *Saudi Med J* 2003;24:88-90
- 7 Gillespie LM, Fenton AC, Wright C. Acinar dysplasia: a rare cause of neonatal respiratory failure. *Acta Paediatr* 2004;93:712-713
- 8 Stocker JT, Madewell JE, Drake RM. Congenital cystic adenomatoid malformation of the lung. Classification and morphologic spectrum. *Hum Pathol* 1977;8:155-171
- 9 Shaw-Smith C. Genetic factors in esophageal atresia, tracheoesophageal fistula and the VACTERL association: roles for FOXF1 and the 16q24.1 FOX transcription factor gene cluster, and review of the literature. *Eur J Med Genet* 2010;53:6-13
- 10 Dishop MK. Paediatric interstitial lung disease: classification and definitions. *Paediatr Respir Rev* 2011;12:230-237