

MR-Guided HIFU Treatment of Symptomatic Uterine Fibroids Using Novel Feedback-Regulated Volumetric Ablation: Effectiveness and Clinical Practice

MR-gesteuerte HIFU-Behandlung symptomatischer Uterusmyome mit neuartiger „Feedback“-regulierter volumetrischer Ablation: Effektivität und klinische Praxis

Authors

H. Ruhnke¹, T. Eckey², M. K. Bohlmann³, M. P. Beldoch¹, A. Neumann¹, A. Agic³, J. Hägele¹, K. Diedrich³, J. Barkhausen¹, P. Hunold¹

Affiliations

¹ Clinic for Radiology and Nuclear Medicine, University Hospital Schleswig-Holstein, Campus Lübeck, Lübeck/Germany
² Institute for Neuroradiology, University Hospital Schleswig-Holstein, Campus Lübeck, Lübeck/Germany
³ Department of Gynecology and Obstetrics, University Hospital Schleswig-Holstein, Campus Lübeck, Lübeck/Germany

Key words

- uterus
- ablation procedures
- interventional MR
- leiomyoma
- technical aspects

eingereicht 6.8.2012
akzeptiert 14.2.2013

Bibliography

DOI <http://dx.doi.org/10.1055/s-0033-1335289>
 Published online: 24.7.2013
 Fortschr Röntgenstr 2013; 185: 983–991 © Georg Thieme Verlag KG Stuttgart · New York · ISSN 1438-9029

Correspondence

Priv.-Doz. Dr. Peter Hunold
 Clinic for Radiology and Nuclear Medicine, University Hospital Schleswig-Holstein, Campus Lübeck
 Ratzeburger Allee 160
 23562 Lübeck
 Tel.: ++49/4 51/5 00 65 52
 Fax: ++49/4 51/5 00 64 97
 Peter.Hunold@uk-sh.de

Abstract



Purpose: To evaluate a novel feedback-regulated volumetric sonication method in MR-guided HIFU treatment of symptomatic uterine fibroids.

Materials and Methods: 27 fibroids with an average volume of 124.9 ± 139.8 cc in 18 women with symptomatic uterine fibroids were ablated using the new HIFU system Sonalleve (1.5 T MR system Achieva, Philips). 21 myomas in 13 women were reevaluated 6 months later. Standard (treatment) cells (TC) and feedback-regulated (feedback) cells (FC) with a diameter of 4, 8, 12, and 16 mm were used and compared concerning sonication success, diameter of induced necrosis, and maximum achieved temperature. The non-perfused volume ratio (NPV related to myoma volume) was quantified. The fibroid volume was measured before, 1 month, and 6 months after therapy. Symptoms were quantified using a specific questionnaire (UFS-QoL).

Results: In total, 205 TC and 227 FC were applied. The NPV ratio was $23 \pm 15\%$ (2–55). The TC were slightly smaller than intended ($-3.9 \pm 52\%$; range, $-100-81$), while the FC were $20.1 \pm 25.3\%$ bigger ($p=0.02$). Feedback mechanism is less diversifying in diameter ($p<0.001$). Overall, the FC correlate well with the planned treatment diameter ($r=0.79$), other than the TC ($r=0.38$). Six months after therapy, the fibroid volume was reduced by $45 \pm 21\%$ (5–100) ($p=0.001$). The symptoms decreased significantly ($p=0.001$). No serious adverse events were recorded.

Conclusion: Use of volumetric sonication leads to homogenous heating and sufficient necrosis. It is a safe and effective therapy for treating symptomatic uterine fibroids. Successful sonication of feedback cells leads to more

contiguous necrosis in diameter and a less diversifying temperature.

Key Points:

- ▶ MR-guided HIFU ablation of symptomatic uterine fibroids is a valuable treatment option.
- ▶ By non-invasive HIFU fibroid volumes can be reduced and symptoms improved.
- ▶ The novel feedback-regulated treatment cells offer advantages over standard treatment cells.

Citation Format:

- ▶ Ruhnke H, Eckey T, Bohlmann M K et al. MR-Guided HIFU Treatment of Symptomatic Uterine Fibroids Using Novel Feedback-Regulated Volumetric Ablation: Effectiveness and Clinical Practice. Fortschr Röntgenstr 2013; 185: 983–991

Zusammenfassung



Ziel: Evaluation einer neuartigen, volumetrischen Sonifikationsmethode mittels Feedback-Regulation in der MR-gesteuerten HIFU-Therapie symptomatischer Uterusmyome.

Material und Methoden: 27 symptomatische Uterusmyome mit einer Größe von $124,9 \pm 139,8$ ml bei 18 Patientinnen wurden mit dem neuen HIFU-System Sonalleve (1,5 T MRT Achieva, Philips) behandelt, 21 Myome von 13 Pat. wurden nach 6 Monaten nachuntersucht. Bei der Therapie wurden Standard-Therapiezellen (TC) und Feedback-kontrollierte Therapiezellen (FC) mit den Durchmessern 4, 8, 12 und 16 mm benutzt und hinsichtlich Erfolgsrate, Durchmesser der induzierten Nekrose und Temperaturentwicklung verglichen. Die Ausdehnung der induzierten Nekrose (NPV) wurde bestimmt. Die Myomvolumina wurden vor, 1 und 6 Monate nach Therapie ausgemessen und die

Symptomatik mittels eines spezifischen Fragebogens (UFS-QoL) bewertet.

Ergebnisse: Es wurden 205 TC durchgeführt und 227 FC. Dabei wurde ein NPV-Anteil der Myome von $23 \pm 15\%$ (2–55) induziert. TC sind im Durchmesser $3,9 \pm 52\%$ (–100–81) kleiner als geplant, FC dagegen $20,1 \pm 25,3\%$ (–100–70) größer ($p=0,02$). Die Größenvarianz der Nekrosen mit Feedback-Mechanismus ist geringer ($p < 0,001$), FC zeigen insgesamt eine gute Korrelation zum geplanten Zelldurchmesser ($r=0,79$), anders als TC ($r=0,38$). Nach 6 Monaten war das Myomvolumen um $45 \pm 21\%$ (5–100) reduziert ($p=0,001$). Die Symptomatik konnte signifikant reduziert werden ($p=0,001$). Es traten in der Nachsorge keinerlei unerwünschte Nebenwirkungen auf.

Schlussfolgerung: Die Anwendung der volumetrischen Sonifikation mittels Feedback-regulierter Therapiezellen führt zu kontrollierter Erwärmung und suffizienter Nekrotisierung und stellt damit eine sichere und effektive Therapiemethode dar. Dies bestätigt die MR-gesteuerte HIFU als nicht invasive und attraktives Verfahren bei symptomatischen Uterusmyomen.

Introduction

Due to their high prevalence rate, uterine fibroids are a clinically relevant problem: Up to 25% of women of reproductive age have myomas [1] and one-third of those patients are symptomatic. The established treatment options include conservative medication-based treatment, surgical treatment, and the minimally invasive uterine artery embolization (UAE) procedure [2–4]. High-intensity focused ultrasound (HIFU) makes it possible to perform completely noninvasive thermoablation of uterine fibroids on an outpatient basis. In the past HIFU has proven to be a safe and effective treatment alternative that achieves a good success rate while preserving the neighboring tissue [5–7]. MRI guidance of HIFU ablation allows precise treatment planning and real-time monitoring of the energy transfer (“sonication”), creates temperature maps of the treated tissue, and records the amount of thermal energy applied, thus making it possible to effectively control treatment and make predictions about therapeutic success [8, 9].

The first version of the Sonalleve® HIFU module developed by Philips HealthCare (Best, The Netherlands) in connection with the 1.5 T or 3 T MRI scanners of the Achieva and Ingenia class uses a novel method for ablating larger volumes. “Volumetric sonication” replaces the previously used point-by-point ablation technique of first-generation HIFU systems in order to make it possible to treat larger areas via ultrasound with dynamic focusing (◉ Fig. 1). The objective is to treat large volumes more quickly in order to increase treatment efficiency. Moreover, the new system includes temperature feedback control which regulates the ablation time as a function of the measured temperature resulting in greater reliability of sonication success. Regulation is performed with the help of real-time temperature mapping and varies the duration of sonication until the necessary thermal dose for complete ablation of the tissue is achieved. The objective of this study was to evaluate the efficiency, tolerability, and therapy effect of the Sonalleve® HIFU system via feedback-regulated ablation for treating symptomatic uterine fibroids.

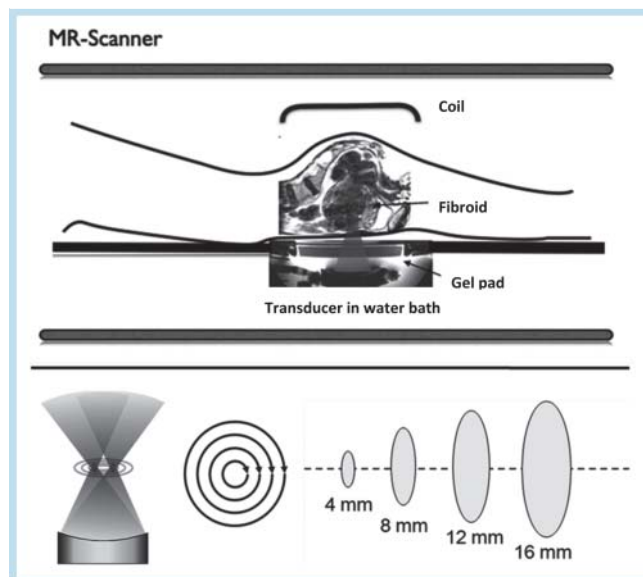


Fig. 1 Top: Schematic representation of the patient position in the MRI scanner with the HIFU transducer integrated in the examination table (Figure from [20]). With the kind permission of Springer Science+Business Media). Bottom: Principle of volumetric focusing of the ultrasound focus for inducing necrosis with a diameter of up to 16 mm by electronically steering the focus in concentric circles in an outward direction.

Materials and Methods

Patients

In the present study 27 myomas in 18 symptomatic patients were treated with HIFU (refer to ◉ Table 1 for inclusion and exclusion criteria). The study was approved by the institutional review board of the University of Lübeck. All patients were able to be followed up over a period of one month and 13 of the 18 patients (21 of the 27 myomas) were reevaluated clinically and via MRI after 6 months. The patients were 47 ± 4 years old (range: 40–53) and the BMI was 23 ± 3 kg/m² (20–26). The 27 treated myomas were located intramural ($n=17$), submucosal ($n=6$), or subserosal ($n=4$). All patients were experiencing myoma-associated symptoms to varying degrees (◉ Table 2). The size of the myomas prior to treatment was 125 ± 140 ml (6–520).

Preliminary diagnostics in the study

After gynecological examination and interdisciplinary determination of the treatment indication, a preparatory MRI examination of the patient in a prone position to simulate therapy (1.5 T Achieva in diagnostic mode) was performed to clarify whether the myomas were suitable for HIFU treatment. The myomas to be treated were evaluated via diagnostic T2-weighted MRI (turbo spin echo 3 D, TR 1000 ms, TE 130 ms, slice thickness 5.0 mm, slice gap 0.5 mm, flip angle 90°) in sagittal slice orientation and via coronal and sagittal fat-saturated T1-weighted MRI before and after contrast administration (fat-saturated spoiled gradient echo, TR 6.6 ms, TE 3.3 ms, slice thickness 2.5 mm, flip angle 10°). To detect any intestinal interposition, 3D-balanced fast-field-echo (bFFE) sequences (balanced steady-state free precession [bSSFP]) (TR 3.75 ms, TE 1.9 ms, slice thickness

Table 1 Inclusion and exclusion criteria

inclusion criteria	exclusion criteria
– known symptomatic uterine fibroid(s)	– serious systemic diseases
– age between 18 and 59 years	– existing pregnancy or desire to become pregnant
– weight < 140 kg/BMI < 35	– significant abdominal wall scarring
– premenopausal or perimenopausal	– general MRI contraindications
– symptom severity score \geq 30	– calcification of the uterine fibroid
– pap smear I or pap smear II	– intraabdominal scarring or surgical clips
– dominant myoma \geq 3 cm and \leq 12 cm	

Table 2 Symptoms of the patients (multiple symptoms possible)

symptom	absolute frequency	frequency in %
severe bleeding/hypermenorrhea	15	83
pollakiuria	11	61
pain/dysmenorrhea	7	39
feeling of tension and pressure	6	33
fluctuation of duration of period	5	28
meteorism	5	28
passing of blood clots	4	22
tiredness	4	22
nycturia	3	17
obstipation	2	11

5.0 mm, slice gap 0.5 mm, flip angle 20°) in sagittal slice orientation were also generated on the day of treatment.

Treatment

The HIFU transducer (Imasonic SA, Besançon, France) is integrated into the MR examination table and can be moved mechanically and tilted within the surrounding water bath in both a horizontal and vertical direction. A gel pad was positioned on the window of the transducer in the MR table to ensure that there was no air between the transducer and the target region, in particular between the gel pad and the skin (Fig. 1).

After thorough abdominal depilation to ensure a smooth skin surface, a peripheral indwelling venous cannula was inserted into all patients for the administration of a non-opioid analgesic (Paracetamol, Perfalgan® 1000 mg/100 ml infusion solution, Bristol-Myers Squibb) prior to treatment and for the administration of the MRI contrast agent Gadobutrol after the completion of sonication (Gadovist® 0.1 mmol/kg KG, Bayer HealthCare). In addition to intravenous pain prophylaxis, the patients received an oral non-steroidal analgesic (Ibuprofen, Ibu-ratiopharm®, 400 mg, Ratiopharm) and a mild oral sedative upon request (Diazepam-ratiopharm® drops 10 mg/ml, Ratiopharm). A urinary catheter was not used for the sake of the patients' comfort. After correct positioning of the patient over the transducer and elimination of interfering air bubbles between the abdominal skin and the gel pad via "BubbleScan" in coronal slice orientation (T1 fast field echo, TR 120 ms, TE 15 ms, slice thickness 2.5 mm, flip angle 60°), T2-weighted planning images (turbo spin echo 3D, TR 1000 ms, TE 130 ms,

slice thickness 2.5 mm, flip angle 90°) were acquired in sagittal slice orientation. During treatment, the planning sequences were repeated every ten minutes to adapt the sonication planning to interim uterine movements, e.g. due to filling of the bladder.

The individual "treatment cell locations" were planned with the help of multiplanar reconstructions of this sequence. Treatment cells with a diameter of 4, 8, 12, or 16 mm with and without the feedback mechanism could be selected. A treatment cell refers to the target tissue region heated per sonication in the targeted volume (Fig. 1). The transducer generates the energy via 256 individual elements with a slightly concave design. Phased-array technology and mechanical deflection of the entire transducer are used to control and move the ultrasound focus. The selection was made based on the myoma size and generous safety distances according to the currently valid recommendations of the FDA [10]. Under consideration of the optimum treatment cell size for the individual treatment, conventional treatment cells (TC) and feedback-regulated treatment cells (feedback cells, FC) were used with approximately the same frequency without randomization for every myoma (205 vs. 227) (Fig. 2). For better assessability, only the successfully completed ablations of the TC and FC were compared.

The ultrasound energy was selected based on the temperature development of a test sonication with 20–50 watts with the average value being 130 ± 28 watts (70–200). Visual monitoring of the sonication using real-time temperature maps via proton resonance frequency change was an important tool during treatment [11]. The visual monitoring by the operators was supported by the measurement of the introduced thermal dose and automatic stopping of the sonication by the HIFU software once the planned volume was reached. The system acquires images of a total of six different slices every three seconds. The temperature development can be tracked on screen on four different levels with color coding. Three adjacent coronal slices and one sagittal slice in the direction of the beam field as well as one previously defined slice to monitor the tissue in front of the beam focus (near field) and one behind the beam focus (far field) were imaged to visualize the heating of the treatment cell. These planes were positioned in particularly sensitive anatomical regions (Fig. 3), i.e., one at the level of the abdominal wall (risk of cavitation), and the other at the level of the front wall of the sacrum (risk of damage to the neural structures). Both the patient and operator were able to stop each sonication at any time by pressing the cancel button.

After completed treatment, the patients underwent clinical examination and were briefly monitored before being allowed to leave the hospital on the same day.

Evaluation

Treatment efficiency

To estimate the treatment efficiency, the non-perfused volume (NPV) was determined via manual segmentation and addition of the determined volumes (slice summation) in the contrast-enhanced, T1-weighted MRI images (fat-saturated spoiled gradient echo, TR 6.6 ms, TE 3.3 ms, slice thickness 2.5 mm, flip angle 10°) directly following treatment. The values were used to determine the percentage of the myoma that was no longer perfused, i.e., the NPV ratio. To evaluate all treatment cells and to compare the used TC

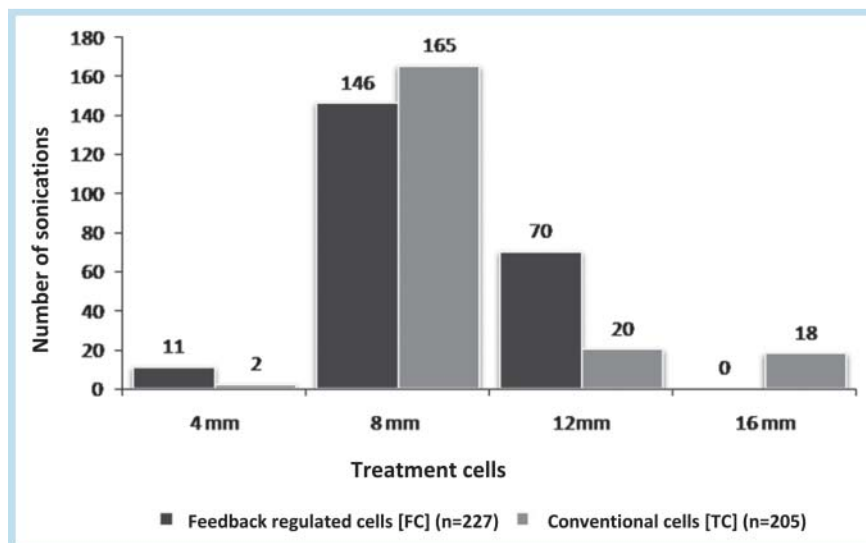


Fig. 2 Overview of the number and size of used treatment cells. Feedback-regulated treatment cells are referred to as feedback cells (FC) and treatment cells without feedback regulation are referred to as treatment cells (TC).

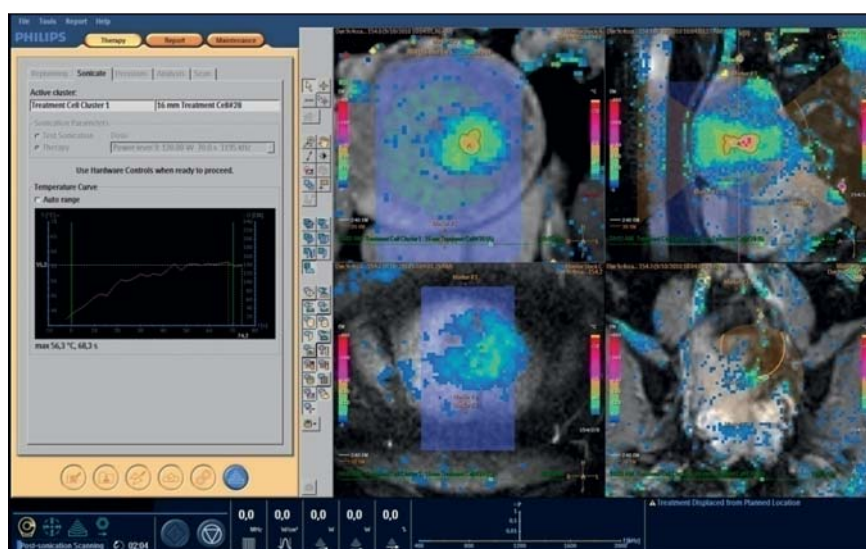


Fig. 3 Treatment monitoring via color-coded MR thermometry with visualization of the ultrasound focus in coronal and sagittal view and from the near and far field in coronal slice orientation. Simultaneous representation of the temperature development in the ultrasound focus over time (left).

and FC, the diameter of all sonications visualized per MR thermometry was determined as a measure for the volume and the deviation from the previously planned size was determined. The induced tissue necrosis was calculated and visualized according to Sapareto, i.e., a virtual exposure time at a reference temperature was calculated on the basis of the currently measured temperature as a function of time and an estimated time-temperature relationship [12]. A thermal energy of 240 equivalent minutes in relation to 43 °C was considered a lethal dose for the tissue area and represented by the monitoring software as an isodose. The area covered by this isodose was evaluated as tissue necrosis and measured after completed treatment at the HIFU planning console. The ablation success or stopping criterion was documented for every sonication. The highest temperature per sonication was recorded and compared between the TC and FC.

Tolerability

The tolerability of the treatment was determined via patient questionnaire concerning the status before, during,

and immediately after treatment. The level of pain was indicated using a 4-point scale (0 = no pain; 1 = minor pain; 2 = moderate pain; 3 = severe pain). In addition, all periinterventional incidents and treatment-based complaints during treatment and for a follow-up period of 6 months were documented. The total treatment time, i.e., the MRI examination time, the time period from the first to the last sonication, and the duration of stay in the hospital, was recorded.

Volume reduction

Treatment was followed by a follow-up MRI examination after one month and after 6 months to evaluate the clinical success. The primary treatment success in terms of volume reduction was determined using volumetry of the treated myomas via manual segmentation prior to treatment and in the follow-up examinations.

Symptom reduction

Myoma-related symptom changes were recorded using a standardized questionnaire prior to treatment and 1 month

and 6 months after treatment. The questionnaire established and used for this purpose, *UFS-QoL* (Uterine Fibroid Symptoms – Quality of Life), was developed specifically for myoma-related symptoms and evaluated for the minimally invasive treatment of symptomatic uterine fibroids and diseases with similar symptoms, such as uterine adenomyosis [13, 14]. The symptom severity score (SSS), which specifies the severity of symptoms on a scale of 0 to 100 with high values indicating severe symptoms, was calculated with the help of the questionnaire. A significant treatment effect is assumed for a point reduction of ≥ 10 points.

Statistics

Statistical data were specified as the mean \pm standard deviation and the range in parentheses. Significance tests were performed according to normal distribution testing via T-test for independent and paired samples and Mann-Whitney-U and Wilcoxon testing for not normally distributed variables with a significance level of $p < 0.05$. The variance was assessed using the Levene test. Spearman's correlation coefficient was used to determine the correlation.

Results

No serious incidents occurred during or after treatment. Treatment was stopped prior to reaching the planned sonication volume in 3 of 18 cases due to pain and a further termination occurred as the result of hardware problems. All patients were able to leave the hospital on the same day and resume normal activities the next day.

A total of 432 sonications were performed in all treatments. The average treatment time (period in which the patient was in the MR scanner) was 244 ± 45 min (150–310), and the time from the first to the last sonication was 140 ± 37 min (92–220). The entire hospital stay for treatment (period from entering to leaving the hospital) was 380 ± 71 min. (240–525).

Treatment efficiency

The primary NPV ratio achieved during treatment was $23 \pm 15\%$ (2–55). The largest primarily no longer perfused volume was 128 ml in a 234 ml myoma. Dividing the study population into 2 groups according to chronological order of treatment as an indicator for the influence of the experience of the operator on treatment success showed that the NPV ratio increased significantly from $14 \pm 10\%$ (2–30) to $30 \pm 15\%$ (3–55) ($p = 0.007$).

The average maximum temperature of all sonications was 63.1 ± 8.4 °C (40–92). 89% reached a maximum temperature of at least 56 °C, while only 1.6% reached an excessive temperature of more than 80 °C. **Fig. 4** provides an overview of the temperature development of all performed sonications.

A large number of feedback sonications could not be completed according to protocol in the manner defined by the system for the particular treatment cell. Only 28.6% (65 of 227) were completed properly according to protocol. 113/227 sonications (50%) were stopped due to error messages or warnings (in particular failure to reach the target thermal dose). However, sufficient ablation could be assumed in most cases on the basis of the temperature development observed by the operator so that the reason for the error message was often unclear. The percentage of terminations increased with the size of the treatment cell. Using the conventional method (TC), 83.4% (171 of 205) of the sonications were completed as planned. A more detailed overview of the consistency and stopping criteria of the TC and FC is provided in **Table 3**.

Compared to the temperature development, using the FC results in significantly higher maximum temperatures than in the case of the TC: 66.7 ± 4.6 °C (57–87) vs. 63.1 ± 7.8 °C (48–127), $p = 0.000001$. The temperature variance is lower when using the FC ($p = 0.01$).

The following applies for the correlation of the actually resulting NPV to the size of the selected treatment cell: The actual NPV of the TC is $3.9 \pm 52\%$ (-100–81) smaller than planned (according to Sapareto) while that of the FC is $20.1 \pm 25.3\%$ (-100–70) greater than expected ($p = 0.02$). The variance of the feedback mechanism is also lower here, and the average deviations from the planned treatment cell

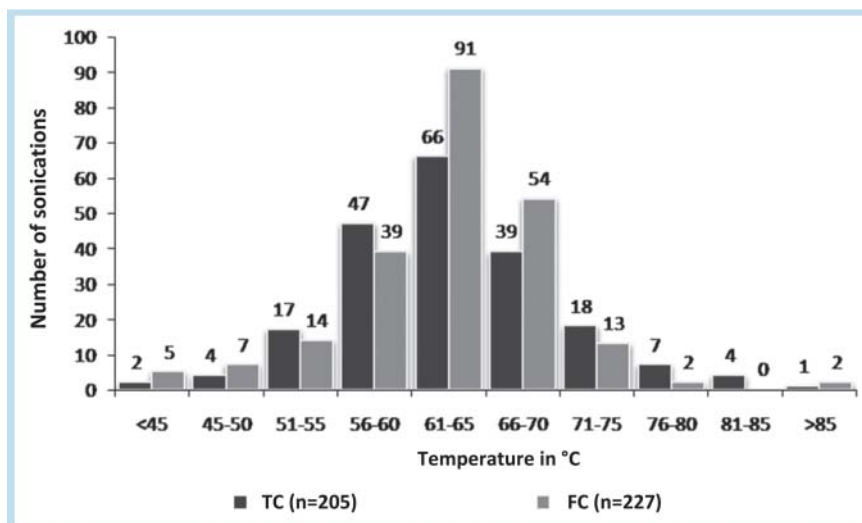


Fig. 4 Measured maximum temperature of the unregulated (TC) and feedback-regulated (FC) sonications.

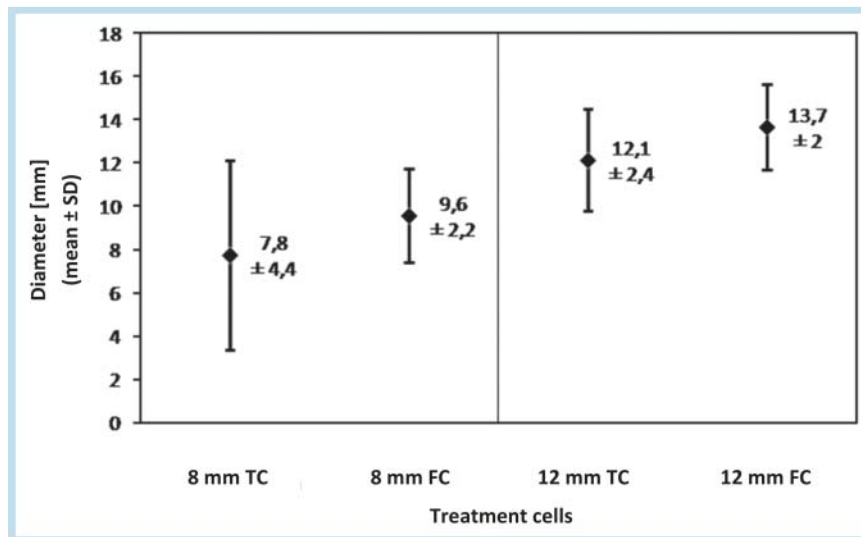


Fig. 5 Overview of the diameter of the induced non-perfused volume (NPV) for treatment cells and feedback cells with a diameter of 8 mm or 12 mm.

Table 3 Overview of termination criteria for treatment cells

sonication	absolute treatment cells (in %)	absolute feedback cells (in %)
completed	171 (83.4)	65 (28.6)
premature termination (total)	34 (16.6)	162 (71.4)
by operator	3 (1.5)	26 (11.4)
by patient	7 (3.4)	3 (1.2)
software-induced	2 (1)	113 (50)
by safety system	5 (2.4)	1 (0.5)
other	17 (8.3)	19 (8.3)
total	205	227

size are smaller ($p=0.0000002$). On the whole, the FC show a good correlation to the planned cell diameter ($r=0.79$) in contrast to the TC ($r=0.38$). **Fig. 5** shows the average diameter of the induced termination of perfusion for cells with a diameter of 8 mm or 12 mm.

In total, slightly more power was used in the case of the feedback-regulated cells: 134 ± 26 W (80–130) vs. 124 ± 32 W (70–200), $p=0.0002$.

Tolerability

No abnormalities were detected in the post-therapeutic clinical examination or in the contrast-enhanced MRI follow-up examination. Neither neurological damage nor reddening of the skin occurred. **Table 4** shows the summary of the level of pain specified by the patients before, during, and immediately after treatment. 39% of the patients never complained of pain. All patients experienced only mild pain or no pain in the post-interventional monitoring phase. Severe pain during treatment was specified in only 3 cases resulting in treatment termination in 2 of the cases. In the other case, the pain was so brief that treatment was able to be continued. In one case, the pain occurred in the area of a C-section scar at the edge of the ultrasound field and in the other cases lumbar and sacral nerve pain occurred. The reproducible occurrence of moderate pain in the sacral area during sonication resulted in the termination of another treatment.

Only 2 remarkable findings were seen in the one-month follow-up period. One patient experienced increased first post-therapeutic menstruation bleeding, and another patient complained of significant pain in the lower abdomen 2 weeks after treatment for a period of several days. However, this pain could not be assigned to a morphological correlate during MRI examination.

Volume reduction

In the reevaluated patients the myoma volume was able to be reduced after 1 month by $28 \pm 21\%$ (7–53) from 108 ± 129 ml (6–411) to 81 ± 97 ml (5–312) ($p=0.003$). After 6 months, the volume reduction was $45 \pm 21\%$ (5–100), and the average myoma volume had decreased to 65 ± 85 ml (0–323) ($p=0.001$) (**Fig. 6**). **Fig. 7** shows an example of the progression of size reduction after successful treatment.

Symptom reduction

The symptoms determined via the UFS-QoL questionnaire were also able to be significantly reduced. The initial SSS of 51 ± 16 points (28–75) of all reevaluated patients was able to be reduced to 44 ± 17 points (22–75) ($p=0.14$) after one month, and by a total of 14 points to 37 ± 17 points (9–66) after six months ($p=0.001$) (**Fig. 8**). 9 of the 13 follow-up patients showed a reduction of the SSS of ≥ 10 points.

Discussion

MR-guided HIFU treatment of uterine fibroids is an effective and reliable method that is completely noninvasive and gentle. The MR-HIFU system in this study uses a novel form of volumetric sonication of large treatment cells with a diameter of up to 16 mm, which involves electronically steering the ultrasound focus in outwardly moving concentric circles (**Fig. 1**). This mechanism ensures higher energy efficiency due to the use of the radial expansion of the thermal energy when heating an inner circle from the next concentric circle [15]. The used feedback mechanism is intended to ensure homogeneous, sufficient heating and thus reliable, constant ablation results regardless of the tissue properties.

level of pain		0 (none)	1 (minor)	2 (moderate)	3 (severe)	mean
number of patients (in %)	prior to treatment	15 (83)	3 (17)	0	0	0.2
	during	7 (39)	4 (22)	4 (22)	3 (17)	1.2
	after treatment	13 (72)	5 (28)	0	0	0.3

Table 4 Pain experienced by patients before, during, and after treatment

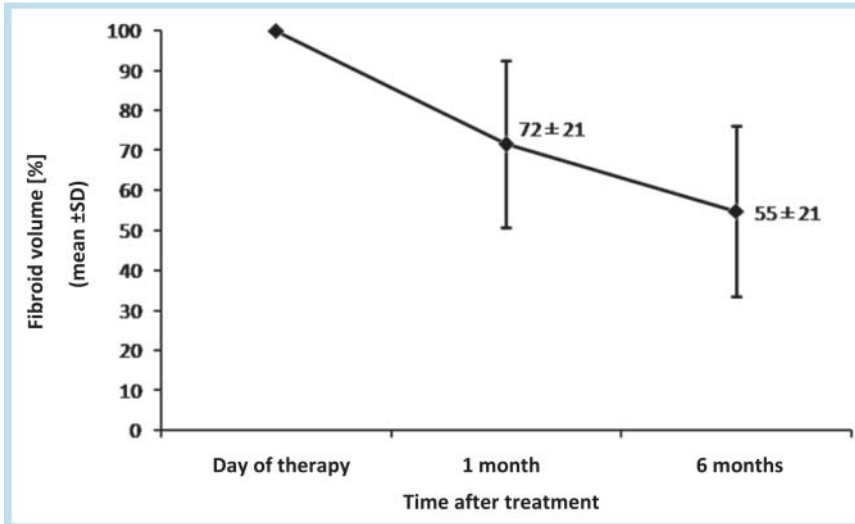


Fig. 6 Post-therapeutic change of the myoma volume in %.

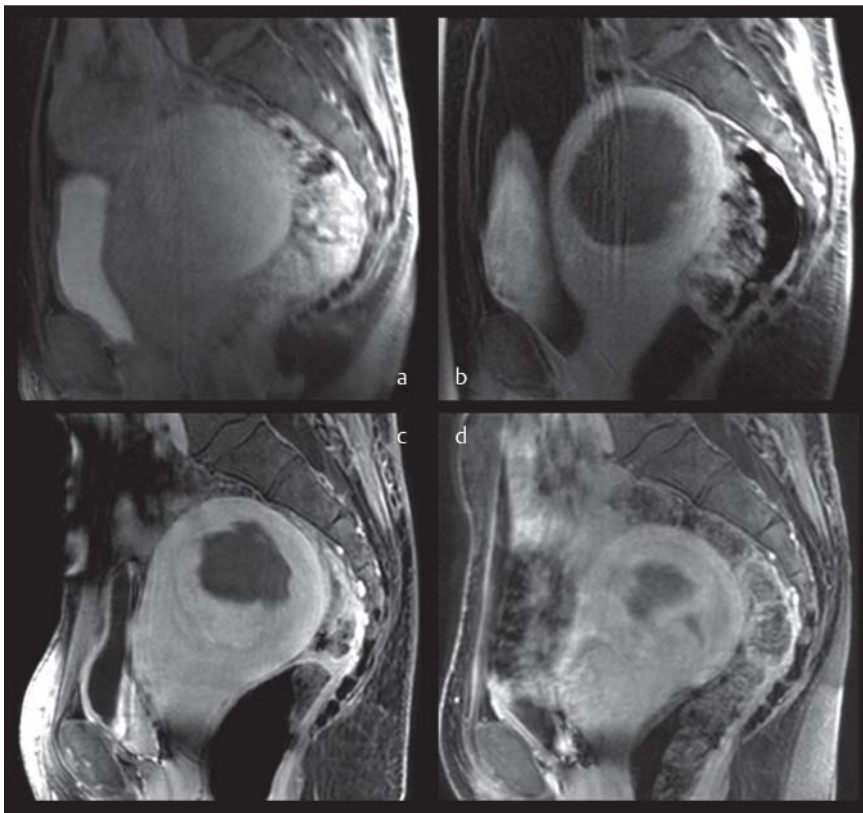


Fig. 7 Exemplary size development. The example shows a large singular myoma prior to treatment (a, 234 ml), immediately after treatment (b, one month after treatment (c, 163 ml), and six months postintervention (d, 131 ml). The hypointense area in b corresponds to the non-perfused volume in terms of induced necrosis which cicatrizes and shrinks over time.

The use of previously introduced feedback mechanisms was always based on the estimation of the intraorganic energy absorption as well as the thermal diffusion. However, valid, reliable feedback regulation is not possible without this knowledge. The novel feedback mechanism is independent

of such difficult-to-predict tissue parameters and thus is significantly more robust and reliable. In the present study the FC reached higher temperatures in the case of successful sonication and induced greater non-perfused volumes than the TC with lower variability. However, the ablation slightly

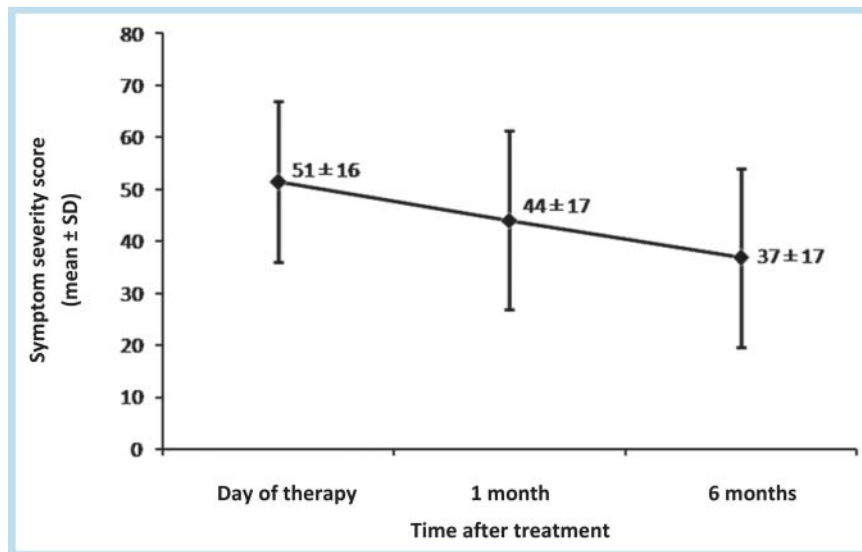


Fig. 8 Development of myoma-related symptoms represented by the symptom severity score of the UFS-QoL questionnaire. High values indicate severe symptoms.

exceeds the planned area. The high rate of feedback sonications that were not completed according to protocol complicates the comparability of the ablation results. A rate of only 28.6% of sonications evaluated by the system as being completed properly reduces the clinical practicability of feedback control. The following can result in a feedback sonication of a submaximal duration: Particularly in the case of small treatment volumes, partial volume effects at a thermometry slice thickness of 7 mm seem to be problematic. Dislocations due to movement during sonication and resulting motion artifacts in the phase contrast representation of the temperature can hinder feedback regulation since the system cannot differentiate between phase differences due to motion and those due to temperature gradients. If sonication is performed with insufficient power, the feedback algorithm criteria that control the transition from the inner to the outer trajectories of the focus path and the completion of sonication are not fulfilled. The power to be applied was determined by a test sonication with low power. The full system power was not always utilized at the start of the learning curve. Due to the still high NPV, it can be assumed that even the feedback sonications terminated by the system resulted in effective ablations. This remains a topic for further systematic analyses. In addition, the current release includes improved software and a new transducer with increased maximum power. The first experiences with the new release show a significantly improved efficiency of the FC with substantially fewer terminations. An NPV ratio of $23 \pm 15\%$ is relatively low but corresponds approximately to the results of previous studies regarding the effectiveness of HIFU using similarly restrictive safety parameters [7, 17]. Examinations in which ablation rates of up to 76.9% were achieved were much more aggressive and decreased the safety distances with respect to the serosa to 2.5 mm. However, due to the initially limited experience of the operator and the lack of study results regarding the precision of the volumetric sonication used here at the time of the treatments, generous safety distances were maintained during the present study to ensure patient safety. However, with increasing experience it is possible to ablate increasingly aggressively without sacrificing patient comfort and safety.

The use of large treatment cells is accompanied by increased energy efficiency, resulting in a relative reduction in treatment time [19]. However, maintaining generous safety distances resulted in limited applicability of large treatment cell volumes. If these are reduced in the future, the efficiency can be further increased. Until the safety limits are reduced, use for larger myomas remains limited. This is also reflected in the treatment time which could not be reduced compared to previous studies [17]. In total, the treatment time remains a limiting factor of HIFU treatment.

The goal of the feedback mechanism is to ensure a sufficient sonication as well as to prevent excessive temperature increases, thus further increasing patient safety [16]. Multiplanar real-time MR thermometry makes it possible to effectively monitor the ablation volume and structures at an increased risk in the near and far field [20]. Particularly when ablating larger volumes, there is a risk of heat accumulation in the near field. However, no undesired lesions occurred in this study. The majority of patients did not experience any pain. The average pain level soon after treatment had already returned to the pretherapeutic level. In the case of symptomatic myomas, HIFU supplements the radiological interventional spectrum that is characterized by minimal invasiveness. In comparison to UAE which can be associated with pain during interventions and with a post-embolization syndrome in 10% of cases [21, 22], HIFU is a very low-pain to painless treatment option that can consequently be performed without problem on an outpatient basis. Treatment had to be stopped in 11% of the patients in our series due to pain during HIFU. The complete prevention of pain-related treatment terminations is desirable since this is a gentle technique. A more stringent analgesic regime, e.g., with intravenous opioids, which were not used in this study, is a possibility for this purpose. The ovaries are also not exposed to radiation in HIFU compared to UAE. Both interventional methods have a very short recovery time compared to surgery.

The achieved reduction of the myoma volume of 45.8% after 6 months is in agreement with previous studies with reduction rates of 13.5 – 46% [17, 23, 24]. Different reasons for the increase in volume reduction beyond the NPV are being dis-

cussed. In addition to induced cell death as part of the so-called bystander effect according to which damaged cells in the myoma cause apoptosis of surrounding undamaged cells via intercellular signal transduction [25], the post-therapeutic formation of an intracapsular edema is responsible for the expanded tissue damage [26]. Cells on the edge of the tissue heating that are not exposed to a lethal thermal dose but to a sufficiently high temperature to induce defects in the cellular structure are limited by defective supply in their repair mechanisms. The optimum treatment plan or the most efficient sonication strategy remains unclear since the above effects cannot be precisely predicted. Therefore, a number of workgroups are currently addressing the influence of different tissue parameters, how they are visualized in MRI, and the effect of treatment cell size and energy on treatment time and outcome.

In addition to the volume reduction, HIFU treatment results in an effective reduction of symptoms which can be objectivized by a reduction of the symptom severity score or an increase in the quality of life score. In a study recently published by Kamp et al., the UFS-QoL of 64.7 prior to treatment was able to be significantly and continuously increased via HIFU to 82.8 after 12 months [27]. In our study the SSS was lowered by an average of 14 points and the symptoms were thus significantly improved. Other previous HIFU studies in which the UFS-QoL was also used even showed an average reduction of the SSS of 20 [28] to 30 points [7] after 6 months with a similar volume reduction. Particularly when treating large volumes, the resorption of the necrotic tissue was not yet complete after 6 months. A further volume and symptom reduction over time consequently seems possible.

In summary, the application of volumetric sonication with feedback regulation results in homogeneous heating and sufficient necrotization without the induction of undesired lesions or the occurrence of other treatment-related side effects and is therefore an effective and safe treatment method. The myoma volume and the accompanying symptoms were able to be significantly reduced, and the application of aggressive treatment schemas with treatment of larger volumes can further increase treatment success in the future.

References

- 1 Stewart EA. Uterine fibroids. *Lancet* 2001; 357: 293–298
- 2 Chavez NF, Stewart EA. Medical treatment of uterine fibroids. *Clin Obstet Gynecol* 2001; 44: 372–384
- 3 Kröncke TJ. Myomembolisation in Deutschland: unbekannt, ungenutzt, ungewollt? *Fortschr Röntgenstr* 2010; 182: 563–564
- 4 Luciano AA. Myomectomy. *Clin Obstet Gynecol* 2009; 52: 362–371
- 5 Rabinovici J, Inbar Y, Revel A et al. Clinical improvement and shrinkage of uterine fibroids after thermal ablation by magnetic resonance-guided focused ultrasound surgery. *Ultrasound Obstet Gynecol* 2007; 30: 771–777
- 6 Stewart EA, Gedroyc WM, Tempany CM et al. Focused ultrasound treatment of uterine fibroid tumors: safety and feasibility of a noninvasive thermoablative technique. *Am J Obstet Gynecol* 2003; 189: 48–54
- 7 Fennessy FM, Tempany CM, McDannold NJ et al. Uterine leiomyomas: MR imaging-guided focused ultrasound surgery – results of different treatment protocols. *Radiology* 2007; 243: 885–893
- 8 Chapman A, ter Haar G. Thermal ablation of uterine fibroids using MR-guided focused ultrasound – a truly non-invasive treatment modality. *Eur Radiol* 2007; 17: 2505–2511
- 9 Seror O, Lepetit-Coiffe M, Le Bail B et al. Real time monitoring of radio-frequency ablation based on MR thermometry and thermal dose in the pig liver in vivo. *Eur Radiol* 2008; 18: 408–416
- 10 Harris GR. FDA regulation of clinical high intensity focused ultrasound (HIFU) devices: Conference proceedings: ... Annual International Conference of the IEEE Engineering in Medicine and Biology Society. IEEE Engineering in Medicine and Biology Society. Conference. 2009, 145–148
- 11 Ishihara Y, Calderon A, Watanabe H et al. A precise and fast temperature mapping using water proton chemical shift. *Magn Reson Med* 1995; 34: 814–823
- 12 Sapareto SA, Dewey WC. Thermal dose determination in cancer therapy. *Int J Radiat Oncol Biol Phys* 1984; 10: 787–800
- 13 Froeling V, Scheurig-Muenkler C, Steffen IG et al. Änderung der gesundheitsbezogenen Lebensqualität und der klinischen Beschwerdestärke nach Uterusarterienembolisation bei symptomatischer Adenomyosis uteri evaluiert mittels standardisiertem Fragebogen. *Fortschr Röntgenstr* 2012; 184: 48–52
- 14 Spies JB, Coyne K, Gaaou Gaaou N et al. The UFS-QoL, a new disease-specific symptom and health-related quality of life questionnaire for leiomyomata. *Obstet Gynecol* 2002; 99: 290–300
- 15 Kohler MO, Mougnot C, Quesson B et al. Volumetric HIFU ablation under 3D guidance of rapid MRI thermometry. *Med Phys* 2009; 36: 3521–3535
- 16 Enholm JK, Kohler MO, Quesson B et al. Improved volumetric MR-HIFU ablation by robust binary feedback control. *IEEE Trans Biomed Eng* 2009; 57: 103–113
- 17 Hindley J, Gedroyc WM, Regan L et al. MRI guidance of focused ultrasound therapy of uterine fibroids: early results. *Am J Roentgenol Am J Roentgenol* 2004; 183: 1713–1719
- 18 Zhang L, Chen WZ, Liu YJ et al. Feasibility of magnetic resonance imaging-guided high intensity focused ultrasound therapy for ablating uterine fibroids in patients with bowel lies anterior to uterus. *Eur J Radiol* 2009; 73: 396–403
- 19 Kim YS, Keserci B, Partanen A et al. Volumetric MR-HIFU ablation of uterine fibroids: Role of treatment cell size in the improvement of energy efficiency. *Eur J Radiol* 2012; 81: 3652–3659
- 20 Eckey T, Neumann A, Bohlmann MK et al. Nichtinvasive Thermoablation symptomatischer Uterusmyome mit MR-gesteuertem hochenergetischem Ultraschall. *Radiologe* 2011; 51: 610–619
- 21 Emons G, Kiesel L, Runnebaum I et al. Kommentar der Kommission Uterus der AGO zum Konsensuspapier des 3. Radiologisch-gynäkologischen Expertentreffens zur Behandlung von Uterusmyomen durch Uterusarterienembolisation (UAE) in München, 15. Januar 2010. *Fortschr Röntgenstr* 2010; 182: 1016–1017
- 22 Kröncke T, David M. Uterusarterienembolisation (UAE) zur Myombehandlung – Ergebnisse des 3. radiologisch-gynäkologischen Expertentreffens. *Fortschr Röntgenstr* 2010; 182: 615–617
- 23 Funaki K, Fukunishi H, Funaki T et al. Mid-term outcome of magnetic resonance-guided focused ultrasound surgery for uterine myomas: from six to twelve months after volume reduction. *J Minim Invasive Gynecol* 2007; 14: 616–621
- 24 LeBlang SD, Hoxter K, Steinberg FL. Leiomyoma shrinkage after MRI-guided focused ultrasound treatment: report of 80 patients. *Am J Roentgenol* 2010; 194: 274–280
- 25 Niu H, Simari RD, Zimmermann EM et al. Nonviral vector-mediated thymidine kinase gene transfer and ganciclovir treatment in leiomyoma cells. *Obstet Gynecol* 1998; 91: 735–740
- 26 McDannold N, Tempany CM, Fennessy FM et al. Uterine leiomyomas: MR imaging-based thermometry and thermal dosimetry during focused ultrasound thermal ablation. *Radiology* 2006; 240: 263–272
- 27 Kamp JE, David M, Scheurig-Muenkler C et al. Klinische Ergebnisse der Behandlung symptomatischer Uterusmyome mittels MRgFUS (Magnetresonanztomographie-gesteuerter fokussierter Ultraschall). *Fortschr Röntgenstr* 2013; 185: 136–143
- 28 Funaki K, Fukunishi H, Sawada K. Clinical outcomes of magnetic resonance-guided focused ultrasound surgery for uterine myomas: 24-month follow-up. *Ultrasound Obstet Gynecol* 2009; 34: 584–589