

Abdominal Cystic Lymphangioma Mimicking Appendicitis

Sarah Wake¹ Aruna Abhyankar¹ Kim Hutton¹

¹Department of Paediatric Surgery, University Hospital of Wales, Cardiff, United Kingdom

Eur J Pediatr Surg Rep 2013;1:32–34.

Address for correspondence Sarah Wake, MBChB, MRCPCH, Department of Paediatric Surgery, University Hospital of Wales, Children's Hospital for Wales, Heath Park, Cardiff CF14 4XW, United Kingdom (e-mail: sarah.wake@doctors.org.uk).

Abstract

Keywords

- ▶ lymphangioma
- ▶ cyst
- ▶ appendicitis
- ▶ abdomen

A cystic lymphangioma arising within the abdomen is a rare entity in children. It may present with an abdominal mass and symptoms of abdominal pain, vomiting, and anorexia. These nonspecific clinical symptoms are often attributed to more common acute pediatric conditions. In this report, we describe two pediatric cases of intra-abdominal cystic lymphangioma that were initially diagnosed and treated as appendicitis. True diagnosis was only achieved on surgical excision and pathological investigation of cystic material.

Introduction

Lymphangiomas are benign congenital malformations of vascular origin that arise from sequestered lymphatic tissue, resulting in a cystic mass that fails to communicate with the normal lymphatic drainage system.¹ Lymphangiomas constitute 5% of all benign tumors in infants and children² with 95% occurring in the neck and axilla. Others areas can be affected including the abdominal viscera and retroperitoneum. Lymphangiomas do not regress and cause symptoms due to their mass effect on surrounding structures or secondary infection. Patients with an intra-abdominal cystic lymphangioma may present with an abdominal mass. We describe two pediatric cases that were initially misdiagnosed as having appendicitis. Their presentations highlight the broad range of pathologies that may present as an acute abdomen in childhood.

Case 1

A 5-year-old boy suffering from lethargy, vomiting, central abdominal pain, and mild right iliac fossa tenderness in the previous 2 days presented to a local hospital. Inflammatory blood markers were moderately raised. Over the following day, the child became progressively more unwell with increased pain and several episodes of vomiting. The abdomen was reexamined showing tenderness and fullness of the right

iliac fossa. A provisional diagnosis of acute appendicitis with associated appendix mass was made. He was commenced on intravenous antibiotics with admission pending on ultrasound investigation.

Furthermore, history of the parents revealed a more chronic presentation than first thought, with a 3-month history of episodic abdominal pain, constipation, abdominal distension, anorexia, and a 4-kg weight loss. He had been investigated for celiac and inflammatory bowel disease with negative results.

Ultrasound examination demonstrated a large cystic fluid collection with swirling internal echoes, measuring 13 × 14 × 6 cm within the mid-abdomen and extending behind the bladder. The mass was seen to displace the bowel loops laterally. A differential diagnosis of (1) an infected collection after appendicitis, (2) a gastrointestinal duplication cyst, or (3) a complicated Meckel diverticulum was done.

Percutaneous drainage was performed yielding a large volume of turbid yellow fluid, appearing suspiciously like urine although this was ruled out on subsequent biochemical analysis. A cystourethroscopy was normal. The patient was treated symptomatically with drainage and intravenous antibiotics to good effect. However, follow-up ultrasound at 2 weeks revealed recurrence of the cystic mass. CT could not clearly separate the mass from adjacent sigmoid and rectum. At laparotomy, the cystic mass was separate from

received
November 21, 2012
accepted after revision
December 16, 2012
published online
March 20, 2013

© 2013 Georg Thieme Verlag KG
Stuttgart · New York

DOI <http://dx.doi.org/10.1055/s-0033-1337114>.
ISSN 2194-7619.

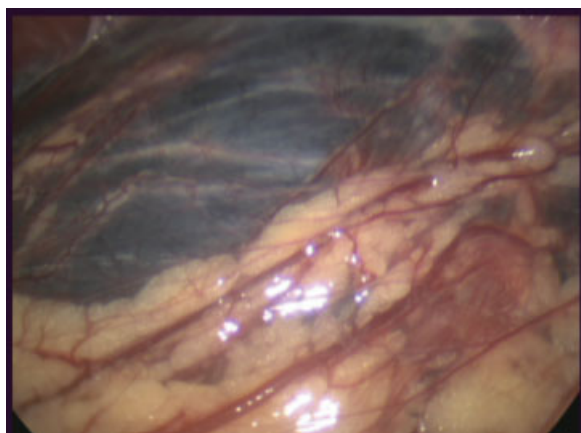


Fig. 1 Intraoperative image illustrating cyst location adherent to omental tissue.

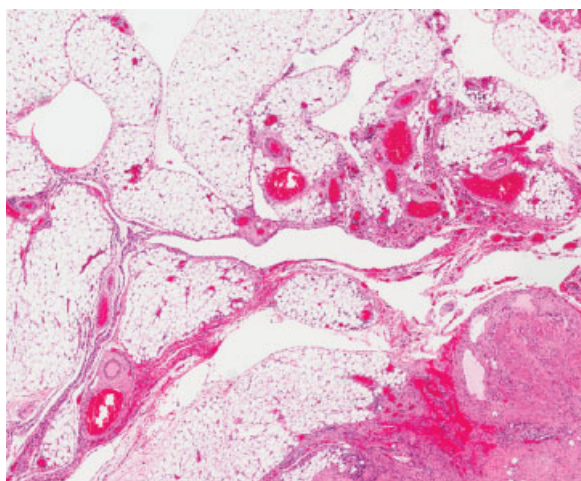


Fig. 2 Photomicrograph of histopathological specimen showing large thin-walled cystic spaces lined with attenuated endothelium.

the small bowel mesentery but adherent to the omentum and abdominal wall in the suprapubic region (→ **Fig. 1**). The cyst was safely removed together with a Meckel diverticulum, the appendix, and a part of the omentum.

Subsequent histology demonstrated omental tissue with chronic inflammation, granulation tissue and fibrosis (→ **Fig. 2**). Immunohistochemistry showed numerous lymphatic channels and endothelial lining with a final diagnosis of an intra-abdominal cystic lymphangioma.

Case 2

A 4-year-old boy presented with a 5-month history of abdominal pain in the right lower quadrant. Pain was episodic and increasing in severity. Examination revealed marked tenderness in the right side of the abdomen. Blood tests showed no sign of inflammation or infection. He was admitted overnight for observation on a working diagnosis of appendicitis. Next day, the pain remained and an ultra-

sound examination was performed demonstrating a fluid collection of $4 \times 4 \times 3.5$ cm in the right iliac fossa. A diagnosis of appendicular mass was made. He was managed conservatively with triple intravenous antibiotics for 7 days and was then discharged despite little improvement in his symptoms. Follow-up ultrasound demonstrated an increase in the size of the mass to $4.8 \times 4.4 \times 3.0$ cm. CT scan demonstrated two separate cystic masses in the right abdomen.

Exploratory laparotomy revealed a large multicystic extraperitoneal mass 10×5 cm, extending from the lower pole of the right kidney as far distally as the femoral vessels where the lesion wrapped itself around the femoral sheath and femoral nerve. The mass was carefully excised. Histology showed cyst lining containing cells positive for the lymphatic marker D-240, thus confirming a diagnosis of retroperitoneal cystic lymphangioma.

Conclusion

Abdominal cystic lymphangioma are rare entities in children with an estimated incidence of 1 to 4 per 100,000 and either an intraperitoneal or retroperitoneal localization.³ It is more common in boys and is usually present in children younger than 5 years, as in our two cases. Abdominal lymphangiomas occur most commonly in the mesentery, followed by omentum, mesocolon, and retroperitoneum.⁴

Accurate preoperative diagnosis is often difficult because there is a varied clinical spectrum and diverse mode of presentation. The majority present with acute on chronic symptoms secondary to an increasing mass effect on surrounding structures. Abdominal pain, nausea, vomiting, and anorexia are the most commonly documented symptoms. Most children with mesenteric or omental cysts have abdominal distension with or without an abdominal mass. A mass may be difficult to palpate due to its large size, soft and fluid consistency, and mobility. A very large mass can stimulate ascites. Clinical presentation may be misleading due to a lack of awareness of the condition and the wide range of nonspecific symptoms and clinical signs are present. This can lead to misdiagnosis as in our two cases, where the initial diagnosis was thought to be a much more common abdominal pathology—appendicitis. Although rare, cystic lymphangioma should be considered when children present with vague and recurrent abdominal pain and in those who fail to respond as expected to appropriate management. Inflammatory markers may be raised due to internal hemorrhage and infection but rarely to the level of an appendicular mass. The early use of ultrasound in these cases is strongly advocated.

Optimum treatment is complete resection. Surgical intervention is recommended as soon as possible following diagnosis due to the secondary risk of torsion, hemorrhage, infection, and bowel obstruction. Once the cyst is excised the prognosis is excellent. Recurrence after surgical excision is rare—it has not occurred in either of our cases to date.

References

- 1 Sun CC, Tang CK, Hill JL. Mesenteric lymphangioma. A case report with transmission and scanning electron microscopic studies. *Arch Pathol Lab Med* 1980;104(6):316–318
- 2 Rønning G, Revhaug A, Størmer J, Eide TJ, Lindal S. Cystic lymphangioma of the small bowel mesentery. *Eur J Surg* 1995; 161(3):203–205
- 3 Hisham F. Abdominal cystic lymphangioma in children. *Ann Pediatr Surg* 2009;2:132–136
- 4 Levy AD, Cantisani V, Miettinen M. Abdominal lymphangiomas: imaging features with pathologic correlation. *AJR Am J Roentgenol* 2004;182(6):1485–1491