

Esophageal metallic stent fixation with dental floss: a simple method to prevent migration



Fig. 1 The dental floss is grasped with a small-sized biopsy forceps.

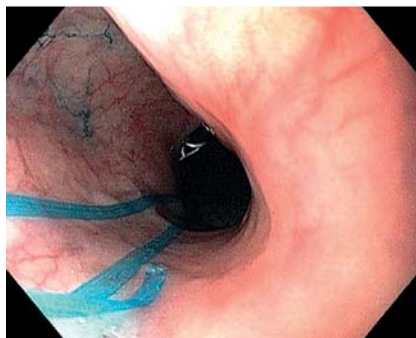

Fig. 3 The dental floss in position.

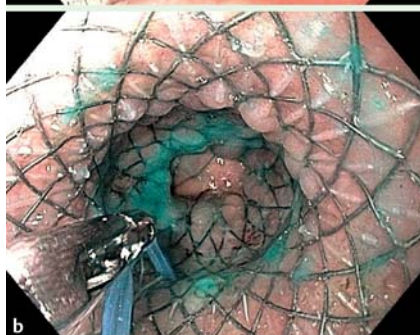
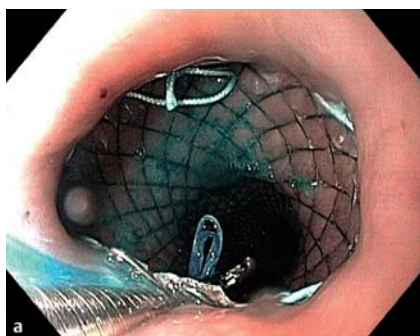
Fig. 2 **a** The dental floss is passed through the stent mesh from the outside to the inside. **b** The floss is then carried down using the biopsy forceps.

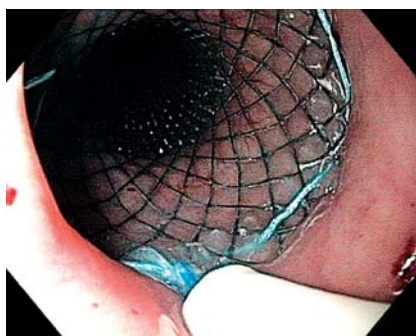


Fig. 4 The dental floss is inserted into a nasenteral tube, which is pushed down towards the mesh to protect the nasopharyngeal mucosa.

Use of fully and partially covered self-expanding metallic esophageal stents (SEMS) is associated with high rates of migration [1]. Stent modification with a silk thread to permit external fixation, proposed by Shim et al., has been shown to reduce migration [2] but this stent may not be routinely available. Therefore we present another modified stent technique

that can be used in patients with or at risk for stent migration.

A piece of dental floss is grasped with a biopsy forceps (● Fig. 1) and advanced to the esophagus. The endoscope is positioned at the upper border of the stent and the forceps carrying the floss is passed through the stent mesh from the outside to the inside and advanced again (● Fig. 2). The endoscope is passed further through the stent and the floss is grasped with the forceps and gently pulled back, taking care to avoid stent dislodgment (● Fig. 3). Finally, using a method similar to exchange of a nasobiliary drainage catheter (● Fig. 4), the dental floss is drawn out through the nose, and, after having tied a knot into it, its loose end is fixed to the patient's earlobe. Upper endoscopy is repeated 2 weeks

after the procedure and, if the proximal uncovered flange of the stent is embedded in the esophageal mucosa and does not separate from the esophagus with air insufflation, the external fixation is removed.

This method has been successfully used in eight patients with esophageal malignancies. Of the stents used in these patients, seven were partially covered and one was fully covered. In the patient with the fully covered stent, a needle-knife was used to puncture the sheath, allowing the passage of the dental floss through the mesh. We believe the external fixation using dental floss is a simple and cheap method that can be applied to any kind and size of stent.

Endoscopy_UCTN_Code_TTT_1AO_2AZ

Competing interests: None

B. da Costa Martins, B. F. Medrado, M. S. de Lima, F. A. Retes, F. S. Kawaguti, C. M. P. S. Pennacchi, F. Maluf-Filho

Cancer Institute of São Paulo University Medical School, Endoscopy Division, São Paulo, São Paulo, Brazil

References

- 1 Verschuur EML, Repici A, Kuipers EJ et al. New design esophageal stents for the palliation of dysphagia from esophageal or gastric cardia cancer: a randomized trial. *Am J Gastroenterol* 2008; 103: 304–312
- 2 Shim CS, Cho YD, Moon JH et al. Fixation of a modified covered esophageal stent: its clinical usefulness for preventing stent migration. *Endoscopy* 2001; 33: 843–848

Bibliography

DOI <http://dx.doi.org/10.1055/s-0033-1344129>
Endoscopy 2013; 45: E342
 © Georg Thieme Verlag KG
 Stuttgart · New York
 ISSN 0013-726X

Corresponding author

B. da Costa Martins
 Endoscopy Division
 Cancer Institute of São Paulo Medical School
 University of São Paulo
 Av. Dr. Arnaldo
 251 São Paulo
 Brazil 01246-000
 bcm.bruno@gmail.com