

Successful pancreatic endotherapy achieved with double guide wire technique after failed pancreatic duct cannulation

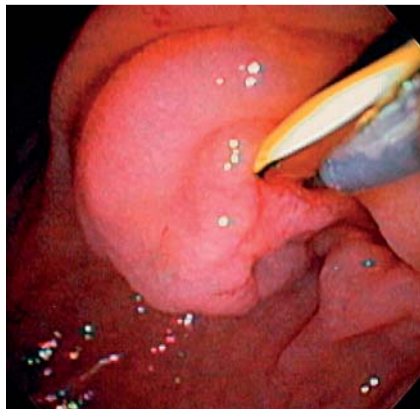


Fig. 1 Endoscopic view of the biliary guide wire along with the sphincterotome and guide wire approaching the ampulla.

A 41-year-old white man with pancreatic ascites and pleural effusion was referred for endoscopic retrograde cholangiopancreatography (ERCP). A previous endoscopic ultrasound (EUS) showed features of chronic pancreatitis with an irregular, undilated, hyperechoic walled pancreatic duct with no evidence of pancreas divisum. At ERCP, several attempts at selective wire-guided cannulation of the pancreatic duct failed.

In order to avoid multiple instrumentation of the pancreatic ductal orifice and the consequent risk of pancreatitis, a 0.035-inch guide wire (Jagwire; Boston Scientific Corp., Natick, Massachusetts, USA) was placed in the common bile duct, kept stiff, and pulled cephalad in order to stretch the common channel. A sphincterotome preloaded with a hydrophilic Glidewire (Terumo Medical Corp., Somerset, New Jersey, USA) was used to approach the ampulla from above. The Glidewire was advanced inferior to the existing biliary guide wire and was passed at the 1 o'clock position into the pancreatic duct (● Fig. 1). Contrast injection confirmed a pancreatic ductal leak near the neck of the pancreas (● Fig. 2). A bridging 5-Fr, 12-cm plastic stent (Cook Endoscopy, Winston-Salem, North Carolina, USA) was inserted and achieved adequate drainage (● Fig. 3). No complications were encountered.

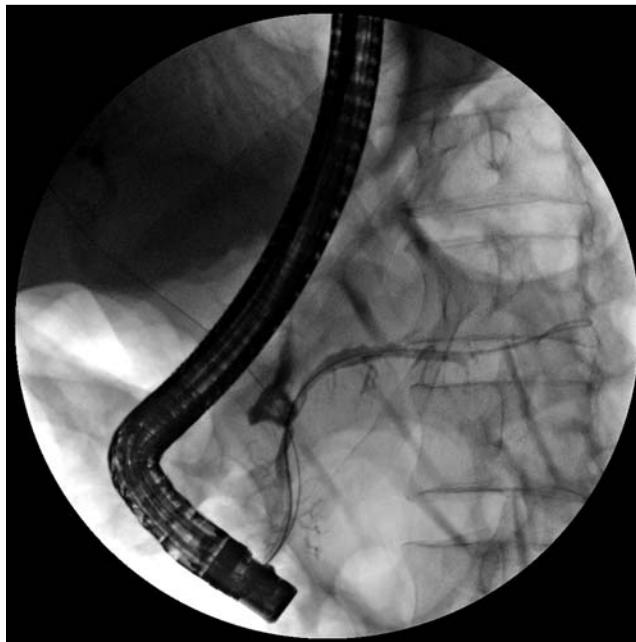


Fig. 2 Pancreatic ductal leak near the neck of the pancreas. The biliary and pancreatic guide wires are in place. Note the "U" technique for the pancreatic guide wire.

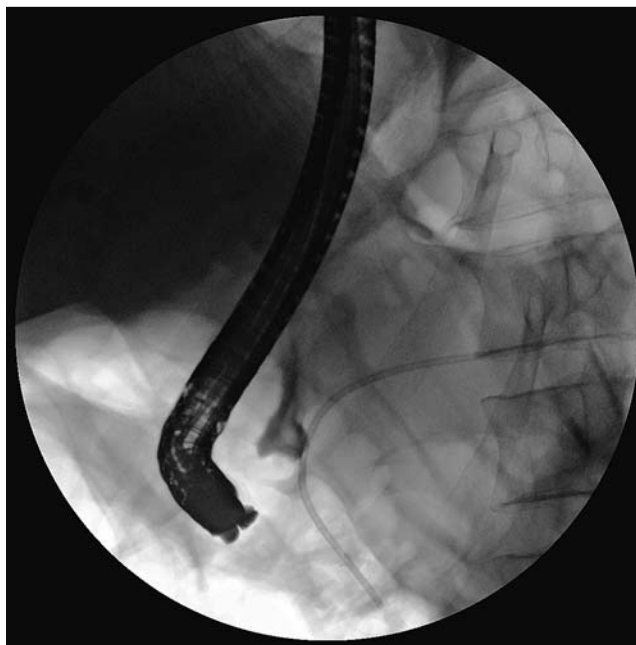

Fig. 3 The bridging pancreatic plastic stent inserted.

Selective cannulation during ERCP can be challenging even in the hands of experienced endoscopists. The double guide wire technique for deep bile duct cannulation with the help of a pancreatic guide wire described by Dumonceau et al. [1], is a well-established technique along with

other alternatives for failed bile duct cannulation [2]. Options are limited for pancreatic duct access. Pancreatic duct cannulation is considered to be easier than bile duct access but deep cannulation of the pancreatic duct can be challenging in ansa pancreatica, strictures, calculi, or

anatomical variation of the pancreatic duct. In the case described above, cannulation of the ampullary portion of the duct was challenging. Options here include a biliary sphincterotomy to expose the pancreatic duct orifice or EUS-guided rendezvous procedure if the pancreatic duct is dilated. However, both alternatives are not without risks and the double guide wire technique is a safer initial approach.

Endoscopy_UCTN_Code_TTT_1AR_2AB

Competing interests: None

D. Popa, K. Mönkemüller, C. M. Wilcox, J. Ramesh

Division of Gastroenterology and Hepatology, Basil Hirschowitz Endoscopic Center of Excellence, University of Alabama, Birmingham, Alabama, USA

References

- 1 *Dumonceau JM, Deviere J, Cremer M.* A new method of achieving deep cannulation of the common bile duct during endoscopic retrograde cholangiopancreatography. *Endoscopy* 1998; 30: 580
- 2 *Freeman MI, Guda NM.* ERCP cannulation: a review of reported techniques. *Gastrointest Endosc* 2005; 61: 112–125

Bibliography

DOI <http://dx.doi.org/10.1055/s-0033-1344221>
Endoscopy 2013; 45: E210–E211
© Georg Thieme Verlag KG
Stuttgart · New York
ISSN 0013-726X

Corresponding author

J. Ramesh, MD

Division of Gastroenterology and Hepatology
Basil Hirschowitz Endoscopic Center of Excellence
Endoscopy Unit, JT 664
619 19th Street S
Birmingham, AL 35249
USA
j1ramesh@gmail.com