Large serrated polyp with *KRAS* mutation in inflammatory bowel disease: a "nondysplastic dysplasia-associated lesion or mass (DALM)"?

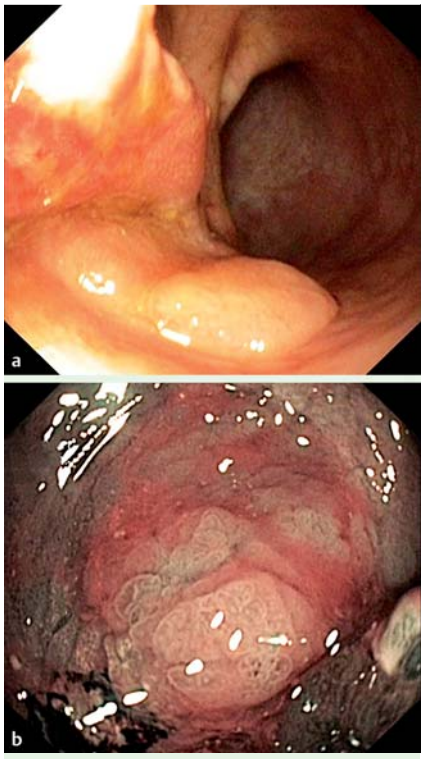

Fig. 1 **a** Large irregular polyp in the sigmoid colon in a 52-year-old woman with 20-year history of ulcerative colitis. **b** Note the discrete surface irregularities analyzed by narrow band imaging.

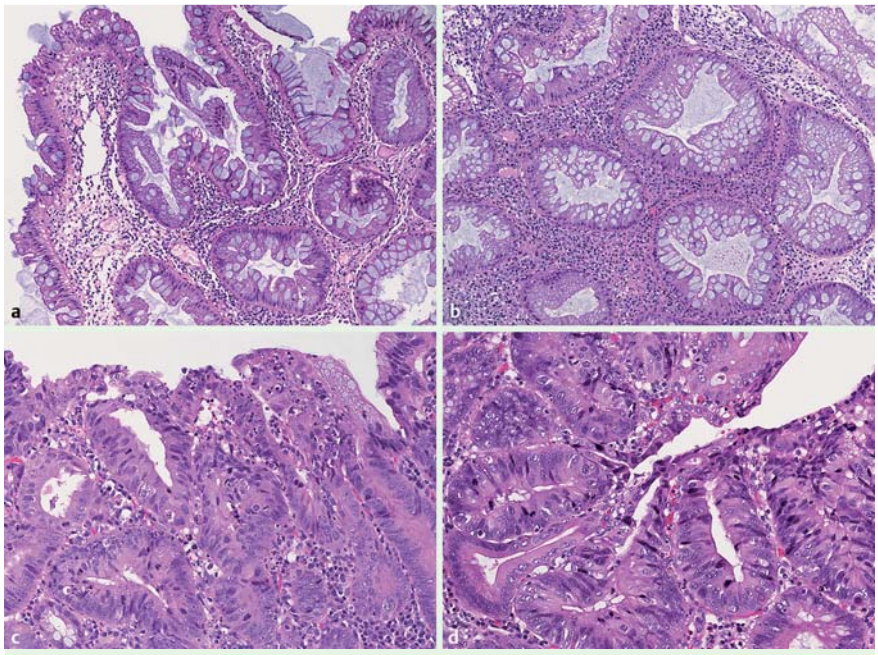

Fig. 2 **a, b** Nondysplastic serrated polyp with marked crypt dilatation within the sigmoid colon (hematoxylin and eosin, original × 100). **c, d** Conventional high grade dysplasia-associated lesion or mass (DALM) at the rectosigmoid junction (hematoxylin and eosin, original × 200).

Patients with longstanding inflammatory bowel disease (IBD) have an increased risk of colorectal cancer. A causal link between chronic inflammation and cancer is well recognized. Precursor lesions include flat dysplasia (intraepithelial neoplasia) and elevated dysplasia, also known as dysplasia-associated lesion or mass (DALM) [1].

A 52-year-old woman with 20-year history of ulcerative colitis underwent surveillance colonoscopy, which disclosed a large irregular polyp in the sigmoid colon (**Fig. 1**). Biopsies showed a nondysplastic polyp with marked crypt dilatation and serration (**Fig. 2 a, b**). This polyp was completely removed and a second lesion clearly showing dysplastic glands was discovered at the rectosigmoid junction, and was diagnosed as high grade DALM (**Fig. 2 c, d**). Molecular analysis of the serrated polyp revealed *KRAS* mutation in exon 13 (**Fig. 3**); tests for *BRAF* mutation and microsatellite instability were negative.

In 2008, Srivastava et al. [2] reported a series of three patients with longstanding IBD who developed numerous "hyperplastic/serrated" colonic polyps similar to those described in the "hyperplastic/serrated" polyposis syndrome. Two patients had synchronous colorectal cancer. *KRAS* mutation was detected in five of the 11 polyps. These findings suggested the possibility of a serrated pathway of carcinogenesis in IBD. In the sporadic setting, sessile serrated adenomas/polyps (SSA/P) are known precursors of mainly right-sided microsatellite instable cancers. They may also be regarded as indicator lesions, as these polyps have been associated with increased risk of synchronous and/or metachronous cancer growth, particularly of the proximal colon [3, 4].

We believe our case to be the first description of a solitary serrated polyp with *KRAS* mutation, similar to the lesions occurring as polyposis in longstanding IBD described by Srivastava et al. [2]. These nondysplastic lesions may indicate increased risk of synchronous and/or metachronous advanced neoplasia and may be the equivalent of conventional DALMs with respect to cancer prediction ("nondysplastic DALM").

Endoscopy_UCTN_Code_CCL_1AD_2AB

Competing interests: None

L. Setaffy[1], C. Högenauer[2], M. Lemmerer[3], C. Langner[1]

[1] Institute of Pathology, Medical University, Graz, Austria
[2] Department of Internal Medicine, Division of Gastroenterology and Hepatology, Medical University, Graz, Austria
[3] Department of Surgery, Krankenhaus der Barmherzigen Brüder, Academic Teaching Hospital, Graz, Austria

This document was downloaded for personal use only. Unauthorized distribution is strictly prohibited.

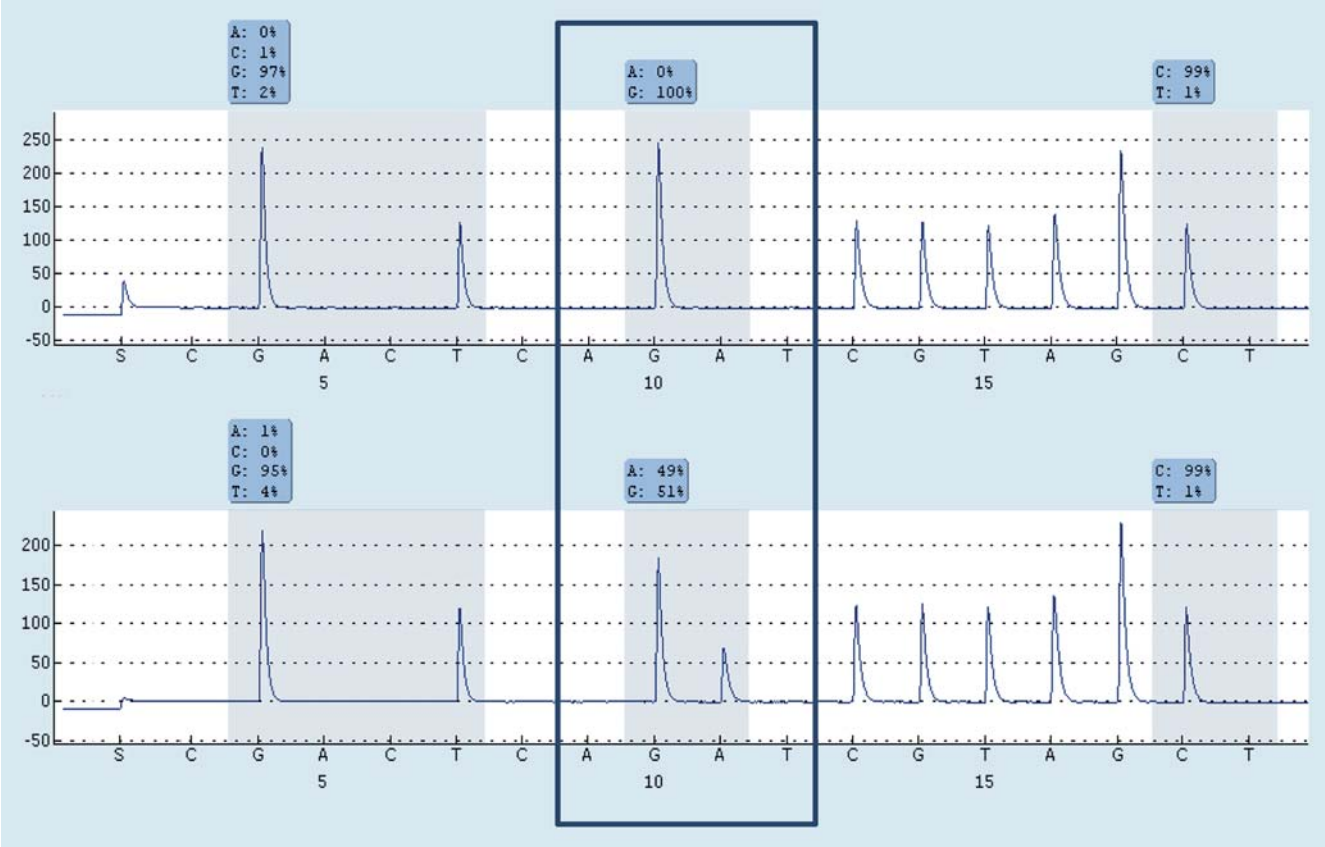

Fig. 3 Molecular analysis (pyrosequencing of the *KRAS* gene) of the serrated polyp showing a somatic missense mutation in codon 13: wildtype control (upper panel) and serrated polyp (lower panel).

References

1 *Van Assche G, Dignass A, Bokemeyer B* et al. Second european evidence-based consensus on the diagnosis and management of ulcerative colitis part 3: special situations. J Crohns Colitis 2013; 7: 1 – 33

2 *Srivastava A, Redston M, Farraye FA* et al. Hyperplastic/serrated polyposis in inflammatory bowel disease: a case series of a previously undescribed entity. Am J Surg Pathol 2008; 32: 296 – 303

3 *Li D, Jin C, McCulloch C* et al. Association of large serrated polyps with synchronous advanced colorectal neoplasia. Am J Gastroenterol 2009; 104: 695 – 702

4 *Hiraoka S, Kato J, Fujiki S* et al. The presence of large serrated polyps increases risk for colorectal cancer. Gastroenterology 2010; 139: 1503 – 1510

Bibliography

DOI http://dx.doi.org/10.1055/s-0033-1344321
Endoscopy 2013; 45: E235–E236

© Georg Thieme Verlag KG Stuttgart · New York

ISSN 0013-726X

Corresponding author

C. Langner
Institute of Pathology
Medical University Graz
Auenbruggerplatz 25
A-8036 Graz
Austria
Fax: +43-316-38513432
cord.langner@medunigraz.at

This document was downloaded for personal use only. Unauthorized distribution is strictly prohibited.