

Fatal aortogastric fistula following fully covered metal stent placement for refractory esophageal stricture

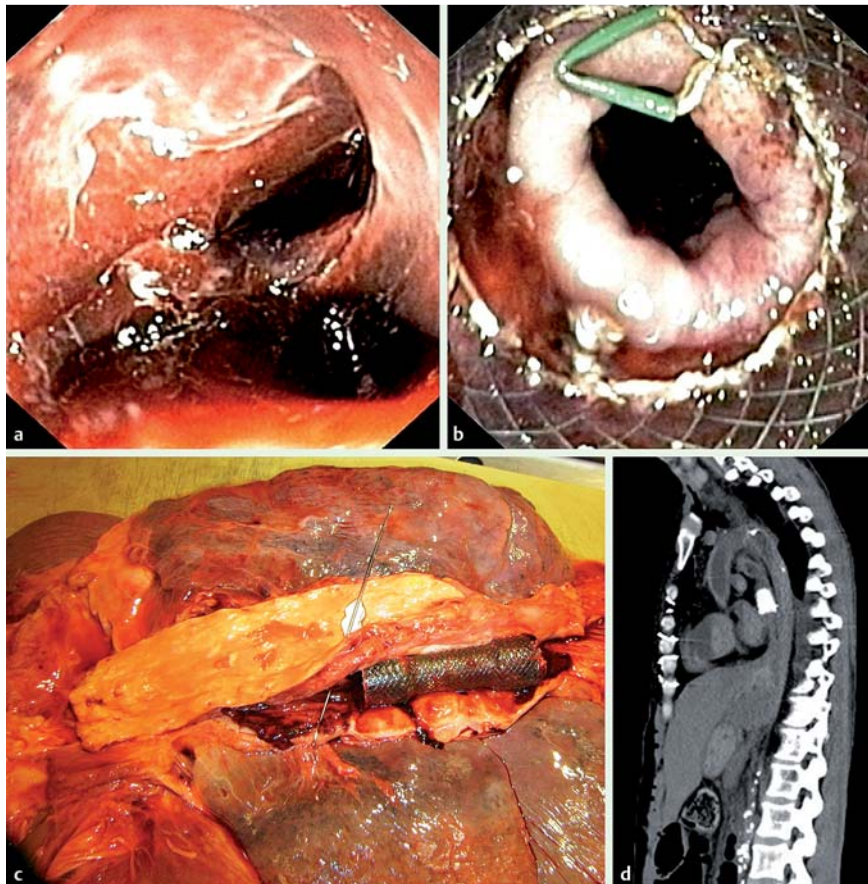


Fig. 1 Emergency upper endoscopy and full-body computed tomography were performed following massive hematemesis and hemodynamic instability 3 weeks after placement of a fully covered stent. **a** Visualization of the anastomosis. **b** Distal part of the fully covered stent resting on the pylorus (migrated stent). **c** Post-mortem autopsy: aorto-gastric fistula located at the distal end of the fully covered stent (metal arrow). **d** Post-mortem full-body scan showing close contact between the stent and the aorta.

A 45-year-old woman with a history of systemic sclerosis presented with a post-anastomotic gastric tube stenosis 1 year after esophagus resection and gastric tube interposition for a ypT3N1M0 adenocarcinoma of the esophagus. She was also treated with neo-adjuvant chemoradiation therapy [1]. Endoscopy identified a post-anastomotic esophageal stenosis extending from 24 cm to 32 cm aborally. She had shown only a limited response to 23 Savary dilations and one balloon dilation in 9 months. We therefore decided to use an 18 × 12 cm fully covered metal stent (Evolution; Cook Medical Inc., Bloomington, Indiana, USA) across the stenosis.

The patient presented 3 weeks after stent deployment with massive hematemesis and hemodynamic instability. Emergency endoscopy revealed a massive amount of blood and a distally displaced stent (Fig. 1a,b), but no active bleeding was seen. A second endoscopy in the intensive care unit revealed a massive amount of blood in the esophagus, but still without a visible cause. Because the patient now required resuscitation (there was no measurable blood pressure), she was transferred to the operating theater. An emergency thoraco-laparo-phrenicotomy was performed and a bleeding source from the aorta was identified and manually occluded. Unfortunately, by this time

the patient did not show any cardiac activity in spite of direct cardiac massage and chemical resuscitation, and she died during surgery. A post-mortem full-body computed tomography scan and autopsy revealed an aortogastric fistula on the downwards-migrated distal part of the esophageal stent (Fig. 1b,c).

An aorto-esophageal fistula (AEF) is an infrequent, but mostly fatal complication after esophagectomy [2, 3]. Thoracic aortic aneurysms are the most common cause of AEF; further causes include foreign body ingestion, trauma (usually iatrogenic), carcinoma or, rarely, tuberculous aortitis [3]. The literature on esophageal stent-related AEF is scarce, and can be classified as follows.

1. Anatomic-aortic fistula
 - ▶ after anastomotic leakage and esophageal stent placement (aortic pressure and local inflammation) [3]
 - ▶ after anastomotic stenosis and stent placement (aortic pressure and possible local perforation) [4, 5]
2. Benign esophageal stricture-aortic fistula after stent placement (aortic pressure and possible local perforation) [6]
3. Direct stent perforation-induced aortic fistula
 - ▶ non-migrated stent [7]
 - ▶ migrated stent (the current case).

Siersema et al. reported the first case of an AEF caused by proximal stent perforation in a patient with inoperable squamous-cell carcinoma [7]. A gastric-aortic fistula caused by perforation due to a migrated distal fully covered stent in an esophagectomized patient with a benign anastomotic stenosis has not been reported previously. Direct pressure-related perforation of the gastric wall by a fully covered stent is the possible mechanism in the current case and raises questions about the design of fully covered stents and indications for their use. Radiotherapy and chemotherapy have been described as possible risk factors for developing complications after esophageal stent placement [4]. Further research on this matter is warranted following the recent publication of the CROSS study results [1] and the fact that combined chemoradiotherapy is becoming the gold standard approach for patients with esophageal adenocarcinoma.

Endoscopy_UCTN_Code_CPL_1AH_2AD

Competing interests: None

**E. J. M. van Geenen¹, N. C. M. Visser²,
J. J. Bonenkamp³**

- ¹ Department of Gastroenterology and Hepatology, St. Radboud University Medical Center, Nijmegen, The Netherlands
- ² Department of Pathology, St. Radboud University Medical Center, Nijmegen, The Netherlands
- ³ Department of Surgery, St. Radboud University Medical Center, Nijmegen, The Netherlands

References

- 1 *van Hagen P, Hulshof MC, van Lanschot JJ et al.*, on behalf of the CROSS Group. Preoperative chemoradiotherapy for esophageal or junctional cancer. *N Engl J Med* 2012; 366: 2074–2084
- 2 *Okita R, Mukaida H, Takiyama W et al.* Successful surgical treatment of aorto-esophageal fistula after esophagectomy. *Ann Thorac Surg* 2005; 79: 1059–1061
- 3 *Byard RW.* Lethal aorto-oesophageal fistula – characteristic features and aetiology. *J Forensic Leg Med* 2013; 20: 164–168
- 4 *Rogart J, Greenwald A, Rossi F et al.* Aorto-esophageal fistula following Polyflex stent placement for refractory benign esophageal stricture. *Endoscopy* 2007; 39 (Suppl. 01): E321–322
- 5 *Schweigert M, Dubecz A, Stadlhuber RJ et al.* Risk of stentrelated aortic erosion after endoscopic stent insertion for intrathoracic anastomotic leaks after esophagectomy. *Ann Thorac Surg* 2011; 92: 513–518
- 6 *Unosawa S, Hata M, Sezai A et al.* Surgical treatment of an aorto-esophageal fistula caused by stent implantation for esophageal stenosis: report of a case. *Surg Today* 2008; 38: 62–64
- 7 *Siersema PD, Tan TG, Sutorius FF et al.* Massive hemorrhage caused by a perforating Gianturco-Z stent resulting in an aorto-esophageal fistula. *Endoscopy* 1997; 29: 416–420

Bibliography

DOI <http://dx.doi.org/10.1055/s-0033-1344561>
Endoscopy 2014; 46: E16–E17
 © Georg Thieme Verlag KG
 Stuttgart · New York
 ISSN 0013-726X

Corresponding author

E. J. M. van Geenen, MD
 Department of Gastroenterology and Hepatology
 St. Radboud University Medical Center
 Geert Grooteplein-Zuid 22
 Nijmegen
 Gelderland 6525 GA
 The Netherlands
 Fax: +31-24-3540103
 e.vangeenen@mdl.umcn.nl