

Radiologic imaging of over-the-scope-clips can be misunderstood: the “pooling sign”

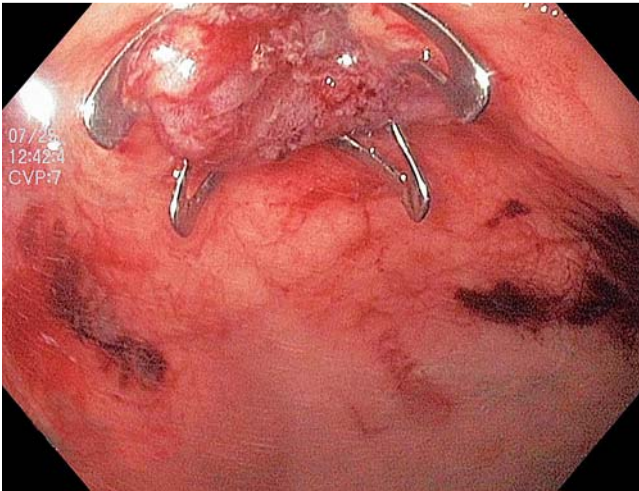


Fig. 1 Endoscopic image of an over-the-scope clip deployed in the gastric fundus. The “cup-like” conformation of the clip is clear.

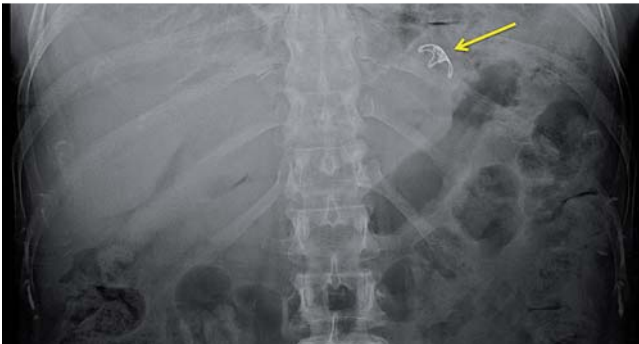

Fig. 2 The scout film demonstrated the “cup-like” formation of the over-the-scope clip (yellow arrow), which was deployed in the gastric fundus after full-thickness endoscopic resection of a gastric gastrointestinal stromal tumor.

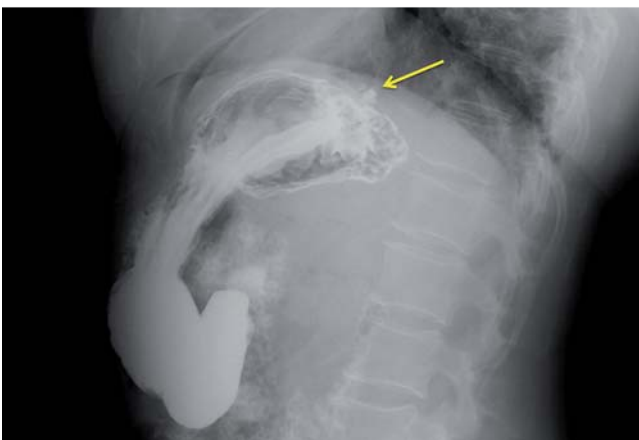


Fig. 3 The cross-table lateral view on upper gastrointestinal series demonstrates the contrast pooling in the “cup” of the over-the-scope clip, which was reported as a contained perforation.

The conventional treatment of gastrointestinal defects, including perforations, fistulas, and anastomotic leaks, is surgery, which is associated with significant morbidity and mortality [1–6]. The over-the-scope clip (OTSC) (Ovesco Endoscopy AG, Tübingen, Germany) conforms to the shape of a cup after deployment (▶ Fig. 1 and ▶ Fig. 2) and provides more durable closure than standard clips because of its

wider mouth and its ability to grasp larger amounts of tissue. Due to limited worldwide experience, radiologists may not be aware of its size and shape. We describe four cases in which the contrast pooling within the “cup” was misinterpreted as contained perforation.

Two patients underwent peroral endoscopic myotomy (POEM) for treatment of achalasia. The mucosal entry was closed

using an OTSC. The patients were asymptomatic on day 1 post-procedure. Findings on routine cine esophagrams were reported as contained perforation. In case 1, a computed tomography (CT) scan with oral contrast revealed limited and clinically insignificant pneumomediastinum (as expected on day 1 post-POEM) without extravasation of contrast. In case 2, the cine esophagram was reviewed again, and confirmed the lack of contrast extravasation. In both cases, commencement of diet was deferred leading to delayed discharge.

A 28-year-old man with severe, refractory gastroparesis underwent treatment by placement of a transpyloric fully covered self-expandable metal stent [7]. The stent was clipped to the gastric antrum with one OTSC to prevent migration. He presented to his local hospital 2 days post-procedure with abdominal discomfort, although he was afebrile and had a non-tender abdomen. Clinically, the patient’s pain was likely due to stent expansion. Abdominal CT with oral contrast revealed an irregular collection of contrast alongside the stent, which was misinterpreted as localized perforation. The patient was transferred to our institution where the CT scan was repeated, with similar findings reported. The patient was admitted. Images reviewed the following day confirmed the “pooling sign.”

A 60-year-old woman underwent full-thickness resection of a 1.4-cm gastric gastrointestinal stromal tumor. The gastrostomy site was closed using one OTSC. Upper gastrointestinal series was obtained to ensure absence of leak. A pool of contrast in the gastric fundus was reported as contained perforation (▶ Fig. 3). The patient remained clinically well and was kept fasted until the imaging study was reviewed again, confirming the pooling sign. Discharge was delayed to 2 days after admission.

In each case, contrast pooling within the “cup” of the OTSC was mistaken for contained perforation and a cascade of further investigations including additional imaging studies and prolonged hospitalization (and therefore additional cost) ensued, all of which could have been avoided if endoscopists and radiologists had been aware of this potential occurrence. Clear communication is critical in facilitating a good understanding of the procedure and devices used.

Endoscopy_UCTN_Code_TTT_1AO_2AI

Competing interests: None

**P. Saxena¹, D. Abdollahian²,
A. Kompel², V. K. Singh¹,
A. M. Lennon¹, M. A. Khashab¹**

¹ Department of Medicine and Division of Gastroenterology and Hepatology, The Johns Hopkins Medical Institutions, Baltimore, Maryland, USA

² Department of Radiology, The Johns Hopkins Medical Institutions, Baltimore, Maryland, USA

References

- 1 Voermans RP, Le Moine O, von Renteln D et al. Efficacy of endoscopic closure of acute perforations of the gastrointestinal tract. *Clin Gastroenterol Hepatol* 2012; 10: 603–608
- 2 Cobb WS, Heniford BT, Sigmon LB et al. Colonoscopic perforations: incidence, management, and outcomes. *Am Surg* 2004; 70: 750–758
- 3 Fernandez FF, Richter A, Freudenberg S et al. Treatment of endoscopic esophageal perforation. *Surg Endosc* 1999; 13: 962–966
- 4 Iqbal CW, Cullinane DC, Schiller HJ et al. Surgical management and outcomes of 165 colonoscopic perforations from a single institution. *Arch Surg* 2008; 143: 701–707
- 5 Luning TH, Keemers-Gels ME, Barendregt WB et al. Colonoscopic perforations: a review of 30,366 patients. *Surg Endosc* 2007; 21: 994–997
- 6 Stapfer M, Selby RR, Stain SC et al. Management of duodenal perforation after endoscopic retrograde cholangiopancreatography and sphincterotomy. *Ann Surg* 2000; 232: 191–198
- 7 Clarke JO, Sharaiha RZ, Valeshabad AK et al. Through the scope trans-pyloric stent placement improves symptoms and gastric emptying in patients with gastroparesis. *Endoscopy* 2013: In press

Bibliography

DOI <http://dx.doi.org/10.1055/s-0033-1344563>
Endoscopy 2013; 45: E305–E306
© Georg Thieme Verlag KG
Stuttgart · New York
ISSN 0013-726X

Corresponding author

M. A. Khashab, MD
Director of Therapeutic Endoscopy
Johns Hopkins Hospital
1800 Orleans St., Suite 7125B
Baltimore
MD 21287
USA
Fax: +1-443-683-8335
mkhasha1@jhmi.edu