Endoscopic detorsion for sigmoid volvulus using unsedated water-immersion colonoscopy

We report a simple method of endoscopic detorsion for sigmoid volvulus using unsedated water-immersion colonoscopy, which we currently use in the majority of our cases.

Importantly, volvulus detorsion with a colonoscope should be attempted only in patients with an absence of necrotic findings. Endoscopic detorsion is performed without fluoroscopic guidance. A cap or hood attached to the tip of the colonoscope, which maintains a distance between the instrument and the colonic wall, so keeping the luminal direction in view, is used to aid insertion [1]. The water-immersion method involves water infusion in lieu of air insufflation as the principal modality to decrease pain during insertion of the colonoscope [2–4]. Water is infused into the rectum through the biopsy port of the scope using two 50-mL disposable syringes or intermittently infused using a water-jet system. Removal of residual luminal air diminishes the boundary and improves the view. Water accumulates around the tip of the colonoscope and collapses the colon as previously described [2,4].

The colonoscope is inserted with a twisting motion, according to the torsion of the sigmoid colon, and is typically passed under direct observation through the normal-caliber colon to the point of obstruction. This point classically appears as a termination of the lumen in a "whirl sign" [5]. Care needs to be taken to avoid air insufflation while gently attempting to pass the scope through the twisted segment (▶ **Fig. 1 a**). If this process is successful, the distended proximal segment (▶ **Fig. 1 b**) is decompressed using endoscopic suction, which often results in spontaneous detorsion. When liquid or soft stools flow out, the success of endoscopic detorsion is confirmed.

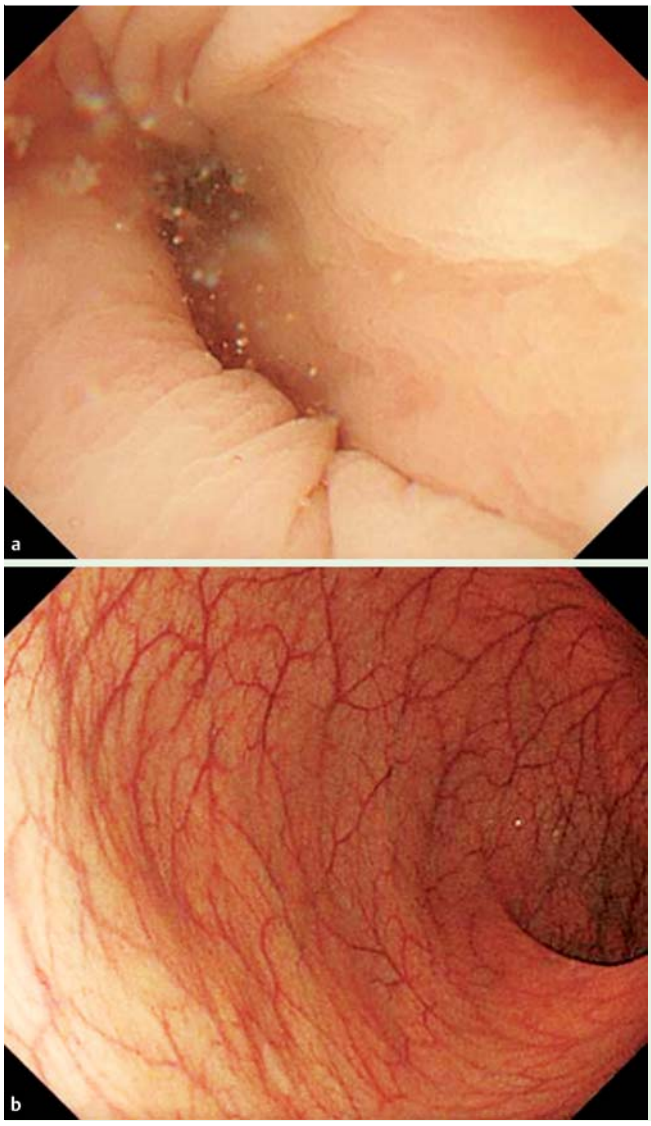

Fig. 1 Endoscopic appearances of a sigmoid volvulus showing: **a** the mucosa at the point of twisting; **b** the dilated lumen in the twisted segment of sigmoid colon.

In our experience the success rate of this treatment has been 100%, therefore we believe an endoscopic detorsion is a reasonable treatment for elderly patients with sigmoid volvulus.

Endoscopy_UCTN_Code_TTT_1AQ_2AJ

Competing interests: None

S. Sugimoto[1,2], T. Mizukami[3], T. Ito[1], Y. Tsunoda[1], S. Imamura[1], T. Tamura[1], S. Nagakubo[1], Y. Morohoshi[1], Y. Koike[1], Y. Fujita[1], H. Komatsu[1]

[1] Department of Gastroenterology, Yokohama Municipal Citizens' Hospital, Yokohama, Japan
[2] Division of Gastroenterology and Hepatology, Department of Internal Medicine, School of Medicine, Keio University, Tokyo, Japan
[3] Endoscopy Center, NHO Kurihama Medical and Addiction Center, Yokosuka, Japan

References

1 *Kondo S*, *Yamaji Y*, *Watabe H* et al. A randomized controlled trial evaluating the usefulness of a transparent hood attached to the tip of the colonoscope. Am J Gastroenterol 2007; 102: 75 – 81
2 *Mizukami T*, *Hibi T*. How I teach my trainees "water navigation colonoscopy". Am J Clin Med 2010; 7: 144 – 146
3 *Leung FW*, *Amato A*, *Ell C* et al. Water-aided colonoscopy: a systematic review. Gastrointest Endosc 2012; 76: 657 – 666
4 *Mizukami T*, *Yokoyama A*, *Imaeda H* et al. Collapse-submergence method: simple colonoscopic technique combining water infusion with complete air removal from the rectosigmoid colon. Dig Endosc 2007; 19: 43 – 47
5 *Sugimoto S*, *Mizukami T*, *Morohoshi Y* et al. Sigmoid volvulus associated with Chilaiditi's syndrome. Intern Med 2013; 52: 515 – 516

Bibliography
DOI http://dx.doi.org/10.1055/s-0033-1344567
Endoscopy 2013; 45: E263–E264

ISSN 0013-726X

Corresponding author
S. Sugimoto, MD
Division of Gastroenterology and Hepatology
Department of Internal Medicine
School of Medicine, Keio University
35 Shinanomachi, Shinjuku-ku
Tokyo 160-8582
Japan
Fax: +81-3-3353-6247
sugimoto-kei@umin.ac.jp