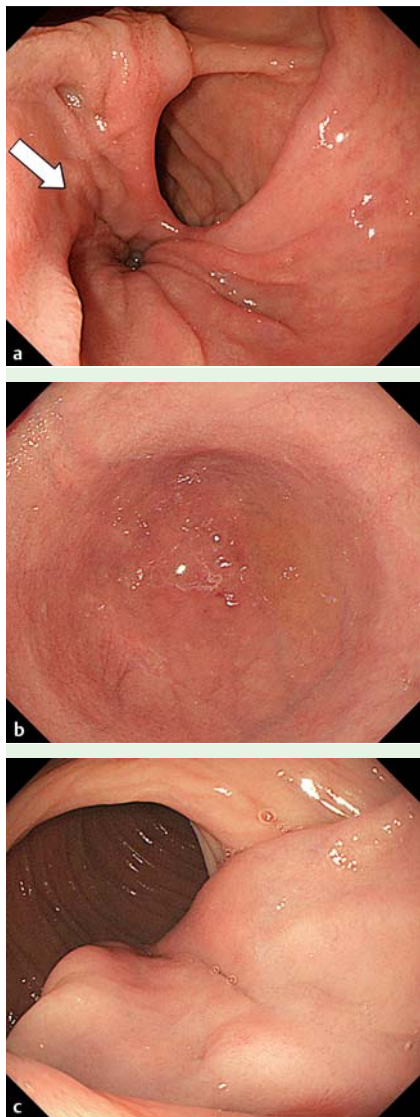
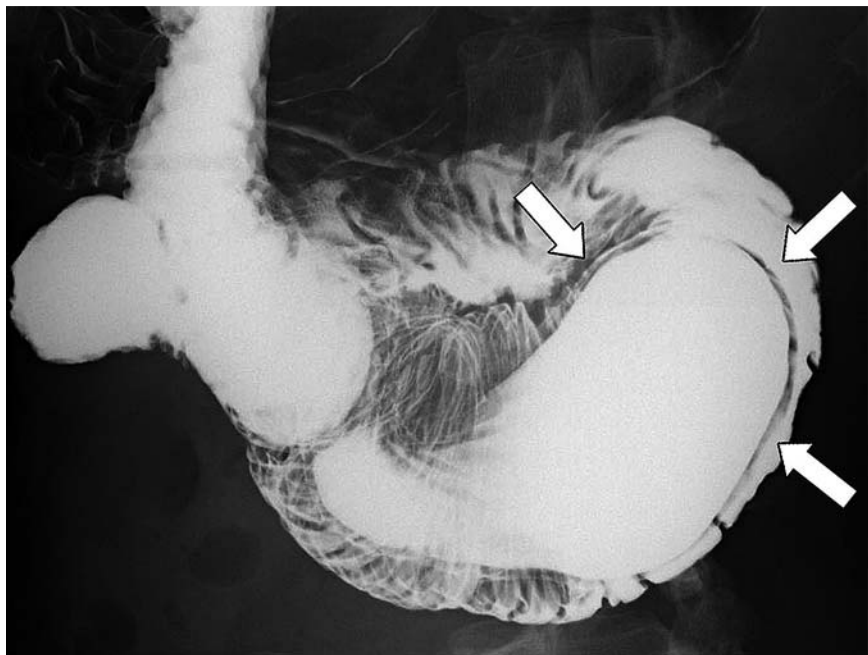


## Intraluminal duodenal diverticulum treated with an endoscopic procedure



**Fig. 1** Endoscopic findings. **a** Esophagogastroduodenoscopy showing a double lumen at the inferior duodenal flexure: one is a true lumen, and the other is an intraluminal duodenal diverticulum (IDD) (arrow). **b** The IDD has a blind end. **c** The IDD was identified in the third portion of the duodenum as a soft-tissue mass covered by normal-appearing mucosa.

A 20-year-old woman was referred to our hospital for recurrent postprandial epigastric pain and vomiting. Physical examination revealed no abdominal mass, and laboratory data were within normal limits except for slight elevation of serum amylase (301 U/l). Esophagogastroduodenoscopy identified double duodenal lumens at the inferior duodenal flexure



**Fig. 2** Barium examination depicting a barium-filled sac surrounded by a narrow radiolucent line, the "windsock sign."

(**Fig. 1 a**). One lumen was discovered to lead into a blind sac (**Fig. 1 b**), which was identified as a soft tissue mass in the third portion of the duodenum, covered by normal-appearing duodenal mucosa (**Fig. 1 c**). In a double contrast study of the small intestine, the blind sac was noted to be surrounded by a narrow radiolucent line, the so-called "windsock sign" (**Fig. 2**). We thus diagnosed the patient as having a pocket-type intraluminal duodenal diverticulum (IDD) [1]. Considering the patient's recurrent abdominal symptoms, we treated her condition with an endoscopic canalization technique using the two-channel method; the bottom of the IDD was externally held with grasping forceps from the true lumen and was resected by snaring with electrocautery without any complication (**Fig. 3**). Histologically, both surfaces of the resected specimen were covered by normal duodenal mucosa (**Fig. 4**). Although IDD is generally treated surgically [2], therapeutic endoscopy has been increasingly applied [3]. Two types of therapeutic endoscopy using snare or needle devices for endoscopic submucosal dissection and endoscopic injection sclero-

therapy have been reported so far [3–7]. However, incision of IDD using needle devices may carry a risk of duodenal perforation and internal excision by snaring requires inversion of the diverticular wall. Because external canalization using the two-channel method enables keeping the IDD away from the duodenal wall, this procedure seems preferable for the treatment of pocket-type IDD.

Endoscopy\_UCTN\_Code\_CCL\_1AB\_2AZ\_3AZ

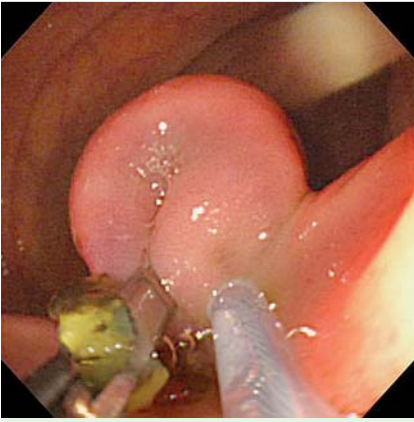
**Competing interests:** None

**K. Yamaguchi<sup>1</sup>, T. Moriyama<sup>1</sup>, M. Esaki<sup>1</sup>, M. Gushima<sup>2</sup>, S. Ayabe<sup>3</sup>, S. Nakamura<sup>1</sup>, T. Kitazono<sup>1</sup>, T. Matsumoto<sup>1</sup>**

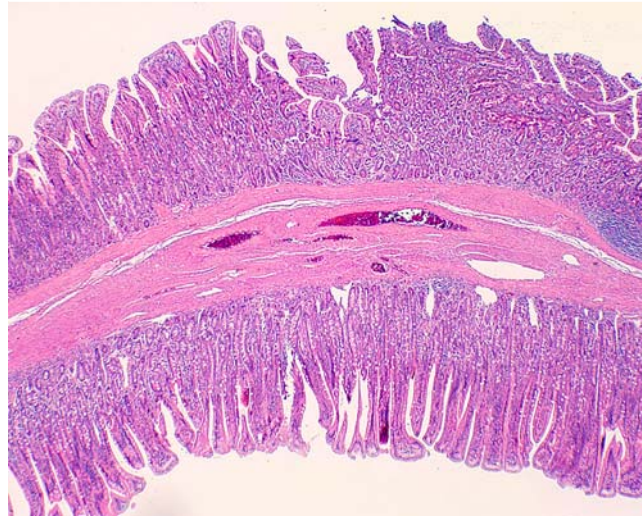
<sup>1</sup> Department of Medicine and Clinical Science, Graduate School of Medical Sciences, Kyushu University, Fukuoka, Japan

<sup>2</sup> Department of Anatomic Pathology, Graduate School of Medical Sciences, Kyushu University, Fukuoka, Japan

<sup>3</sup> Division of Gastroenterology, Chihaya Hospital, Fukuoka, Japan



**Fig. 3** External canalization technique: the floor of IDD is externally held with grasping forceps from the true lumen and is resected by snaring with electrocautery.



**Fig. 4** Histologic section showed both surfaces of the specimen covered by normal duodenal mucosa, including the muscularis mucosa. A thin layer of smooth muscle is present between the two mucosal layers.

## References

- 1 Griffin M, Carey WD, Hermann R et al. Recurrent acute pancreatitis and intussusception complicating an intraluminal duodenal diverticulum. *Gastroenterology* 1981; 81: 345–348
- 2 Meinke AK, Meighan DM, Meinke ME et al. Intraluminal duodenal diverticula: collective review with report of a laparoscopic excision. *J Laparoendosc Adv Surg Tech A* 2013; 23: 129–136
- 3 Law R, Topazian M, Baron TH. Endoscopic treatment of intraluminal duodenal (“wind-sock”) diverticulum: varying techniques from five cases. *Endoscopy* 2012; 44: 1161–1164
- 4 Hajiro K, Yamamoto H, Matsui H et al. Endoscopic diagnosis and excision of intraluminal duodenal diverticulum. *Gastrointest Endosc* 1979; 25: 151–154
- 5 Ravi J, Joson PM, Ashok PS. Endoscopic incision of intraluminal duodenal diverticulum. Case report of a new technique. *Dig Dis Sci* 1993; 38: 762–766
- 6 Badaoui A, Piessevaux H. A new endoscopic therapy for an intraluminal diverticulum of the duodenum. *Endoscopy* 2007; 39 (Suppl. 01): E99–100
- 7 Van Os EC, Petersen BT, Kelly DG et al. Endoscopic management of an intraluminal duodenal diverticulum. *Gastrointest Endosc* 1996; 44: 494–497

## Bibliography

**DOI** <http://dx.doi.org/10.1055/s-0033-1344586>  
*Endoscopy* 2013; 45: E322–E323  
 © Georg Thieme Verlag KG  
 Stuttgart · New York  
 ISSN 0013-726X

## Corresponding author

**K. Yamaguchi, MD**

Department of Medicine and Clinical Science  
 Graduate School of Medical Sciences  
 Kyushu University  
 Fukuoka  
 Japan  
 Fax: +81-92-6425273  
[yamakan723@msn.com](mailto:yamakan723@msn.com)