Jejunal post-polypectomy syndrome

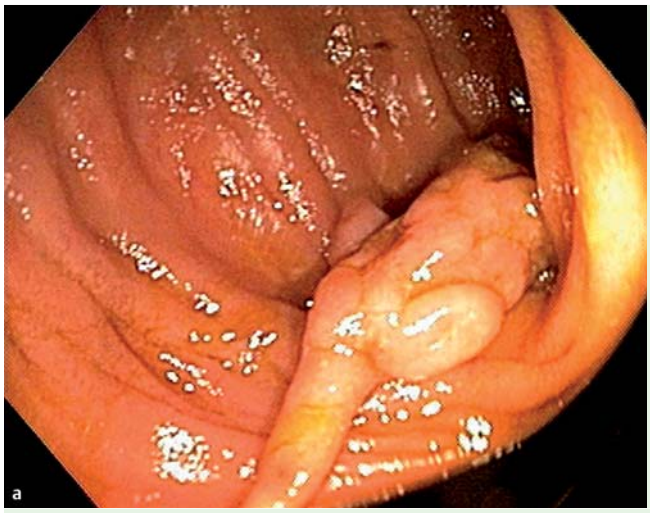

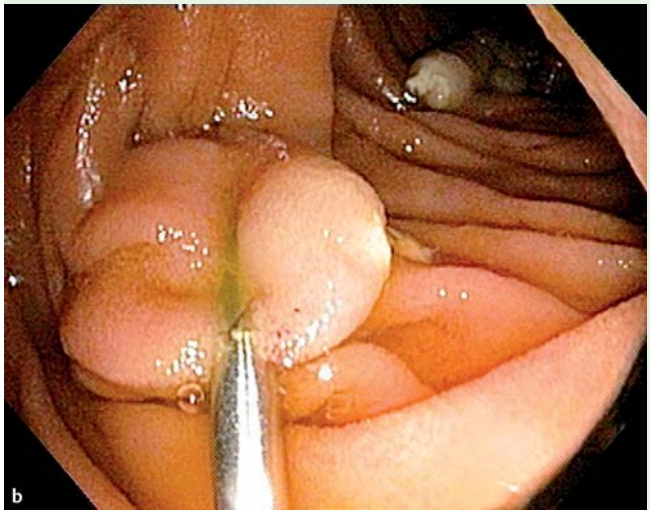

Fig. 1 **a** Pedunculated polyp in the proximal jejunum of a 65-year-old woman with a long-standing history of obscure gastrointestinal bleeding and anemia who was found to have active bleeding in the jejunum on capsule endoscopy. **b** The excised polyp.

A 65-year-old woman, with a longstanding history of obscure gastrointestinal bleeding and anemia, and following unrevealing upper endoscopy, push enteroscopy, and colonoscopy, was found to have active bleeding in the jejunum on capsule endoscopy. Anterograde double-balloon enteroscopy revealed a large 2-cm pedunculated polyp in the proximal jejunum (**Fig. 1 a**), which was resected using a hot snare. Additionally, the site was marked by injection of SPOT tattoo ink and the polypectomy site was closed using a Resolution clip (Boston Scientific, Natick, Massachusetts, USA) (**Fig. 1 b**). There were no immediate post-procedural complications and the patient was discharged.

Several hours later, the patient developed severe, sharp, diffuse abdominal pain associated with nausea, nonbilious emesis, fever, and chills, and she was seen in the emergency room the next day. On physical examination, she was found to have rebound tenderness to palpation in the left lower quadrant. Laboratory studies were significant for leukocytosis and a white blood cell count of $15.9 \times 10^3/mm^3$, consisting of 86% neutrophils. Liver function tests showed no abnormalities and her serum lipase level was found to be within normal limits. An abdominal computed tomography scan showed normal findings and ruled out possible perforation or pancreatitis secondary to the procedure. Thus, a diagnosis of post-polypectomy syndrome was made. The patient was started on intravenous broad-spectrum antibiotics along with intravenous fluids and bowel rest. Her symptoms improved and she was discharged. The excised polyp was found to be a Peutz-Jegher polyp on pathologic examination.

Post-polypectomy syndrome is a well-established complication after colonoscopy in which a polyp is removed by electrocoagulation. The syndrome is characterized by the development of abdominal pain, fever, leukocytosis, and peritoneal symptoms following the procedure [1]. It is thought that syndrome occurs due to extension of a transmural burn past the mucosa into the muscularis mucosa and serosa, leading to peritoneal inflammation in the absence of overt bowel perforation [2]. Risk factors that increase the likelihood of developing post-polypectomy syndrome include hypertension, large size of polyp, and nonpolypoid configuration of lesions [1]. Treatment of post-polypectomy syndrome generally consists of antibiotics and supportive care, which includes bowel rest, intravenous fluids, and slow advancement of diet [1]. Patients generally recover well with this treatment and do not display long-term stigmata. Despite extensive literature on colonic post-polypectomy syndrome, the occurrence of this condition in the small intestine has not yet been described in great detail. However, as double-balloon enteroscopy becomes more widely used for small-bowel polyp removal, its incidence will probably increase.

In conclusion, small-bowel post-polypectomy syndrome should be suspected in patients presenting with abdominal pain, fever, and leukocytosis shortly after small-intestinal polyp removal. The management and treatment should consist of early recognition of the syndrome by ruling out other causes of the symptoms along with antibiotics and supportive care, including bowel rest.

Endoscopy_UCTN_Code_CPL_1AI_2AD

Competing interests: None

Abhishek Bhandari[1], Denise Kalmaz[2]

[1] University of California at San Diego, Department of Internal Medicine, San Diego, California, United States of America

[2] University of California at San Diego, Department of Gastroenterology, San Diego, California, United States of America

References

1 *Cha J, Lim K, Lee S* et al. Clinical outcomes and risk factors of post-polypectomy coagulation syndrome: a multicenter, retrospective, case-control study. Endoscopy 2013; 45: 202 – 207

2 *Waye J.* Management of complications of colonoscopic polypectomy. Gastroenterologist 1993; 2: 158 – 164

Bibliography

DOI http://dx.doi.org/10.1055/s-0033-1344955
Endoscopy 2014; 46: E133–E134

ISSN 0013-726X

Corresponding author

Abhishek Bhandari
200 W. Arbor Dr
Department of Internal Medicine
San Diego
CA 92103
USA
abbhandari@ucsd.edu