Gastric perforation into the pericardium

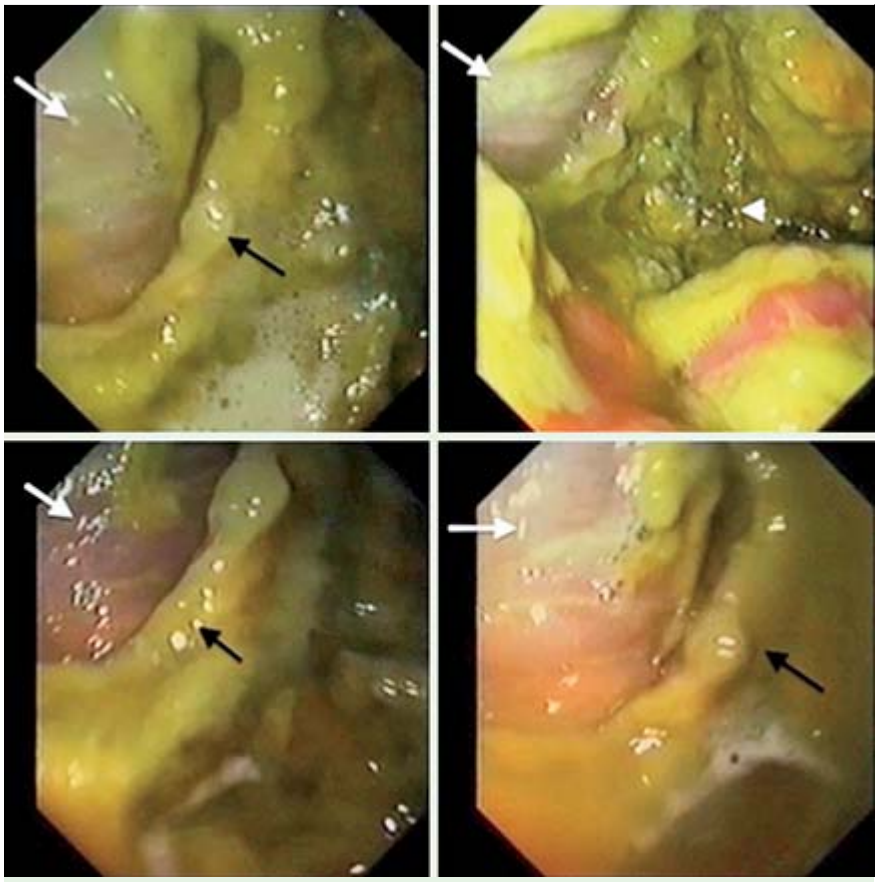

Fig. 1 Perforation at the gastric fundus, with a protruding, pulsatile base (pericardium, white arrow) and free in relation to the borders (black arrow). The surrounding gastric mucosa was invaded by neoplastic tissue (white arrowhead).

A 68-year-old man with a previous history of partial gastrectomy (Billroth II) for an unknown indication, was admitted as an emergency case to our hospital following several hours of epigastric pain. He had suffered weight loss and anorexia for about 4 days, without hematemesis or melena. The physical examination findings were normal except for leg edema. Pulse rate was 118 bpm and blood pressure was 101/63 mmHg. Laboratory findings were normal (hemoglobin 11.7 g/dL). Nothing abnormal was observed on chest radiography. Endoscopy revealed a large perforated area at the gastric fundus, with a protruding and strongly pulsatile base, which was mobile and free in relation to the borders (**Fig. 1**, **Video 1**). Endoscopic findings suggested gastric perforation into the pericardium, and surgery was decided.

At surgery, the gastric mucosa was found to be invaded by neoplastic tissue, with the fundus adherent to the diaphragm, invasion of the pericardium, and protrusion of the cardiac tip into the gastric cavity. Total gastrectomy was carried out. Histopathology of the surgical specimen showed adenocarcinoma, which was poorly differentiated and showed subserosal invasion and lymph node metastasis.

Perforation into the heart or pericardium is described as a rare peptic ulcer complication [1–3]. Gastric perforation should raise suspicions of malignancy, particularly in elderly patients [2]. This complication usually occurs in advanced stages of gastric cancer; nevertheless this does not contraindicate radical surgical treatment [3]. Cardiac involvement determines the mode of presentation and clinical course. In most instances, gastric carcinoma is not suspected as the cause of perforation prior to emergency laparotomy, and the diagnosis of malignancy is often only made on postoperative pathology examination [4]. The clinical case described here is illustrated by a rare endoscopic image which, although not useful for treatment, provided endoscopic findings suggesting a perforation into the pericardium and allowed early diagnosis and guidance.

Video 1

Upper gastrointestinal endoscopy showing gastric mucosa invaded by neoplastic tissue and large perforated area at the gastric fundus, with a protruding pulsatile base, suggesting gastric perforation into the pericardium. This was confirmed later at surgery.

Endoscopy_UCTN_Code_CCL_1AB_2AD_3AF

Competing interests: None

Ana Maria Grilo[1], Denise Pinto[1], Margarida Lopes[1], José Reina[1], Paulo Jácome[2], José Vaz[3]

[1] Department of Internal Medicine I, Hospital José Joaquim Fernandes, Beja, Portugal
[2] Department of Surgery, Hospital José Joaquim Fernandes, Beja, Portugal
[3] Intensive Care Unit, Hospital José Joaquim Fernandes, Beja, Portugal

References

1 *Montes Rodriguez JA, Iglesias A, Simal J* et al. Ulcera Gástrica perforada en ventrículo izquierdo. Aportación de un caso y revisión de la literatura. Rev Esp Cardiol 1986; 39: 385–387
2 *Kotan C, Sumer A, Baser M* et al. An analysis of 13 patients with perforated gastric carcinoma: A surgeon's nightmare? World J Emerg Surg 2008; 3: 17
3 *Roviello F, Rossi S, Marrelli D* et al. Perforated gastric carcinoma: a report of 10 cases and review of the literature. World J Surg Oncol 2006; 30: 19
4 *Brullet E, Campo R, Combalia N* et al. Gastric ulcer perforation into the heart. Endoscopy 1996; 28: 316–318

Bibliography

DOI http://dx.doi.org/10.1055/s-0033-1344994
Endoscopy 2014; 46: E72
© Georg Thieme Verlag KG Stuttgart · New York
ISSN 0013-726X

Corresponding author
Ana Maria Grilo, MD
Department of Internal Medicine I
Hospital José Joaquim Fernandes
Rua Dr. António Fernando Covas Lima
Beja 7801-849
Portugal
Fax: +351-284-322747
ana.grilo@gmail.com

This document was downloaded for personal use only. Unauthorized distribution is strictly prohibited.