

Transclival Pseudomeningocele Secondary to Ecchordosis Physaliphora: Case Report and Literature Review

Sakshi Kaul¹ Osaama H. Khan¹ Idara Edem¹ Shelley Lwu¹ Robert Willinsky² Allen Vescan³ Gelareh Zadeh¹

¹Division of Neurosurgery, Toronto Western Hospital, Toronto, Ontario, Canada

²Department of Medical Imaging, Toronto Western Hospital, Toronto, Ontario, Canada

³Department of Otolaryngology, Mount Sinai Hospital, Toronto, Ontario, Canada

Address for correspondence Osaama H. Khan, MD, MSc, Division of Neurosurgery, Toronto Western Hospital, 399 Bathurst St, Toronto, Ontario, M5T 2S8, Canada (e-mail: osaama.h.khan@gmail.com).

J Neurol Surg Rep 2013;74:92–95.

Abstract

Keywords

- ▶ ecchordosis physaliphora
- ▶ clivus defect
- ▶ pseudomeningocele
- ▶ meningitis
- ▶ transsphenoidal endoscopic surgery

We describe a 52-year-old woman who presented with meningitis secondary to a pseudomeningocele within the sphenoid sinus derived from a bony defect in the clivus. The bony defect was radiologically characteristic of an ecchordosis physaliphora (EP). She underwent surgical repair of the defect and had resolution of her symptoms. This case report will discuss the second case of transclival pseudomeningocele in the English literature and present EP as a cause.

Introduction

Nontraumatic transclival true pseudomeningoceles are exceedingly rare. They involve the protrusion of an arachnoid sac containing cerebrospinal fluid (CSF) through a bony defect in the clivus. There is only one other reported case in the English literature of a transclival pseudomeningocele.¹ Similar lesions through the clivus are also rare, and to date there are eight reports in the literature of transclival CSF fistulae and two reports of transclival meningoceles (▶ **Table 1**). Of these cases, only three have demonstrated clear etiology—ecchordosis physaliphora (EP)^{2,3} or chordoma.⁴ EP is a benign notochordal remnant that can present in the intradural space dorsal to the clivus or sacrum.⁵ Although EP is a benign remnant, intradural chordomas are very rare slow-growing tumors arising from EPs that can potentially invade bone.⁶ Radiologically, chordomas would be larger and not cystic in appearance. EPs are not known to invade bone but have been

associated with CSF fistulas in only the two cases mentioned above. This case report demonstrates the radiological appearance of an EP, presents a literature review of presentations in cases with known or unknown etiologies of clival defects, and offers a mechanism of how the EP may have produced the rare finding of transclival pseudomeningocele observed.

Case Report

Clinical History and Presentation

A 52-year-old right-handed female with a past medical history significant for vertigo, temporomandibular joint disorder, and recurrent otitis media over the past 15 years presented with spontaneous bacterial meningitis approximately 8 months prior to her referral. Meningitis was treated with a 6-week course of appropriate intravenous antibiotics tailored to sensitivities from spinal CSF cultures, and she made a full recovery at an outside hospital. One week after

received
April 10, 2013
accepted
April 30, 2013
published online
September 9, 2013

DOI <http://dx.doi.org/10.1055/s-0033-1348956>.
ISSN 2193-6358.

© 2013 Georg Thieme Verlag KG
Stuttgart · New York

License terms



Table 1 Summary of published cases of clivus defect with transclival (pseudo)meningocele or CSF fistula

Authors (Year)	Age, sex	Type of clival protrusion	Signs and symptoms	Other findings
Lockwood et al 1980 ¹¹	63, F	Meningocele into sphenoid	Intermittent CSF rhinorrhea	
Macdonald et al 1990 ³	66, F	CSF fistula into sphenoid, ecchordosis physaliphora	CSF rhinorrhea (worse w/forward bend)	Anosmia
Coiteiro et al 1995 ⁸ —case 1	53, F	CSF fistula into sphenoid	Meningitis, CSF rhinorrhea	Basilar artery observed pulsating through dural defect
Coiteiro et al 1995 ⁸ —case 2	43, M	CSF fistula into sphenoid	Bacterial meningitis, nasal drip, loculated fluid in sphenoid	
Schick et al 1998 ¹⁰	55, F	CSF fistula into sphenoid	Sinusitis, headache	
Ramos et al 2007 ⁹	36, M	CSF fistula	Rhinorrhea, occipital headache, vomiting	Known Marfan syndrome
Akyuz et al 2008 ⁷	36, F	Meningocele into sphenoid	Intermittent CSF rhinorrhea	
Alli et al 2008 ²	52, F	CSF fistula into sphenoid, ecchordosis physaliphora	CSF rhinorrhea	
Ahmad et al 2008 ¹ —case 1	50, M	CSF fistula into sphenoid	Intermittent CSF rhinorrhea bacterial meningitis	
Ahmad et al 2008 ¹ —case 2	56, M	Pseudomeningocele into sphenoid	Intermittent CSF rhinorrhea (worse w/forward bend)	Basilar artery observed pulsating through dural defect
Feng et al 2009 ⁴	62, M	CSF fistula secondary to clival chordoma	CSF rhinorrhea (worse w/URI)	
Present study	52, F	Pseudomeningocele into sphenoid	Meningitis, recurrent otitis media, tinnitus, ear ache	Basilar artery observed pulsating through dural defect

Abbreviations: CSF, cerebrospinal fluid; URI, upper respiratory infection.

List of published cases of clival defects with transclival pseudomeningocele, meningocele, or CSF fistula.

completing treatment, she developed another ear infection and was referred to an otolaryngologist (AV). With the exception of central and peripheral right vestibular dysfunction, the patient was neurologically intact. There was no CSF rhinorrhea or otorrhea. Imaging investigations were obtained and neurosurgery was subsequently consulted to assist with management.

Investigations

The noncontrast head computed tomography (CT) scan showed a well-defined and corticated bony defect in the dorsal wall of the clivus, measuring approximately 6 mm, and a soft tissue mass in the sphenoid sinus (►Fig. 1a, b). Magnetic resonance imaging (MRI) revealed a cystic lesion within the bony defect (►Fig. 1c, d). The cyst was isointense to CSF on T1- and T2-weighted images and did not enhance with gadolinium. The cyst was continuous with a fluid loculation that nearly filled the sphenoid sinus. The appearance and location of the cystic lesion was characteristic of EP, and the fluid loculation was in keeping with that of a pseudomeningocele. The tympanic membranes and scutum were intact. The mastoid air cells were clear, and there was no evidence of eustachian tube blockage.

Surgical Management

Given the history of spontaneous meningitis and the presence of a clival defect with associated pseudomeningocele,

there were concerns for CSF leaks and recurrence of meningitis. Hence, the decision was made to proceed with surgical exploration and repair of the clival defect. To assist with localization of the CSF leak intraoperatively, 5 cc of 10% fluorescein was mixed with 10 cc of CSF and injected intrathecally through a lumbar puncture (LP) and infused slowly for 30 minutes, 3 hours prior to the surgery. Using an endoscopic endonasal approach, the nasopharynx was explored. The sphenoid sinus had no evidence of leakage into the nasal cavity. The sphenoid sinus was entered and drainage of fluorescein-stained CSF through the clival defect was visualized (►Fig. 2a). The sphenoid sinus mucosa was removed and sent for pathological assessment (►Fig. 2b). The underlying 6-mm round defect in the clivus was identified and through it the basilar artery was visible under the arachnoid plane. The bone edges of the clival defect were soft and devoid of any pathology and therefore were not biopsied. There was no associated soft tissue lesions.

A multilayered reconstruction was then performed. The clival defect was repaired with an inlay-onlay Duragen (Integra Neurosciences, Plainsboro, New Jersey, USA) artificial dural substitute (►Fig. 2c) and then covered with a vascularized nasoseptal flap (►Fig. 2d). A balloon-inflated Foley catheter was used to buttress the repair. It was left in place for 3 days postoperatively. A lumbar drain was inserted to decrease the CSF pressure on the repair to facilitate healing.

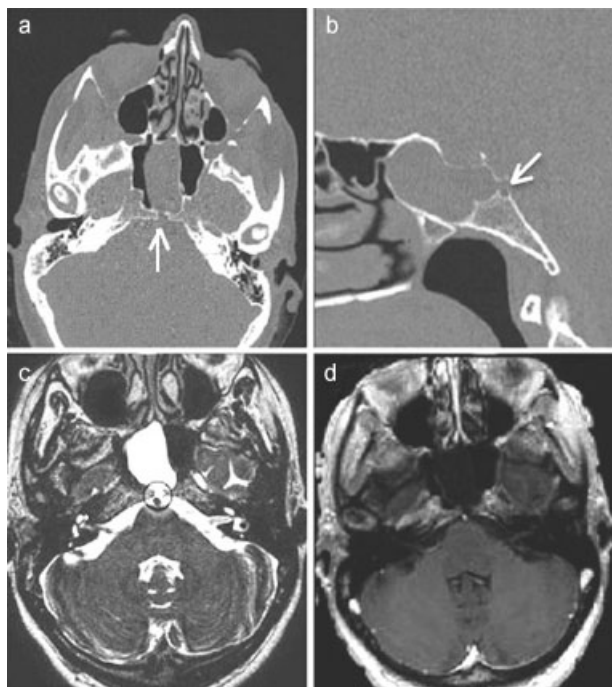


Fig. 1 Radiological imaging. (a) Axial computed tomography (CT) scan revealing defect in clivus bone (arrow). (b) Sagittal CT scan revealing defect in clivus bone (arrow). (c) T2-weighted axial magnetic resonance imaging (MRI) revealing hypointense basilar artery (black circle) directly dorsal to hyperintense cystic lesion characteristic of eckchordosis physaliphora (black circle) and pseudomeningocele in sphenoid sinus. (d) T1-weighted axial MRI with gadolinium enhancement, revealing only enhancement of basilar, and no enhancement of the cystic lesion.

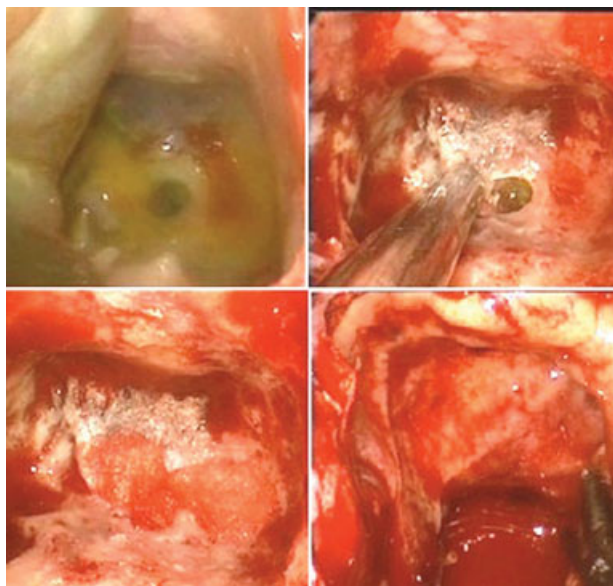


Fig. 2 Intraoperative Images. (a) Clivus defect visible through fluorescein loculation in sphenoid sinus. (b) Clivus defect. (c) Clivus defect repair with inlay-onlay Duragen (Integra Neurosciences, Plainsboro, New Jersey, USA). (d) Placement of septal flap.

A noncontrast head CT done one day after the removal of the lumbar drain revealed scant pneumocephalus with no hydrocephalus. There was still evidence of the presumed EP dorsal to the clival repair. Six weeks postoperatively, the CT

scan showed resolution of the pneumocephalus. The patient reported improvement of vertigo and earache. One year postoperatively the patient continued to be well with no reports of meningitis, otitis media, headache, or vertigo.

Pathological Examination

The wall of the pseudomeningocele was found to contain respiratory mucosa with fragments of bone, dystrophic calcification, and hemosiderin. These findings suggest chronic irritation within the sphenoid sinus.

Discussion

To date there has been only one other case of pseudomeningocele reported through the clivus.¹ Although the transclival pseudomeningocele is a rarely reported lesion, similar lesions through the clivus are also rare. There are a total of eight reports in the literature of transclival CSF fistulae and a total of two reports of transclival meningoceles^{1-4,7-11} (► **Table 1**).

A review of clival embryology and anatomy is well beyond the scope of this paper; however, in brief, the clivus is formed by a combination of the basal part of the occipital bone (basiocciput) and the body of the sphenoid bone (basisphenoid) at the spheno-occipital synchondrosis. Postnatal development of the clivus continues till the age of 11, at which point it reaches its maximal size.¹² The pathophysiology related to the development of a clival bone defect is not very well defined. It is well appreciated that congenital craniofacial syndromes, such as Alpert syndrome and Crouzon syndrome, are occasionally associated with hypoplasia of the clivus.¹³ There are no clear studies reporting the incidence of spontaneous CSF leak in congenital craniofacial syndromes. Ko had recently published a report of a 7-month old infant with a basio-occipital meningocele that was repaired via endoscope and reviews three other cases previously reported.¹⁴ All of the cases were associated with a congenital defect in the clivus.

Previous reports of CSF fistulas, meningoceles, and pseudomeningoceles have largely alluded to increased intracranial pressure or normotensive pressure changes being the primary cause of the development of these conditions. Original papers that discussed the role of pressure changes primarily addressed middle fossa bone defects, such as in the lateral sphenoid,^{15,16} cribriform plate, and sellar floor.¹⁶ In 1979, Kaufman et al¹⁷ proposed that fistulae can occur as the result of enlargement of normally present fenestrations in the middle fossa with repeated variations of intracranial pressure and arterial pulsations. Though conceivable that a similar theory could apply to the clivus, it remains to be proven whether in fact gradual dehiscence of the clival bone can occur as a result of the same mechanism given that the clivus in comparison to the cribriform plate, sellar floor, and lateral sphenoid is a much thicker bone. In our patient, for example, the sella floor and lateral sphenoid bones showed no defects. The defect was only within the thick clivus.

In our opinion the occurrence of bony defect in such a location as the clivus would likely need to involve other contributing factors. Macdonald et al³ and Alli et al² demonstrated transclival CSF fistulas secondary to EP, and Feng et al⁴

demonstrated a transclival CSF fistula secondary to a small intradural chordoma. EP is a benign notochordal remnant that may be found in 0.5 to 2% of autopsies and is typically seen dorsal to the clivus or sacrum.¹⁸ It varies in size from a few millimeters to 2 cm. Radiologically, EP typically appears as a mass attached to the clivus by a stalk, and it appears hypointense on T1-weighted images, hyperintense on T2-weighted images, and does not enhance with gadolinium.^{5,18,19}

If not for a congenital defect, it is difficult to imagine why the thick clivus would contain a well-rounded defect. It may be postulated that the development of the hole in the clivus was due to the combined effect of the EP acting as a pressure point, and the mechanisms described by Kaufman,¹⁷ such as the beating of the basilar artery. In the case of our patient, the basilar artery was visible right underneath the dural defect and in the arachnoid plane. It may also have been possible that the presumed EP remained, blocking the clival defect, while pulsations of the basilar artery upon it also caused dural erosion, which then allowed for arachnoid membrane and CSF to herniate through slowly over time to create the pseudomeningocele. As dystrophic calcification and fragments of bone were apparent on pathology, the pseudomeningocele was likely a source of chronic irritation and the cause of the patient's meningitis. The only other report of a transclival pseudomeningocele was also shown to have the basilar artery pulsating right behind the defect.¹

Conclusions

To our knowledge, this is the first reported case of a transclival pseudomeningocele presenting radiological findings of an EP. This report calls onto increasing the awareness of the possibility of the presence of EP when observing transclival protrusions with spontaneous CSF leaks and/or meningitis, to gain more evidence of the correlation of the congenital defect with such symptomatic findings. Finally, endoscopic transsphenoidal repair is a valid surgical approach for treatment of this condition and its associated symptoms.

Conflict of Interest

None

References

- Ahmad FU, Sharma BS, Garg A, Chandra PS. Primary spontaneous CSF rhinorrhea through the clivus: possible etiopathology. *J Clin Neurosci* 2008;15(11):1304–1308

- Alli A, Clark M, Mansell NJ. Cerebrospinal fluid rhinorrhea secondary to echordosis physaliphora. *Skull Base* 2008;18(6):395–399
- Macdonald RL, Cusimano MD, Deck JH, Gullane PJ, Dolan EJ. Cerebrospinal fluid fistula secondary to echordosis physaliphora. *Neurosurgery* 1990;26(3):515–518, discussion 518–519
- Feng K, Qiuhan Z, Qiuyi Q. Transclival cerebrospinal fluid rhinorrhea as the initial presenting symptom of a tiny intradural chordoma. *J Clin Neurosci* 2010;17(8):1083–1085
- Rotondo M, Natale M, Mirone G, Cirillo M, Conforti R, Scuotto A. A rare symptomatic presentation of echordosis physaliphora: neuroradiological and surgical management. *J Neurol Neurosurg Psychiatry* 2007;78(6):647–649
- Cha ST, Jarrahy R, Yong WH, Eby T, Shahinian HK. A rare symptomatic presentation of echordosis physaliphora and unique endoscope-assisted surgical management. *Minim Invasive Neurosurg* 2002;45(1):36–40
- Akyuz M, Arslan G, Gurkanlar D, Tuncer R. CSF rhinorrhea from a transclival meningocele: a case report. *J Neuroimaging* 2008;18(2):191–193
- Coiteiro D, Távora L, Antunes JL. Spontaneous cerebrospinal fluid fistula through the clivus: report of two cases. *Neurosurgery* 1995;37(4):826–828
- Ramos A, García-Uría J, Ley L, Saucedo G. Transclival cerebrospinal fluid fistula in a patient with Marfan's syndrome. *Acta Neurochir (Wien)* 2007;149(7):723–725, discussion 725
- Schick B, Brors D, Goedecke A, Prescher A, Draf W. Detection of an occult transclival cerebrospinal fluid fistula by CT and MRI. *Neuroradiology* 1998;40(12):797–799
- Lockwood AH, Quencer RM, Page LK. CSF rhinorrhea from a transclival meningocele demonstrated with metrizamide CT cisternography. Case report. *J Neurosurg* 1980;53(4):553–555
- Krmpotić-Nemanić J, Vinter I, Kelovizć Z, Marusić A. Postnatal changes of the clivus. *Ann Anat* 2005;187(3):277–280
- Tokumaru AM, Barkovich AJ, Ciricillo SF, Edwards MS. Skull base and calvarial deformities: association with intracranial changes in craniofacial syndromes. *AJNR Am J Neuroradiol* 1996;17(4):619–630
- Ko AL, Gabikian P, Perkins JA, Gruber DP, Avellino AM. Endoscopic repair of a rare basioccipital meningocele associated with recurrent meningitis. *J Neurosurg Pediatr* 2010;6(2):188–192
- Morley TP, Wortzman G. The importance of the lateral extensions of the sphenoidal sinus in post-traumatic cerebrospinal rhinorrhoea and meningitis: clinical and radiological aspects. *J Neurosurg* 1965;22:326–332
- Ommaya AK, Di Chiro G, Baldwin M, Pennybacker JB. Non-traumatic cerebrospinal fluid rhinorrhoea. *J Neurol Neurosurg Psychiatry* 1968;31(3):214–225
- Kaufman B, Yonas H, White RJ, Miller CF II. Acquired middle cranial fossa fistulas: normal pressure and nontraumatic in origin. *Neurosurgery* 1979;5(4):466–472
- Mehnert F, Beschorner R, Küker W, Hahn U, Nägele T. Retroclival echordosis physaliphora: MR imaging and review of the literature. *AJNR Am J Neuroradiol* 2004;25(10):1851–1855
- Toda H, Kondo A, Iwasaki K. Neuroradiological characteristics of echordosis physaliphora. Case report and review of the literature. *J Neurosurg* 1998;89(5):830–834