

Cervical Detachment Using Monopolar SupraLoop™ Electrode versus Monopolar Needle in Laparoscopic Supracervical Hysterectomy (LSH): An Interventional, Comparative Cohort Study

Durchtrennung der Zervix mit der monopolaren SupraLoop™ Elektrode verglichen mit der monopolaren Nadelelektrode bei der laparoskopischen suprazervikalen Hysterektomie: Eine interventionelle Kohortenstudie

Authors

S. Brucker^{1*}, R. Rothmund^{1*}, B. Krämer¹, F. Neis¹, B. Schönfisch¹, W. Zubke¹, F. A. Taran¹, M. Wallwiener²

Affiliations

¹ Women's Clinic, University Tübingen, Tübingen

² Women's Clinic Heidelberg, University Heidelberg, Heidelberg

Key words

- hysterectomy
- laparoscopy
- SupraLoop™
- LASH
- LSH

Schlüsselwörter

- Hysterektomie
- Laparoskopie
- SupraLoop™
- LASH
- LSH

received 6.5.2013
revised 12.9.2013
accepted 7.10.2013

Bibliography

DOI <http://dx.doi.org/10.1055/s-0033-1350975>
Geburtsh Frauenheilk 2013; 73:
1121–1127 © Georg Thieme
Verlag KG Stuttgart · New York ·
ISSN 0016-5751

Correspondence

Dr. Florin Andrei Taran
University Tübingen
Women's Clinic
Calwerstraße 7
72076 Tübingen
florin.andrei.taran@gmail.com

Abstract

Objective: Currently available monopolar loop electrodes are difficult to handle in laparoscopic supracervical hysterectomy (LSH) and are entirely disposable devices, generating additional operating costs. The aim of this interventional study was the comparison of the efficiency and safety of cervical detachment with a newly developed monopolar loop electrode (SupraLoop™) with a conventional method of cervical detachment in LSH.

Material and Methods: Our study sample included 1598 patients; 1070 patients that underwent LSH with cervical detachment using the monopolar SupraLoop™ (study group) and 528 patients that underwent LSH with cervical detachment using the monopolar needle (control group). We also assessed cervical detachment time and total device application and cutting time in a subgroup of 49 patients (23 patients from the study group and 26 patients from the control group).

Results: Total operation time for LSH was significantly shorter among SupraLoop™ patients (93 ± 41 minutes) when compared to patients in whom cervical detachment was performed with the needle (105 ± 44 minutes) ($p < 0.001$). Cervical detachment time and total device application including cutting time was significantly shorter for the SupraLoop™ group (SupraLoop vs. needle; 0.12 ± 0.21 min vs. 5.1 ± 4.4 min [$p < 0.001$]; 2.3 ± 1.8 min vs. 5.4 ± 2.4 min [$p < 0.001$]). There were no major or minor complications directly related to the use of the SupraLoop™ device, whereas two intraoperative complications were directly related to the application of the monopolar needle.

* These authors contributed equally to this work.

Zusammenfassung

Ziel: Viele der derzeit verfügbaren monopolaren Loop-Elektroden für die laparoskopische suprazervikale Hysterektomie (LSH) sind schwierig zu handhaben und sind Einwegartikel, die dadurch zu einer Erhöhung der Behandlungskosten führen. Das Ziel dieser interventionellen Studie war die Analyse der Effektivität und Sicherheit der Zervixdurchtrennung mittels der neu entwickelten monopolaren Schlingenelektrode (SupraLoop™) mit der konventionellen Methode mit der Nadelelektrode bei der LSH.

Material und Methode: Interventionelle Kohortenstudie. In unsere Studie wurden 1598 Patientinnen eingeschlossen; bei 1070 wurde die Durchtrennung der Zervix bei der LSH mit der monopolaren SupraLoop™ (Studiengruppe) durchgeführt, bei 528 Patientinnen wurde bei der LSH die Zervix mit der monopolaren Nadelelektrode (Kontrollgruppe) durchtrennt. In einer Subgruppe von 49 Patientinnen wurde zudem die Zeit, die zur Durchtrennung der Zervix notwendig war, sowie die gesamte Applikationszeit und die Zervix-Durchtrennungszeit evaluiert (23 Patientinnen der Studiengruppe und 26 Patientinnen der Kontrollgruppe).

Ergebnisse: Die Gesamtoperationszeit der LSH war signifikant kürzer in der SupraLoop™-Gruppe (93 ± 41 min) im Vergleich zur Durchtrennung der Zervix mit der monopolaren Nadelelektrode (105 ± 44 min) ($p < 0,001$). Die Zeit zur Durchtrennung der Zervix, die gesamte Applikationszeit und Zervix-Durchtrennungszeit war signifikant kürzer in der SupraLoop™-Gruppe (SupraLoop vs. Nadel; $0,12 \pm 0,21$ min vs. $5,1 \pm 4,4$ min [$p < 0,001$]; $2,3 \pm 1,8$ min vs. $5,4 \pm 2,4$ min [$p < 0,001$]). Es wurden weder leichte noch schwere Komplikationen in direktem Zusammenhang mit dem Einsatz der SupraLoop™ beobachtet.

Zusammenfassung: Die neue monopolare Schlin-

Conclusion: The newly developed monopolar loop electrode (SupraLoop™) is both an effective and safe instrument for cervical detachment in laparoscopic supracervical hysterectomy, and performed better than the needle, offering a significantly shorter operating time and less complications for the hysterectomy compared to the conventional method.

Introduction

Operative gynecology has continually evolved during the last decades with establishment of laparoscopic procedures in the methodical spectrum of gynecological surgical interventions, especially for the treatment of benign disease [1]. Several trials highlighted the advantages of laparoscopic hysterectomy compared to hysterectomy by laparotomy: less intraoperative bleeding reduced postoperative pain, quicker recovery and better short-term quality of life [2–4].

Additionally, in the absence of specific indications for total laparoscopic hysterectomy (TLH), laparoscopic supracervical hysterectomy (LSH) is a safe procedure and appears to provide greater improvement in short-term postoperative quality of life compared with TLH [5–8]. Moreover, LSH has been shown to have significantly shorter operating times compared with TLH [5]. Recent advances in the electric morcellator technology have lead to additional shortening of operating times for LSH [9].

Cervical detachment in LSH can be performed through various techniques such as monopolar needle, monopolar hook, Harmonic scalpel and bipolar forceps. However, detachment of the cervix with those devices leads to formation of smoke with subsequent line-of-sight obstruction. Additionally, the devices have to be repeatedly readjusted when cutting the cervix. Thus, operating time is increased and there is a higher risk of lesions of adjacent organs (bowel, bladder, ureter) and of an uneven amputation surface of the cervical stump [10].

The development of monopolar loop electrodes lead to a reduction in cervical detachment time and total device application and cutting time for LSH and to a reduction of smoke formation [10, 11]. Nevertheless, the currently available monopolar loop electrodes are difficult to handle when placed around the uterus and are entirely disposable devices, generating additional operating costs. We have therefore developed an easy to handle, monopolar loop electrode for cervical detachment in LSH. Thus, the primary aim of this study was to compare the monopolar SupraLoop™ (Karl Storz GmbH, Tuttlingen, Germany) as an alternative surgical approach to the monopolar needle (Karl Storz GmbH, Tuttlingen, Germany) for cervical detachment in laparoscopic supracervical hysterectomy. Furthermore, we intended to

genelektrode (SupraLoop™) ist sowohl effektiv als auch sicher in der Durchtrennung der Zervix bei der laparoskopischen suprazervikalen Hysterektomie. Sie ist der konventionellen Nadelelektrode überlegen, indem sie schnellere Operationszeiten bei einer niedrigeren Komplikationsrate ermöglicht.

evaluate the handling of the device, as well as intra- and post-operative complications.

Material and Methods

This interventional, comparative cohort study was conducted at the Department of Obstetrics and Gynecology, University Women's Clinic, Tuebingen. The study was approved by the Ethics Committee of the Medical Faculty of the Tuebingen University. The monopolar loop device was developed 2005 together with Karl Storz GmbH, Tuttlingen, Germany, in pilot investigations and was named "SupraLoop™". The SupraLoop™ monopolar device (size 29 cm) consists of a handle with connector pin for monopolar coagulation and cutting, an insulated outer sheath (size 5 mm) and a disposable spare loop and is for use with a normal trocar size of 6 mm. Furthermore, the loop is available in 2 sizes (● Fig. 1). All improvements to the SupraLoop™ device suggested by our group (placement of the trocar for the loop, size of the loop, current modulation: power output and cutting/coagulation effect-level) were incorporated by Karl Storz GmbH. Each improved device was tested in vitro and in vivo. Once satisfied with the results of this implementation phase, the new SupraLoop™ device was then routinely used for cervical detachment. This study compares all patients at our center between January 1, 2003 and March 31, 2010 that underwent LSH for benign uterine disease. After introduction of supracervical hysterectomy at our institution in 2003 all patients underwent cervical detachment using the monopolar needle. After the implementation of the SupraLoop™ monopolar device into clinical routine in 2005, cervical detachment in LSH was performed at our institution using the new device. During the implementation of the SupraLoop™ device into clinical routine, we also assessed the specific cervical detachment time and total device application including cutting time in a subgroup of 49 patients as a proof of principle; in 23 patients the cervix was detached with the SupraLoop™ device, the control group consisted of 26 patients who underwent LSH using the monopolar needle for uterine detachment.

All women included in the study were at least 18 years old and had no further wish to conceive. Further inclusion criteria were a clear



Fig. 1 The SupraLoop™ device is available in two different sizes.

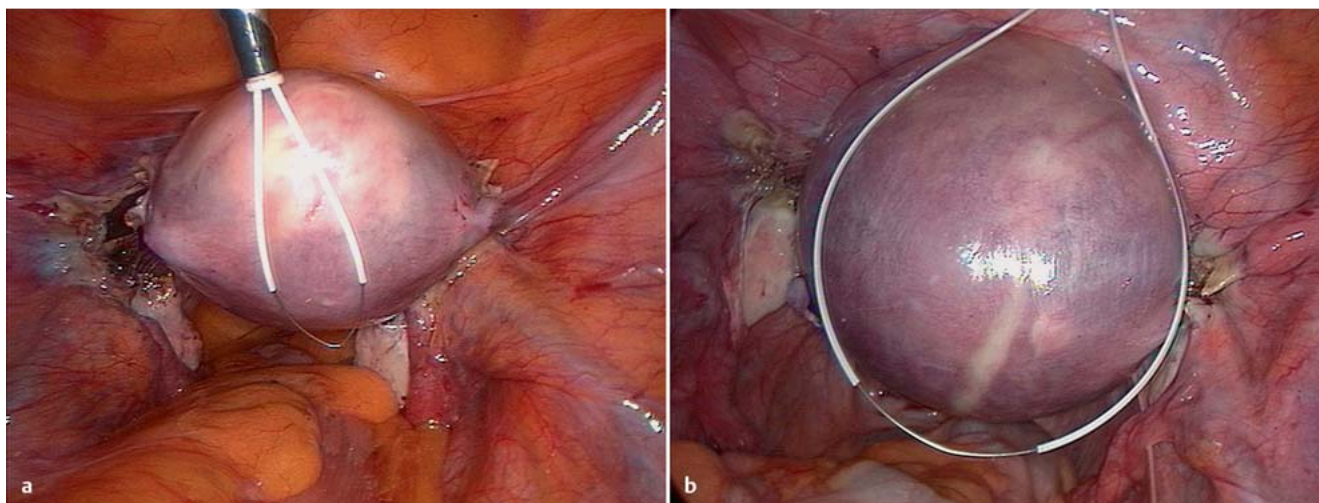


Fig. 2a and b Insertion of the SupraLoop™ (a) and placement around the uterus (b).

indication for LSH for benign gynecologic conditions, a negative Pap smear and/or normal endometrial curettage. Participants needed to agree to a follow-up schedule of annual Pap smears. Presence of gynecologic malignancies on pathologic examination was an exclusion criterion. Thus, our study sample comprised a total of 1598 patients; in 1070 patients the cervix was detached using the monopolar SupraLoop™ device and in 528 patients the cervix was detached using the monopolar needle.

All patients initially included in the study were mailed the questionnaire and a short letter stating the purpose of the mailing. Furthermore, the allocating doctors of the women that did not respond to the questionnaire were contacted in order to provide follow-up information. Thus, a total of 735 patients (69%) from the SupraLoop™ group and 349 patients (66%) from the needle group were included for the analysis of postoperative complications (occurrence ≥ 1 week after surgery).

All patients underwent standard LSH [12]. In brief, the patient was placed in a supine position under general anesthesia. The Tintara uterus manipulator (Karl Storz GmbH, Tuttlingen, Germany; diameter 4–4.8 mm and length 50–80 mm according to uterus size) was introduced into the uterine cervix. After the establishment of a pneumoperitoneum using a Veress needle and the insertion of the trocars, the ongoing operation with one of the instruments followed a standardized procedure: first, transection of the cornual structures of the uterus (adnexa, round ligament) was performed, followed by dissection of the anterior and posterior layers of the broad ligament. The broad ligament was prepared to allow for visualization of the uterine artery and vein. Using the tension of the Tintara manipulator the vesical peritoneum was dissected, resulting in dislocation of the vaginal fornices from the bladder as well as lateralization of the bladder pillars. The next steps were the separation, coagulation and cutting of the uterine artery and vein.

After transection of the cervix at the level of the internal ostium, the SupraLoop™ is inserted into the abdominal cavity through the 6 mm trocar in the suprapubic region (● Fig. 2). Afterwards, the loop is placed around the uterus and locked up around the cervix at the inferior part of the isthmo-cervical passage (● Fig. 2). The position of the SupraLoop™ is checked to guarantee it is snug around the cervix without compressing any adjacent tissue and to ensure the loop is not in contact with any other

structures (bowel, bladder, pelvic side wall) (● Fig. 3). When the monopolar cutting current is applied, the SupraLoop™ is pulled back slicing through the cervix and detaching the uterine corpus from the cervix. Passage of the SupraLoop™ leaves a perfectly plain and hemostatic cut on the cervical stump (● Fig. 4). The VIO 300D (ERBE Elektromedizin GmbH, Tuebingen, Germany) was used as an electrosurgical unit for the SupraLoop™; the following settings provided the best cutting/coagulation ratio: CUT output 180 watt, effect-level 5, HIGH CUT.

Finally, morcellation of the uterus (Unidrive® Gyn with the Roto-cut G1 system, Karl Storz GmbH & Co. KG, Tuttlingen, Germany) after coagulation of the remaining cervical canal (to prevent spotting) and closure of the peritoneum (if the length of the remaining cervix was ≤ 1 cm) was performed. The weight of the uterus was documented.

The study protocol received prior approval from the Ethics Committee of the Medical Faculty of the University of Tübingen. Patient demographic, clinical, and surgical data were prospectively collected and extracted from the hospital records and operative reports for statistical analysis. Following variables were analyzed: age, weight, height, indications for surgery, drop in hemoglobin concentration after surgery (difference between pre- and postoperative values), surgical history, intraoperative (operating time) and pathologic information (uterine weight, histologic diagnosis), as well as intra- and postoperative complications. Cervical detachment time was calculated in minutes; total device application including cutting time was calculated in minutes from device introduction until removal of the device. The operating time was calculated in minutes from skin incision until closure of the laparoscopic ports. Prophylactic antibiotics were administered preoperatively in all hysterectomy cases.

Women in both treatment groups were then followed for six months to ascertain intra-/perioperative complications and postoperative complications. A complication was defined as “intra-/perioperative” if it occurred during or less than one week after the index surgery. Complications that occurred ≥ 1 week after the index surgery were considered to be postoperative complications. Data were collected using an Excel spread sheet (Microsoft, Redmond, Washington, D.C., USA). Statistical analysis and tests were performed with the software R, version 2.12.1 (<http://www.r-project.org/>). We report means and standard deviations (SD)

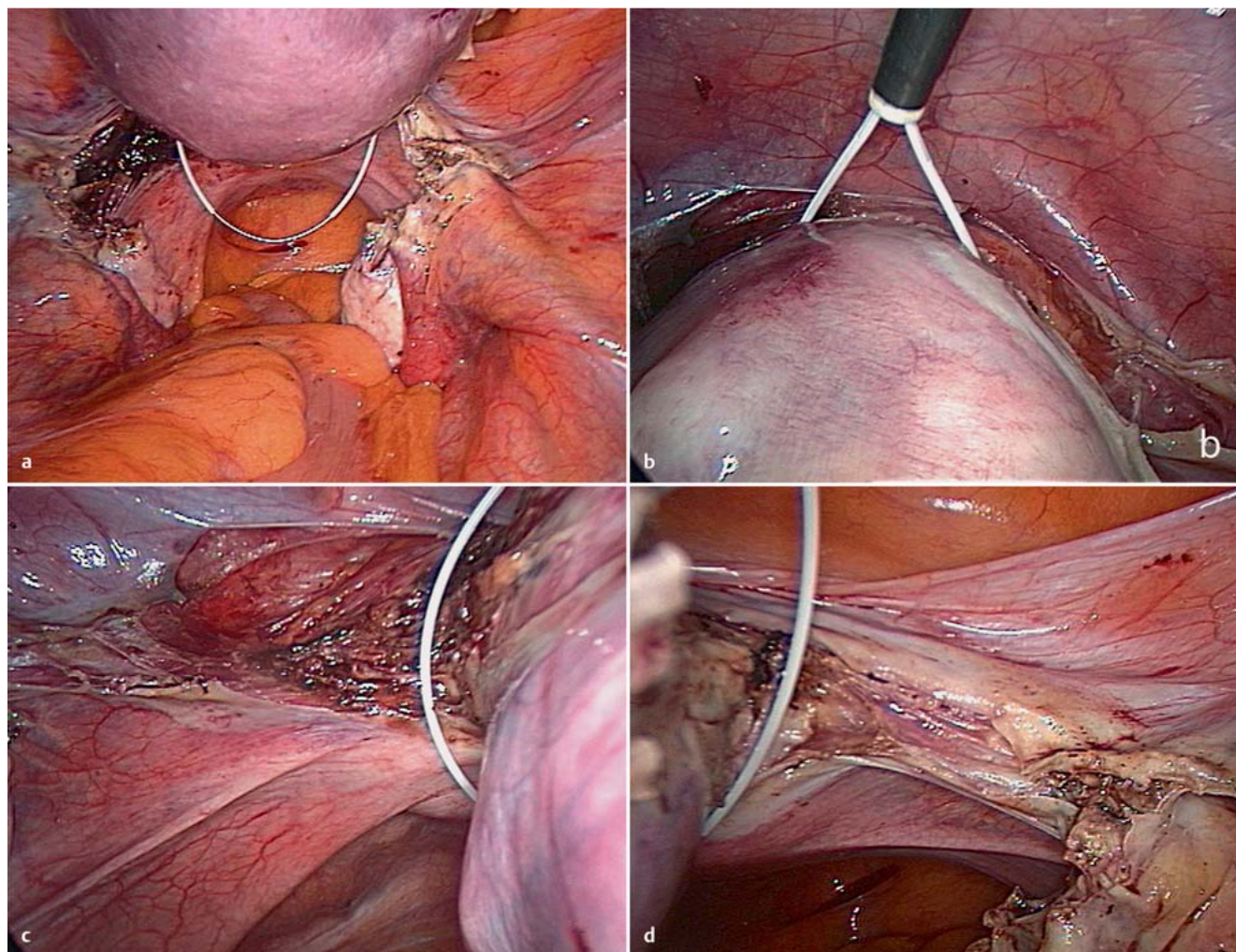


Fig. 3 a to d Checking the placement of the SupraLoop™: bowel (a), bladder (b), left pelvic side wall (c), right pelvic side wall (d).

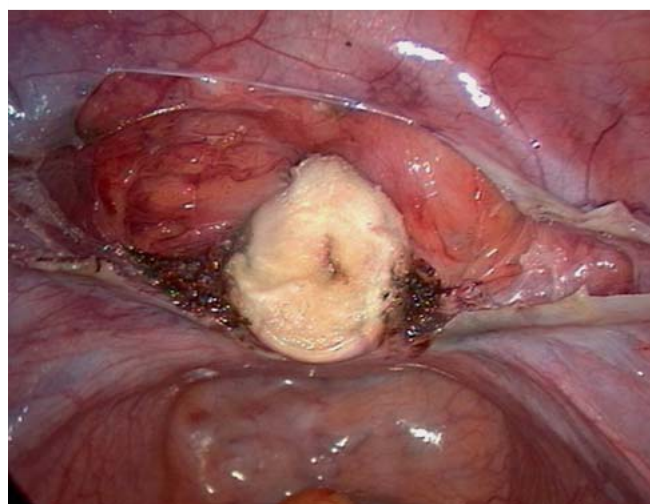


Fig. 4 Final intraoperative situs: coagulated cervical stump.

respectively numbers and percentages. To assess differences between groups, Wilcoxon rank-sum tests respectively Fisher's exact tests were performed. A significance level of 0.05 was chosen.

Results



The study included a total of 1598 patients; in 1070 patients (67.0%) the cervix was detached using the monopolar SupraLoop™ device, and in 528 patients (33.0%) the cervix was detached using the monopolar needle. Surgeries were performed by 14 surgeons, each performing between 3 and 219 procedures. The most frequent indication for surgery were uterine leiomyomas (72.2% in the SupraLoop™ group vs. 75.6% in the monopolar needle group) and dysfunctional uterine bleeding (77.6% resp. 74.0%) in both study groups.

Patient characteristics and intraoperative data

Patient demographics are shown in [Table 1](#), with no significant differences between the two study groups. The uterine weight range for the women included in the study was between 35 and 1400 g. Cervical detachment time (SupraLoop™ vs. needle; 0.12 ± 0.21 min vs. 5.1 ± 4.4 min [$p < 0.001$]), total device application including cutting time (SupraLoop™ vs. needle; 2.3 ± 1.8 min vs. 5.4 ± 2.4 min [$p < 0.001$]) and total operating time (SupraLoop™ vs. needle; 93 ± 41 min vs. 105 ± 44 min [$p < 0.001$]) for the hysterectomy was significantly shorter for the SupraLoop™ group.

Table 1 Patient characteristics and intraoperative data.

Variable	Supra-Loop™ n = 1 070	Needle n = 528	p-value (Wilcoxon test)
Age years, mean (SD)	47.2 (6.9)	47.6 (7.1)	0.190
BMI (kg/m ²), mean (SD)	25.3 (4.9)	25.2 (4.7)	0.864
Uterine weight (g), mean (SD)	186 (147)	211 (198)	0.062
Hb drop (mg/dl), mean (SD)	1.3 (0.8)	1.3 (0.8)	0.741
Operating time (min), mean (SD)	93 (41)	105 (44)	<0.001
Cervical detachment time (min), mean (SD) (n = 23 SupraLoop™ group; n = 26 needle group)	0.12 (0.21)	5.1 (3.4)	<0.001
Total device application and cutting time (min), mean (SD) (n = 23 SupraLoop™ group; n = 26 needle group)	2.3 (1.8)	5.4 (2.4)	<0.001

Intra-/perioperative and postoperative serious and minor surgical complications

Intra-/perioperative and postoperative serious surgical complications that occurred are shown in **Table 2**. While no intraoperative complication was attributed directly to the application of the SupraLoop™ device, two intraoperative complications were directly related to the application of the monopolar needle (a thermal bladder lesion and an injury of the external iliac artery). The bladder lesion was noted intraoperatively and was managed successfully conservatively; the postoperative course of the patient was uneventful. Additionally, a lesion of the external iliac artery was noted. Emergency laparotomy was performed and the injured external iliac artery was transfixated-ligated; the postoperative course of the patient was uneventful.

Minor complications in the SupraLoop™ arm were: urinary tract infections in nine cases, nine superficial hematomas not requiring surgical intervention, postoperative fever not requiring antibiotic therapy in 16 cases, postoperative fever requiring antibiotic therapy in four cases, two cases of postoperative vaginal bleeding and seven cases with minor complications not otherwise specified. Minor complication in the needle arm were: urinary tract infections in 10 cases, two superficial hematomas not requiring surgical intervention, postoperative fever not requiring antibiotic therapy in 16 cases, postoperative fever requiring antibiotic therapy in two cases, two cases of postoperative vaginal bleeding and two cases with minor complications not otherwise specified. There were no significant differences regarding minor complications between the groups of patients.

Intraoperative failures and handling of the newly developed device

We observed no intraoperative failures of the SupraLoop™ device and noted an easy handling of the device during the surgical procedure. Furthermore, after the detachment of the uterine corpus by SupraLoop™ no additional coagulation steps were needed in order to establish hemostasis. Three cervical stump hematomas were observed after surgery with the SupraLoop™ device,

Table 2 Intraoperative and postoperative serious surgical complications.

	Supra-Loop™ (n = 1 070)	Needle (n = 528)	p-value (Fisher test)
Intraoperative complications related to the surgical device			
Injury external iliac artery	0	1	
Bladder injury	0	1	
Intraoperative complications not related to the surgical device			
Ureteric injury	1	0	
Epigastric artery injury	1	0	
Total number of intra-operative complications	2 (0.2%)	2 (0.3%)	1.000
	Supra-Loop™ (n = 735)	Needle (n = 349)	
Postoperative complications (occurrence ≥ 1 week after surgery)			
Pelvic peritonitis	3	1	
Hematoma requiring surgical intervention			
▶ Cervical stump hematoma	3	0	
Re-operation due to adhesions	1	2	
Total number of post-operative complications	7 (1.0%)	3 (0.9%)	1.000

however, none of them required a secondary surgical intervention.

Discussion



The current study shows that cervical detachment in laparoscopic supracervical hysterectomy with the monopolar SupraLoop™ device results in decrease of operating time when compared to cervical detachment with the monopolar needle. Furthermore, the SupraLoop™ device is safe and easy to handle. We observed no surgical complications directly related to the SupraLoop™ device in 1070 LSH performed at our institution, whereas two intraoperative complications were directly related to the application of the monopolar needle.

Our results regarding cervical detachment time and total device application including cutting time are in concordance with previous clinical evidence. Dequesne et al. and Pasic et al. also reported a decrease in cervical detachment time and total device application and cutting time with the use of the electrode loop technique [10, 11]. However, Pasic et al. reported no significant decrease of total operating time in the group of patients with cervical detachment by electrode loop. In contrast with these findings we observed a significant decrease of the operating time for the entire hysterectomy in the group of patients with cervical detachment by SupraLoop™.

The overall complication rate (for both intra-/perioperative and postoperative complications) in our study compares favorably with complication rates during LSH [13–17]. The effectiveness and safety of LSH has been demonstrated by a number of large series of LSH procedures [13–17]. Furthermore, none of the intraoperative complications noted in our study were directly related to the SupraLoop™ device. This additionally underlines the safety of cervical detachment in LSH by loop electrode, which has been reported by other studies as well [10, 18–20].

The use of the SupraLoop™ device in LSH allows safe, fast detachment of the uterus from the cervix with minimal formation of

smoke and thus, improved visibility. In order to enhance safety, a large proportion of the loop is electrically isolated and the loop retracts back into the introducer as cutting proceeds to further reduce the risk of damage to adjacent organs. Furthermore, after detachment of the uterine corpus no additional coagulation steps were needed in order to establish hemostasis. Additionally, loop devices allow the supracervical separation of the uterus at or above the level of the coagulated uterine vessels, therefore minimizing slippage or retraction of the uterine vessels [18–20]. Furthermore, the SupraLoop™ device eliminates, similarly to other loop systems, the disadvantage of using straight rigid laparoscopic instruments to detach the uterus from the cervix regardless of the uterine size, and therefore, it is preferable [18–20]. Thus, the development of loops for cervical detachment is leading to an improvement and simplification of the operating technique. However, the relative costs of the SupraLoop™ device are slightly higher compared to the monopolar needle due to the disposable spare loop component.

In terms of economic considerations, generally accepted data do not exist as conditions vary largely between hospitals and countries. However, published figures can be of indicative value, and costs between 15–20 \$ or € per minute of operating room time seem plausible [21,22]. The costs of the SupraLoop device are 51 € and our findings revealed a significantly shorter operation time (mean difference: 12 min) in the SupraLoop arm compared to the needle arm. However, at the outset of the study, this specific endpoint was not implemented in the design and thus, these findings have to be interpreted with caution.

Loop electrodes simplify the cervical detachment and decrease the time required for fundal detachment, which many consider to be the most difficult part of laparoscopic supracervical hysterectomy [10]. Advantages of the SupraLoop™ compared to lozenge shaped electrode loop devices are its round shaped form that allows safe, anatomically adapted placement around the uterus, its easy handling, due to its “memory effect”, and reusability.

Possible pitfalls associated with supracervical hysterectomy with the SupraLoop™ device are a skew transection of the cervix, injury of adjacent structures (bowel, bladder, pelvic wall), transection below the coagulation area of the uterine arteries or a limited view in case of very large uteri. Possible pitfalls associated with supracervical hysterectomy with the monopolar needle are a higher risk of adjacent organ (rectum) and iliac vessel injury in case of very larger uteri due to limited view and possible slipping of the instrument and too deep transection of the cervix and sacrouterine ligaments.

A limitation of this study was its design which precluded randomization. However, the large number of patients included increases the assessment of clinical characteristics and surgical complications. Furthermore, the design of the current study did not include the analysis of operating learning curves and their possible influence on the reduction of the total operation time. Our study describes the first application of the monopolar SupraLoop™ device in LSH for cervical detachment and comparison with a conventional method of cervical detachment. The use of this new device has allowed us to improve operating times (cervical detachment time, total device application and cutting time, total operating time for the hysterectomy) and perform the operation safely. Nevertheless, based on our results, larger prospective, randomized, controlled trials comparing different loop electrode devices are warranted.

Conclusions for Practice



The newly developed monopolar loop electrode (SupraLoop™) is an effective and safe instrument for cervical detachment in laparoscopic supracervical hysterectomy, offering a significantly shorter operating time for the hysterectomy compared to the conventional method with a low risk of injury to adjacent organs and tissue and thus, leading to an improvement and simplification of the operating technique.

Conflict of Interest



Prof. Dr. med. Sara Brucker: Clinical trial investigator for Karl Storz; Consultant for Karl Storz.

References

- 1 Wallwiener D, Becker S. Perspectives in gynecologic surgery: past, present and future. *Gynecol Surg* 2004; 1: 63–65
- 2 Wattiez A, Cohen SB, Selvaggi L. Laparoscopic hysterectomy. *Curr Opin Obstet Gynecol* 2002; 14: 417–422
- 3 Garry R, Fountain J, Brown J et al. EVALUATE hysterectomy trial: a multicentre randomised trial comparing abdominal, vaginal and laparoscopic methods of hysterectomy. *Health Technol Assess* 2004; 8: 1–154
- 4 Hoffman CP, Kennedy J, Borschel L et al. Laparoscopic hysterectomy: the Kaiser Permanente San Diego experience. *J Minim Invasive Gynecol* 2005; 12: 16–24
- 5 Cipullo L, De Paoli S, Fasolino L et al. Laparoscopic supracervical hysterectomy compared to total hysterectomy. *JLS* 2009; 13: 370–375
- 6 Einarsson JI, Suzuki Y, Vellinga TT et al. Prospective evaluation of quality of life in total versus supracervical laparoscopic hysterectomy. *J Minim Invasive Gynecol* 2011; 18: 617–621
- 7 Wallwiener M, Taran FA, Rothmund R et al. Laparoscopic supracervical hysterectomy (LSH) versus total laparoscopic hysterectomy (TLH): an implementation study in 1,952 patients with an analysis of risk factors for conversion to laparotomy and complications, and of procedure-specific re-operations. *Arch Gynecol Obstet* 2013; 288: 1329–1339
- 8 De Wilde RL. Totale Hysterektomie bei Frauen mit großen Uteri nach Kaiserschnitt. Wie vermeidet man eine Läsion der Harnwege? *Geburtsh Frauenheilk* 2013; 73: 27
- 9 Brucker S, Solomayer E, Zubke W et al. A newly developed morcellator creates a new dimension in minimally invasive surgery. *J Minim Invasive Gynecol* 2007; 14: 233–239
- 10 Pasic R, Abdelmonem A, Levine R. Comparison of cervical detachment using monopolar lap loop ligature and conventional methods in laparoscopic supracervical hysterectomy. *JLS* 2006; 10: 226–230
- 11 Dequesne J, Schmidt N, Frydman R. A new electrosurgical loop technique for laparoscopic supracervical hysterectomy. *Gynaecological Endoscopy* 2008; 7: 29–32
- 12 Wallwiener D, Jonat W, Kreienberg R et al. Atlas der gynäkologischen Operationen. Stuttgart: Thieme; 2008
- 13 Lyons T. Laparoscopic supracervical versus total hysterectomy. *J Minim Invasive Gynecol* 2007; 14: 275–277
- 14 Bojahr B, Raatz D, Schonleber G et al. Perioperative complication rate in 1706 patients after a standardized laparoscopic supracervical hysterectomy technique. *J Minim Invasive Gynecol* 2006; 13: 183–189
- 15 Mueller A, Renner SP, Haeblerle L et al. Comparison of total laparoscopic hysterectomy (TLH) and laparoscopy-assisted supracervical hysterectomy (LASH) in women with uterine leiomyoma. *Eur J Obstet Gynecol Reprod Biol* 2009; 144: 76–79
- 16 Boosz A, Lermann J, Mehlhorn G et al. Comparison of re-operation rates and complication rates after total laparoscopic hysterectomy (TLH) and laparoscopy-assisted supracervical hysterectomy (LASH). *Eur J Obstet Gynecol Reprod Biol* 2011; 158: 269–273
- 17 Grosse-Drieling D, Schlutius JC, Altgassen C et al. Laparoscopic supracervical hysterectomy (LASH), a retrospective study of 1,584 cases regarding intra- and perioperative complications. *Arch Gynecol Obstet* 2012; 285: 1391–1396

- 18 Lieng M, Istre O, Langebrekke A *et al.* Outpatient laparoscopic supracervical hysterectomy with assistance of the lap loop. *J Minim Invasive Gynecol* 2005; 12: 290–294
- 19 Erian J, El-Toukhy T, Chandakas S *et al.* One hundred cases of laparoscopic subtotal hysterectomy using the PK and Lap Loop systems. *J Minim Invasive Gynecol* 2005; 12: 365–369
- 20 Erian J, Hassan M, Pachydakis A *et al.* Efficacy of laparoscopic subtotal hysterectomy in the management of menorrhagia: 400 consecutive cases. *BJOG* 2008; 115: 742–748
- 21 Overhaus M, Schaefer N, Walgenbach K *et al.* Efficiency and safety of bipolar vessel and tissue sealing in visceral surgery. *Minim Invasive Ther Allied Technol* 2012; 6: 396–401
- 22 Macario A. What does one minute of operating room time cost? *Clin Anesth* 2010; 22: 233–236