

Atypical Manifestation of Vestibular Schwannoma

Guilherme Webster¹ Rui Carlos Ortega Filho¹ Antonini de Oliveira e Sousa¹
Márcio Cavalcante Salmito¹ Mariana Lopes Favero¹ Patrícia Maria Sens Marques¹

¹ Department of Otorhinolaryngology, Hospital do Servidor Público Municipal de São Paulo, São Paulo/SP, Brazil

Address for correspondence Guilherme Webster, MD, Hospital do Servidor Público Municipal de São Paulo, Rua Castro Alves, 355—Apto 95, Aclimação, CEP 01532-001, São Paulo/SP, Brazil
(e-mail: guilhermewebster@uol.com.br).

Int Arch Otorhinolaryngol 2013;17:419–420.

Abstract

Introduction Vestibular schwannoma (also known as *acoustic neuroma*) is a benign tumor whose cells are derived from Schwann sheaths, which commonly occurs from the vestibular portion of the eighth cranial nerve. Furthermore, vestibular schwannomas account for ~8% of intracranial tumors in adults and 80 to 90% of tumors of the cerebellopontine angle. Its symptoms are varied, but what stands out most is a unilateral sensorineural hearing loss, with a low index of speech recognition.

Objective Describe an atypical manifestation of vestibular schwannoma.

Case Report The 46-year-old woman had vertigo and binaural hearing loss and fullness, with ear, nose, and throat examination suggestive of cochlear injury. After 6 months, the patient developed worsening of symptoms and onset of right unilateral tinnitus. In further exams the signs of cochlear damage remained, except for the vestibular test (hyporeflexia). Magnetic resonance imaging showed an expansive lesion in the right cerebellopontine angle.

Discussion This report warns about the atypical manifestations of vestibular schwannoma, which must always be remembered in investigating and diagnosing hearing loss.

Keywords

- ▶ neuroma
- ▶ acoustic
- ▶ dizziness
- ▶ hearing loss

Introduction

The acoustic neuroma is a benign tumor of the eighth cranial nerve, which commonly affects the portion of the vestibular nerve.¹ This tumor represents ~8% of all intracranial tumors in adults and 80 to 90% of tumors in the cerebellopontine angle.^{1,2} The incidence of acoustic neuroma is ~1:100,000 people per year,³ but with the evolution of imaging that number has increased because asymptomatic lesions are detected. Its pathogenesis is characterized by a hyperproliferation of Schwann cells, often insidious.^{1,3}

The vestibular schwannoma can occur in two types: sporadic or associated with neurofibromatosis type 2. In the first, the tumor is unilateral and represents ~95% of cases, whereas, when associated with neurofibromatosis type 2, the tumor is bilateral and represents the other remaining 5% of cases.⁴

The most common manifestation of acoustic neuroma is a unilateral and gradual loss of hearing, and it may be associated with tinnitus.^{1,4,5} Due to the slow tumor growth, there is enough time for the occurrence of vestibular compensation and adjustment, causing infrequent vertigo symptoms.⁴

For the diagnosis, it is necessary to use imaging methods during the investigation, especially computed tomography and magnetic resonance imaging, both with emphasis on cerebellopontine angle to check the internal auditory canal—the main location of emergence of vestibular schwannoma.

Referring to the differential diagnosis of this disease, meningiomas can be cited; the main differential diagnosis includes Meniere disease, metastases, and tumors of other cranial nerves.⁴

The aim of this study is to report an atypical manifestation of vestibular schwannoma.

received
February 5, 2012
accepted
April 22, 2012

Copyright © 2013 by Thieme Publicações Ltda, Rio de Janeiro, Brazil
DOI <http://dx.doi.org/10.1055/s-0033-1351673>.
ISSN 1809-9777.

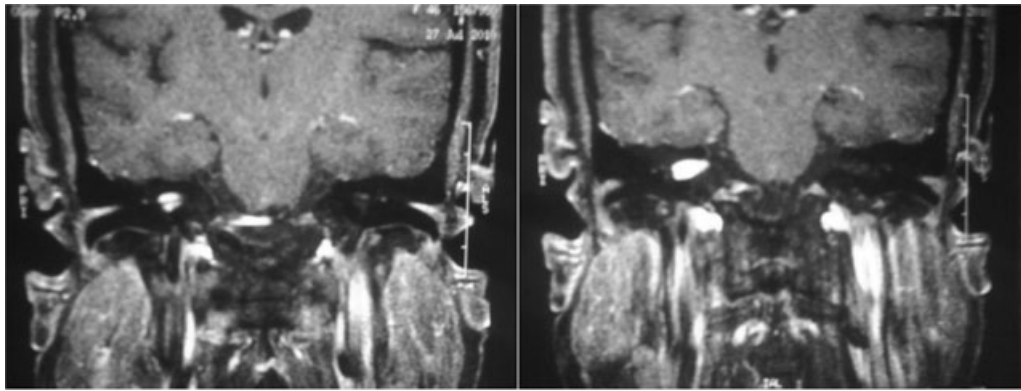


Fig. 1 Magnetic resonance imaging showing lesion occupying the entire length of the right internal auditory canal (5 × 6 × 14 mm) with lateral margin establishing contact with the bottom of the canal and labyrinth without extension.

Case Report

The patient, a 46-year-old woman, presented with 2-month history of symptoms of dizziness that lasted several hours. She reported associated nausea, sense of fullness, and bilateral hearing loss during the attacks. On physical examination, no change was found.

Audiometry showed sensorineural loss at 8 kHz in the right ear, with speech recognition rate of 100% at 50 dB and stapedius muscle reflex present but without recruitment. The otoneurologic examination showed right hyporeflexia. The auditory brainstem response (ABR) showed no signs of retrocochlear disease, and electrocochleography showed signs of endolymphatic hydrops in the left ear.

Six months after symptom onset, the patient's condition worsened, with the appearance of constant tinnitus in right ear and normal ear, nose, and throat examination. A new audiometry showed moderate to severe sensorineural loss, flat, between 1 and 8 kHz, with speech recognition rate of 70% at 45 dB in the right ear and recruitment in stapedial reflex. Magnetic resonance imaging was suggestive of acoustic neuroma, with dimensions of 5 × 6 × 14 mm, in the right internal auditory canal (→Fig. 1).

Discussion

The vestibular schwannoma is the most common tumor in the region of the internal auditory canal and is often associated with asymmetrical and sensorineural loss associated with a higher prevalence in females.

The literature shows that the more frequent hearing change in vestibular schwannoma is a sensorineural loss in high frequencies, associated with absence of acoustic reflex, and a low rate of recognition speech.^{1–5} However, as can be seen in the case presented, it has been detected in the presence of stapedial recruitment, which would speak in favor of a cochlear etiology. Moreover, the first consultation revealed a 100% recognition rate of monosyllables,

which would also take away the possibility of vestibular schwannoma.

In ABR of vestibular schwannoma, we would find an increased interval between waves I and III above 2.3 milliseconds, an increased interval between waves I and V above 4.4 milliseconds, an interaural difference of wave V above 0.4 milliseconds, as well as absence of wave I.⁴ However, ABR performed in the patient did not show any suggestive changes.

The result of the vestibular test case is reported in accordance with the literature, because it showed hyporeflexia on the affected side.⁴

Thus, due to inconclusive electrophysiologic examination, we turned to magnetic resonance imaging—the gold standard in detecting tumors of the cerebellopontine angle—for help diagnosing the patient.^{2,3,5}

Conclusion

This report has warned us about the atypical manifestations of vestibular schwannoma, which should always be remembered in research and diagnosis of hearing loss.

References

- 1 Park JK, Black PM, Vernick DM, Ramakrishna N. Vestibular schwannoma (acoustic neuroma). Available at: <http://www.uptodate.com/contents/vestibular-schwannoma-acoustic-neuroma>. Accessed January 28, 2012
- 2 Zandoni A, Cruz OLM. Schwannoma vestibular. In: Ganança FF, Ponte P, eds. Manual de otorrinolaringologia e cirurgia de cabeça e pescoço. 1st ed. São Paulo, Brazil: Editora Manole; 2011:577–589
- 3 Lin D, Hegarty JL, Fischbein NJ, Jackler RK. The prevalence of “incidental” acoustic neuroma. Arch Otolaryngol Head Neck Surg 2005;131:241–244
- 4 Swensson RC, Swensson RP, Pizzini FEC, Boldorini PR, Jorge Júnior JJ. An uncommon presentation of a VIII nerve tumor. Braz J Otorhinolaryngol 2008;74:628–631
- 5 Coca Pelaz A, Rodrigo JP, Llorente JL, Gómez JR, Suárez C. [Unusual clinical presentations of vestibular schwannomas]. Acta Otorrinolaryngol Esp 2008;59:187–189