Monitoring of Gadolinium-BOPTA Uptake into the Vessel Wall during Magnetic Resonance (MR)-Guided Angioplasty of the Peripheral Arteries with a Paclitaxel/Gadolinium-BOPTA-Coated Balloon: An Experimental Study at 3 Tesla

Monitoring von Gadolinium-BOPTA-Aufnahme in die Gefäßwand während einer Magnet Resonanz (MR) gesteuerten Angioplastie der peripheren Gefäße mit einem beschichteten Ballon: Eine experimentelle Studie an einem 3 Telsa MR-Scanner

Authors M. Neizel[1], A. Ruebben[2], N. Weiss[2], R. W. Günther[3], M. Kelm[1], G. A. Krombach[4]

Affiliations
[1] Department of Cardiology, Pneumology and Angiology, University Hospital Düsseldorf
[2] Aachen Resonance, Aachen Resonance, Aachen
[3] Deparment of Radiology, University Hospital Aachen
[4] Department of Radiology, University Hospital Giessen

Key words
- interventional MRI
- angioplasty
- drug-eluting balloon
- vascular
- MR imaging

received 25.10.2012
accepted 19.8.2013

Bibliography
DOI http://dx.doi.org/10.1055/s-0033-1355543
Published online: 18.10.2013
Fortschr Röntgenstr 2014; 186: 388–393 © Georg Thieme Verlag KG Stuttgart · New York · ISSN 1438-9029

Correspondence
Dr. Mirja Neizel
Department of Cardiology, Pneumology and Angiology, University Hospital Düsseldorf
Moorenstraße 5
40225 Düsseldorf
Germany
Tel.: ++ 49/02 11/8 10 87 90
Fax: ++ 49/02 11/81/1 88 04
mirja.neizel@med.uni-duesseldorf.de

Zusammenfassung

Ziel: Nach Paclitaxel-beschichteter Ballonangioplastie kann unter Röntgendurchleuchtung nicht kontrolliert werden, ob das Paclitaxel wirklich in die Gefäßwand aufgenommen wurde und so die Restenose-Rate vermindern kann. Ziel dieser Studie war es zu untersuchen, ob ein Monitoring von Gadolinium-BOPTA-Aufnahme in die Gefäßwand nach MR-gesteuerter beschichteter Ballon-Angioplastie der peripheren Gefäße möglich ist.

Material und Methoden: 6 Schweine (Gewicht 47 ± 2 kg) wurden untersucht. Alle Untersuchungen wurden an einem 3 Tesla MRT-Scanner durchgeführt. Eine MR-gesteuerte bilaterale Angioplastie der Iliacalgefäße wurde mit einem Paclitaxel/Gadolinium-BOPTA beschichtetem Ballonkatheter durchgeführt. Die Machbarkeit des Monitorings der Gadolinium-BOPTA-Aufnahme in die Gefäßwand wurde an 4 Schweinen untersucht. Zusätzlich wurden bei 2 weiteren Schweinen bilaterale Stenosen der Iliacalgefäße induziert. Die Aufnahme von Gadolinium-BOPTA in die Gefäßwand wurde mit einer T1-gewichteten Gradientenecho-Sequenz visualisiert. Zusätzlich wurde die normalisierte Signalintensität der Gefäßwand bei allen Tieren vor und bis zu 45 Minuten nach der Intervention gemessen.

Ergebnisse: Die Paclitaxel/Gadolinium-BOPTA beschichtete Ballonangioplastie wurde in allen Iliacalarterien erfolgreich durchgeführt (n = 12). Bei allen Tieren mit Iliaca-Stenose zeigte sich in der MR-Angiografie eine erfolgreiche Behandlung der Iliacalstenosen (n = 4). Die normalisierte Signalintensität der Gefäßwand stieg in beiden Gruppen signifikant nach der Intervention an ($p < 0{,}001$).

Schlussfolgerung: Visualisierung der Gadolinium-BOPTA-Aufnahme in die Gefäßwand während einer MR-gesteuerten Paclitaxel/Gadolinium-BOPTA beschichteten Ballonangioplastie ist machbar. Dies ist ein erster Schritt in die Richtung, eine

Abstract

Purpose: The success of paclitaxel distribution within the vessel wall during paclitaxel-coated balloon angioplasty to prevent restenosis cannot be monitored under X-ray guidance. The aim of this pilot study was to demonstrate the feasibility of monitoring Gadolinium-BOPTA delivery within the vessel wall during magnetic resonance (MR)-guided paclitaxel/Gadolinium-BOPTA-coated balloon angioplasty of the peripheral arteries.

Materials and Methods: 6 pigs (47 ± 2 kg) were investigated. All experiments were performed using a 3 Tesla MR scanner. MR-guided bilateral angioplasty of the iliac arteries was performed using a paclitaxel/MR contrast agent-coated balloon catheter. The feasibility of monitoring the delivery of Gadolinium-BOPTA to the vessel wall was assessed in 4 animals. In two additional animals, bilateral stenosis was surgically induced in the iliac arteries. Delivery of paclitaxel to the vessel wall was monitored using a 3 D T1-weighted gradient echo (GE) sequence for delineation of the vessel wall. Normalized signal intensity (SI) of the vessel wall was measured before and repeatedly after the intervention for 45 min. in all animals.

Results: Paclitaxel/gadolinium-BOPTA-coated balloon angioplasty was successfully accomplished in all iliac arteries (n = 12). In animals with stenosis MR-angiography demonstrated successful dilatation (n = 4). The normalized SI of the vessel wall on T1-weighted GE images significantly increased after the intervention in all animals with and without stenosis for more than 45 min. ($p < 0.001$).

Conclusion: Monitoring of Gadolinium-BOPTA into the vessel wall during MR-guided coated balloon angioplasty is feasible. This is a first step towards providing a tool for the online control of homogenous drug delivery after paclitaxel-coated balloon angioplasty.

This document was downloaded for personal use only. Unauthorized distribution is strictly prohibited.

Therapiekontrolle zu ermöglichen, mit welcher die homogene Medikamentenaufnahme nach beschichteter Ballonangioplastie nachgewiesen werden könnte.

Key Points:

- Monitoring of gadolinium-BOPTA uptake into the vessel wall during MR-guided coated balloon angioplasty is feasible.
- Endovascular MR-guided interventions on a 3 Tesla MR scanner are feasible.
- This is a first step towards providing a tool for online control of homogenous drug delivery after paclitaxel-coated balloon angioplasty.

Citation Format:

- Neizel M, Ruebben A, Weiss N et al. Monitoring of Gadolinium-BOPTA Uptake into the Vessel Wall during Magnetic Resonance (MR)-Guided Angioplasty of the Peripheral Arteries with a Paclitaxel/Gadolinium-BOPTA-Coated Balloon: An Experimental Study at 3 Tesla. Fortschr Röntgenstr 2014; 186: 388–393

Introduction

Despite substantial improvements in endovascular techniques, the rate of vascular restenosis remains high, especially in patients with peripheral artery disease [1, 2]. Drug-eluting stents are often applied to avoid restenosis. However, concerns have been raised due to long-lasting antiplatelet therapy and late thrombotic complications [3, 4]. Preclinical studies have demonstrated that the use of paclitaxel-coated balloons in both coronary and peripheral arteries can create a high local drug concentration and diminished neointimal proliferation, even when the balloon delivery exposure is brief [5, 6]. Recent clinical studies proved that paclitaxel balloon coating is able to reduce restenosis in patients undergoing angioplasty of peripheral arteries [7, 8]. Paclitaxel-coated balloon angioplasty is usually conducted under fluoroscopy guidance. However, uptake of the drug within the vessel wall, which might prove the success of the intervention, cannot be monitored under fluoroscopy guidance.

Magnetic resonance (MR)-guided endovascular intervention is a developing field of preclinical research and preliminary clinical experience [9 – 13]. The feasibility of monitoring the delivery of a MR contrast medium tagged solution to the vessel wall during MR-guided dilatation of the peripheral arteries has been demonstrated before [14]. In that study a microporous balloon instead of a coated balloon was used. However, a microporous balloon requires the interventionalist to inject the drug into the catheter via a syringe. Coated balloons have not been applied so far. Beyond that, the study was conducted on a 1.5 Tesla MR scanner. Vessel wall imaging, however, benefits from the gain in signal-to-noise ratio at a higher field strength. We therefore hypothesized that gadolinium-BOPTA uptake into the vessel wall can be monitored during MR-guided paclitaxel/gadolinium-BOPTA-coated balloon angioplasty of the peripheral arteries on a 3 Tesla MR scanner.

Methods

Experimental animals

6 domestic pigs (body weight 47 ± 2 kg) were included in the study. All experiments were performed according to the international standards for animal experiments and were approved by the local ethical animal care committee.

The pigs were intubated and mechanically ventilated. All interventions were done under general anesthesia, introduced with intramuscularly injections of atropine (0.5 ml/10 kg body weight, azaperone (2 ml/10 kg body weight), and ketamine (1 ml/10 kg body weight). General anesthesia was maintained with intravenously injected phenobarbital sodium and fentanyl as needed.

The feasibility of monitoring gadolinium-BOPTA uptake into the vessel wall during MR-guided angioplasty of the peripheral arteries with a gadolinium-BOPTA/paclitaxel-coated balloon was investigated in four animals. In two additional animals surgical bilateral stenosis of the external iliac arteries was created by placing a suture (Cardiofil, Davis & Geck, Wayne, NY, USA) around the vessel as described before [14]. Bilateral femoral artery sheaths (8F) were placed in all pigs to perform angioplasty.

MR protocol

All experiments were performed using a 3 Tesla MR system (Achieva, Philips, Best, the Netherlands) with a 6-channel coil. The laboratory was equipped with interventional LCD in-room monitors for in-room guidance during the procedure.

Vessel wall imaging was performed before and directly after the intervention and after 10, 20, 30 and 45 minutes using a 3 D T1-weighted gradient echo (GE) sequence. The image parameters of this high resolution sequence were as follows: TR 59 ms, TE 1.72 ms, flip angle 35°, voxel size 0.73 × 0.73 × 3 mm^3, slices 70, fat suppression using spectral presaturation with inversion recovery (SPIR), no parallel imaging, acquisition time 5 minutes.

In animals with stenosis, local MR angiography was performed before and after the intervention to evaluate the degree of stenosis. A 5F pigtail catheter (Cook®, Bloomington, Indiana, USA) was placed in the aorta abdominalis below the renal arteries and 2 ml of MR contrast agent (gadolinium-DTPA, Magnevist®, Bayer, Germany) diluted with 18 ml of NaCl 0.9 % were locally injected to reduce the amount of contrast medium required and thus minimize the wash-out time of gadolinium-DTPA from the body before the intervention. A T1-weighted angiography sequence was immediately started with contrast agent injection. The image parameters for this sequence were TR 7.9 ms, TE 1.42 ms, flip angle 30°, voxel size 0.82 × 0.82 × 1.6 mm^3, SENSE factor 2, acquisition time 27 s. Maximum intensity projections (MIP) were reconstructed from the datasets on the MR scanner.

All interventions (placement of pigtail catheter for angiography and angioplasty of the external iliac arteries) were monitored using a steady-state free precession (SSFP) real-time imaging sequence. The parameters of the sequence were TR 3 ms, TE 1.3 ms, flip angle 8°, voxel size 2.67 × 2.67 × 8 mm^3, acquisition mode (k-space trajectory) radial, no parallel imaging. Image planes for the real-time imaging sequence were planned on the T1-weight-

This document was downloaded for personal use only. Unauthorized distribution is strictly prohibited.

ed GE sequence or on MR angiography and were adapted during the procedure according to the needs of the interventionalists.
In one animal without stenosis, angioplasty with a non-coated 5F balloon catheter (Fox Plus (40 mm × 8 mm), Abbott®, Beringen, Switzerland) was conducted bilaterally before the actual dilatation with a coated balloon to ensure that the enhancement of the vessel wall was caused by the balloon coating and not by other effects. After non-coated balloon angioplasty, a 3 D T1-weighted GE sequence, as described above, was conducted. Moreover, a T2-weighted turbo spin echo (TSE) sequence was acquired to investigate if the signal intensity increased due to water uptake within the vessel wall. The sequence parameters for the T2-weighted TSE sequence were as follows: TR 3000 ms, TE 80 ms, flip angle 90°, voxel size 0.56 × 0.73 × 3 mm^3, fat suppression using SPIR, SENSE factor 1.5.

Devices and intervention

Bilateral angioplasty of the external iliac arteries was performed in all animals. Catheterization was performed through the femoral artery sheath with an ipsilateral approach. Heparin was given as an initial bolus of 10 000 IU. A 0.014 inch guidewire (Cook®, Bloomington, Indiana, USA) and a 5F cobra catheter (Cook®, Bloomington, Indiana, USA) were advanced through a femoral artery sheath and then placed in the aorta abdominalis. The cobra catheter was then removed. A 5F balloon catheter (diameter 8 mm, length 40 mm, Aachen Resonance®, Aachen, Germany) coated with paclitaxel and gadolinium-BOPTA was then inserted over the guidewire and placed in position. Dilatation of the vessel was performed by inflating the balloon with a 10 % gadolinium-DTPA/NaCl 0.9 % solution for improved visualization. Balloon inflation was standardized to 1 min. with an inflation pressure of 10 atm. The balloon was then deflated and the balloon catheter and the guidewire were removed. All procedures were carried out by two experienced investigators.

Paclitaxel/gadolinium-BOPTA-coated balloon catheter

For the purpose of this study we modified a commercially available drug-eluting balloon "Elutax SV" (Aachen Resonance, Germany). The balloon distinguishes itself by a three-dimensional paclitaxel layer. Additionally, gadolinium-BOPTA was applied into the drug matrix by spraying gadolinium-BOPTA/ethanol 95 % solution onto the surface of the balloon. Because of the porous structure of the paclitaxel coating, gadolinium-BOPTA could partially seep away into the drug layer, and the rest dried as a top layer on the drug matrix. The ethanol volatilized minutes after application. The measured (by weight) final paclitaxel/gadolinium-BOPTA ratio was around 2:1.
Because of the proximity of both substances and the complex structure of paclitaxel and gadolinium-BOPTA, ion compounds and van der Waals compounds, or generally speaking dispersion interaction may possibly bond both substances to each other. These natural chemical bonds are reversible. However, the molecules are not going to be changed with respect to their chemical properties.

Data analysis

The signal intensity (SI) of the vessel wall was calculated to measure the uptake of gadolinium-BOPTA within the vessel wall. The SI was measured on the T1-weighted 3 D GE images before and after the intervention using a commercial workstation (Extended work space, release 2.6, Philips, Best, the Netherlands) and was normalized to that of the iliopsoas muscle in the same image (SI of the vessel wall minus SI of the iliopsoas). The normalized SI before the intervention was then compared to the normalized SI after the intervention. To ensure that the same regions were evaluated, a region of interest (ROI) was drawn to the enhanced vessel wall after angioplasty and was then copied to the image before the intervention. This was possible because the position of the animal did not change and exactly the same sequence with the same field of view was used.
In animals with created stenosis, the severity and length of stenosis was evaluated on MIP images by consensus reading of two experienced MR specialists (G. A. K. and M. N.) and were classified as mild (< 50 %), moderate (50 – 75 %), severe (76 – 99 %) and occluded (100 %).

Statistical analysis

All values were reported as mean ± standard deviation. Comparison between normalized SI of T1-weighted images before and after angioplasty was performed with a paired t-test. Statistical analysis of the control vessels was performed with an f-test. Differences were regarded as statistically significant at $p < 0.05$. All statistical analysis was performed using MedCalc (Mariakerke, Belgium, version 9.3.1).

Results

▼

Balloon angioplasty

The guidewire was visible in the blood pool along its entire length. The balloon catheter was visible after dilatation with a diluted gadolinium solution (**Fig. 1**). Placement of the guidewire and catheter was feasible in all cases. Paclitaxel/gadolinium-BOPTA-coated balloon angioplasty was successfully performed in all animals bilateral with iliac stenosis (external iliac artery left and

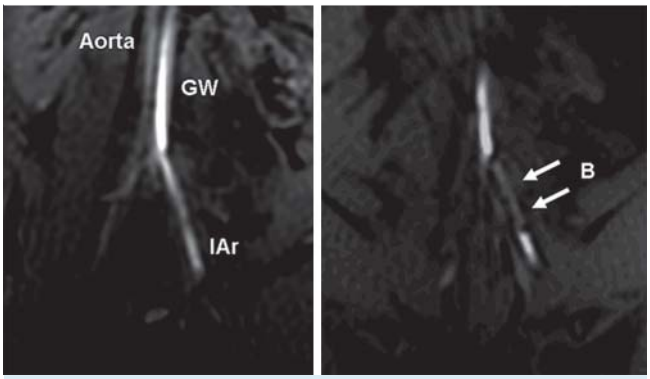

Fig. 1 Real-time images of MR-guided angioplasty at 3 Tesla. On the left, the guide wire, visible bright white in the blood pool, was advanced through a femoral artery sheath and placed in the aorta abdominalis (left) (GW = guide wire, Aorta = aorta abdominalis, IAr = iliac artery right). On the right, the balloon catheter was then placed in the vessel at the location of the stenosis and balloon angioplasty was performed. For improved passive visualization of the balloon catheter, dilatation was performed using a diluted gadolinium-DTPA solution (B = balloon catheter, see also arrows).

Abb. 1 Der Führungsdraht wird durch eine femorale Schleuse vorgebracht und in der Aorta abdominalis placiert (links) (GW = Führungsdraht, Aorta = Aorta abdominalis, IAr = rechte Iliacalarterie). Der Ballonkatheter wird dann in der Position von der Stenose placiert und die Angioplastie durchgeführt mit dem beschichteten Ballon (rechts). Zur verbesserten Visualisierung des Ballonkatheters wurde die Dilatation mit einer verdünnten Gadolinium-DTPA Lösung durchgeführt (B = Balloncatheter).

This document was downloaded for personal use only. Unauthorized distribution is strictly prohibited.

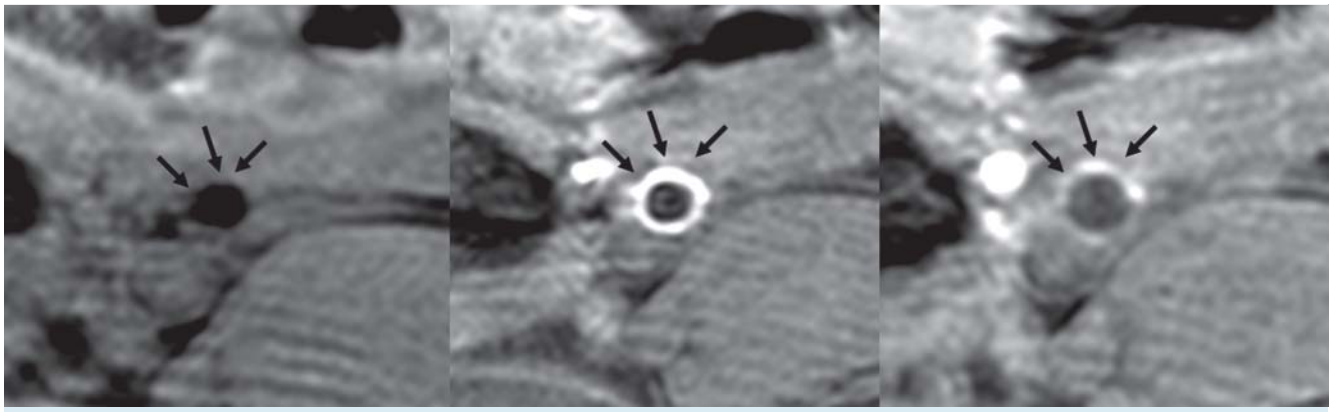

Fig. 2 Vessel wall imaging before and after angioplasty. Vessel wall imaging was performed before and after paclitaxel/gadolinium-BOPTA-coated balloon angioplasty using a T1-weighted high-resolution gradient echo (GE) sequence. On the left side the vessel wall (arrows) before angioplasty is shown with no enhancement of the vessel wall. In the middle the T1-weighted GE image directly after angioplasty shows homogenous enhancement of the vessel wall suggesting uptake of gadolinium within the vessel wall. On the right side a T1-weighted GE image 30 minutes after angioplasty is demonstrated. The enhancement of the vessel wall has already decreased.

Abb. 2 Die Darstellung der Gefäßwand wurde vor und nach beschichteter (Paclitaxel/Gadolinium-BOPTA) Angioplastie durchgeführt mit einer T1-gewichteten hochauflösenden Gradientenecho-Sequenz. Links sieht man die Gefäßwand vor der Angioplastie ohne Anreicherung der Gefäßwand. In der Mitte ist das Gefäß direkt nach der beschichteten Ballonangioplastie zu sehen mit homogener Aufnahme des Gadoliniums in die Gefäßwand. Rechts sieht man das Gefäß 30 Minuten nach der Angioplastie. Die Signalintensität in der Gefäßwand hat bereits schon wieder abgenommen.

Table 1 Signal intensity of the vessel wall before and after PTA

Tab. 1 Signalintensität der Gefäßwand vor und nach der PTA

	SI before PTA	SI after PTA	p-value
animals without stenosis n = 8 PTA	0.78 ± 0.16	1.91 ± 0.05	p < 0.001
animals with stenosis n = 4 PTA	0.75 ± 0.2	1.72 ± 0.48	p < 0.001

PTA = percutaneous transluminal angioplasty; SI = normalized signal intensity
PTA = percutane Angioplasty; SI = normalisierte Signalintensität

right, n = 4) and without iliac stenosis (external iliac artery left and right, n = 8). In animals with stenosis the severity of stenosis was high (70 – 99 %) in all cases before the intervention (n = 4). After angioplasty the stenosis was completely removed in 3 cases. One stenosis was still mild (severity of stenosis < 50 %). No complications such as dissection, perforation of the vessel wall and occlusion of the vessel occurred.

Vessel wall imaging

Vessel wall imaging was successfully conducted in all animals with and without stenosis. The normalized SI of the vessel wall on T1-weighted GE images significantly increased directly after the intervention in all animals (0.78 ± 0.16 versus 1.86 ± 0.3; p < 0.001) (**Fig. 2**).

In animals without stenosis the normalized SI was 0.78 ± 0.16 before and 1.91 ± 0.05 directly after the intervention (p < 0.001). In animals with stenosis the normalized SI was 0.75 ± 0.2 before and 1.72 ± 0.48 directly after the intervention (p < 0.01). The normalized SI was not significantly different in animals with and without stenosis (before intervention: p = 0.86; after intervention: p = 0.45) (**Table 1**).

Course of SI

The course of the normalized SI of the vessel wall directly after gadolinium-BOPTA/paclitaxel coated balloon angioplasty until 45 minutes after angioplasty is illustrated in **Fig. 3**. The SI of the vessel wall decreased over time. After 45 minutes, the normalized SI was still significantly different from the normalized SI before the intervention (0.80 ± 0.18 versus 0.89 ± 0.15, p = 0.02)

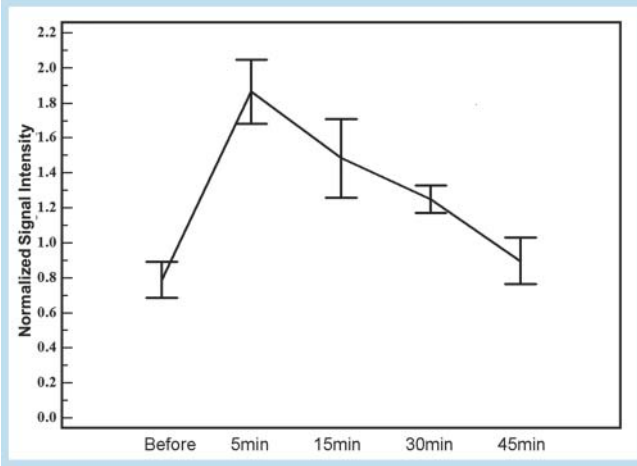

Fig. 3 Time course of normalized signal intensity after angioplasty. The time course of normalized signal intensity (SI) is illustrated in this figure. Before angioplasty the normalized SI is low. Directly after angioplasty the normalized SI reaches its maximum and then decreases.

Abb. 3 Der Zeitverlauf der normalisierten Signalintensität ist in dieser Abbildung dargestellt. Nach der Angioplastie steigt die Signalintensität signifikant auf das Maximum an, um dann im Verlauf wieder abzufallen.

MR angiography

Placement of the pigtail catheter in animals with stenosis was feasible in all cases to perform local MR angiography (n = 2). After injection of 10 % gadolinium-DTPA, local MR angiography could be successfully performed before and after angioplasty and MIPs could be created.

This document was downloaded for personal use only. Unauthorized distribution is strictly prohibited.

Control group

The normalized SI was measured in T1-weighted GE images before and after angioplasty with a non-coated balloon catheter in one animal bilaterally. No significant difference of the normalized SI before and after the intervention was observed (0.63 ± 0.02 versus 0.66 ± 0.02; p = 1). Additionally, no increase of SI on T2-weighted TSE images could be observed (0.66 ± 0.02 versus 0.62 ± 0.02; p = 0.89).

Discussion

The present study demonstrates (1) the feasibility of monitoring gadolinium-BOPTA uptake into the vessel wall during MR-guided paclitaxel/gadolinium-BOPTA-coated balloon angioplasty of the peripheral arteries and (2) that endovascular MR-guided interventions at a 3 Tesla MR scanner are feasible.

Drug-coated balloon angioplasty

Drug-eluting stents are currently widely used to prevent restenosis. However, there are a few limitations: First, if the vessel is too small, drug-eluting stents cannot be implanted. Second, late stent thrombosis can occur probably due to the use of polymeric matrix on the stents in which the antiproliferative drug is embedded. Third, the delivery of the drug to the arterial wall is not uniform and the drug concentration is highest at the stent struts. Recently, paclitaxel-coated balloons were developed to reduce restenosis [15]. Scheller et al. showed in an experimental study that most of the drug is released from the balloon after a 60-second dilatation and they could detect 10 – 15 % of the drug in the vessel wall even 40 – 60 minutes later [16]. No systemic bioavailability of paclitaxel was detected > 24 hours after PTA with a paclitaxel-coated balloon catheter [17]. Cell culture experiments also showed that the brief contact between vascular smooth cells and lipophilic taxane compounds is sufficient to inhibit proliferation of the cells for a long period [5, 6].

Initial clinical results show that using these coated balloon catheters during an angioplasty procedure keeps the vessels open wider over time, including peripheral arteries, compared to standard angioplasty and published reports of other current standard-of-care therapies [8, 15, 18]. However, it is of incremental importance to monitor successful uptake into the vessel wall because this therapy only works if drug uptake occurs. Monitoring of drug uptake is currently not possible under fluoroscopy guidance. The idea of monitoring potential therapeutic solutions under MR guidance has been demonstrated before [19, 20]. Saeed et al. could monitor the endomyocardial delivery of a gadodiamide-blue dye mixture into the endocardium and could then visualize gadolinium-enhanced regions on T1-weighted images [19]. Moreover, a recently published study demonstrated the MR-guided delivery of a contrast media doped solution to the vessel wall using a standard balloon catheter with multiple perforations on a 1.5 Tesla scanner [14]. Perforated balloon catheters have been described in the literature [21, 22]. However, coated balloons have achieved more acceptance over the years due to more homogenous drug distribution [7, 8, 18]. In contrast to microporous balloons, it is not necessary to inject the drug with a syringe when coated balloons are used.

In the present study we could show for the first time that gadolinium-BOPTA was applied into the paclitaxel drug matrix to generate a paclitaxel/gadolinium-BOPTA-coated angioplasty balloon in order to visualize the gadolinium-BOPTA uptake into the vessel wall by acquiring a T1-weighted GE sequence. We observed a homogenous increase of signal intensity within the vessel wall after coated angioplasty. The signal of the vessel wall is highest directly after vessel dilatation due to the MR contrast agent and decreases over time. Lederman et al. observed a similar kinetic after endomyocardial injection using gadolinium-DTPA [20]. The distribution of gadolinium-BOPTA has also been observed in the vessel wall [23].

MR-guided endovascular intervention

The feasibility of MR-guided peripheral vascular interventions has been demonstrated before, even in humans [9 – 11, 13]. MR-guided interventions have the advantage of avoiding the use of iodinated contrast agents and ionizing radiation. Moreover, besides real-time guidance during the intervention, MRI provides information about the vessel wall and plaque stability as well as functional parameters [24]. Most interventional MR studies are performed on a 1.5 Tesla MR scanner. However, vessel wall imaging benefits from a higher field strength and achieves a higher signal-to-noise ratio. We therefore chose a 3 Tesla system for the procedure. We implemented an SSFP real-time imaging sequence for 3 Tesla, which had sufficient spatial and temporal resolution for optimal guidance of the procedure. We did not have any problems with susceptibility artifacts. Despite using a commercial guidewire, the placement of the coated balloon catheter was optimal. Even in animals with stenosis, the balloon could be placed in the narrowed section of the vessels and the stenosis could be dilated successfully. For vessel wall imaging we used a high-resolution T1-weighted GE sequence and could optimally delineate the vessel wall. The material we used was MR conditional except the guidewire. To apply this procedure to humans, the use of MR conditional guidewires is required. A 0.035-inch passive MR guidewire has already been developed and preclinically tested [25]. In this study we used this commercial 0.014-inch guidewire to be compatible with the balloon catheter. However, the developed 0.035-inch MR guidewire has potential to be reduced in size in the near future.

Limitations

Our stenosis model differs from lipid and calcium-rich atherosclerotic human peripheral artery disease. Further studies need to be performed to evaluate the distribution of paclitaxel and gadolinium-BOPTA in an atherosclerosis model. As this study was designed as a pilot study, we did not conduct a follow-up. Gadolinium-BOPTA was not tagged to the paclitaxel. Therefore, we could only monitor the uptake of gadolinium-BOPTA into the vessel wall. However, this technique provides at least a therapy control of where the dilatation has been performed. This may be especially useful for cases where the underlying stenosis is hard to detect during intervention, for example in inflammatory lesions or acute occlusion with consecutive thrombosis of the complete vessel. Histological analysis of ELUTAX SV balloons in preclinical experiments could demonstrate a homogenous diffusion of paclitaxel into the vessel wall for up to 3 mm (personal communication/Aachen Resonance). However, whether the diffusion of gadolinium-BOPTA or paclitaxel occurs jointly or independently cannot ultimately be clarified by this experiment.

This document was downloaded for personal use only. Unauthorized distribution is strictly prohibited.

Conclusion

Monitoring uptake of gadolinium-BOPTA into the vessel wall during MR-coated balloon angioplasty of the iliac arteries on a 3 Tesla MR scanner is feasible. This is a first step towards providing a tool for the online control of homogenous drug delivery after paclitaxel-coated balloon angioplasty.

References

1 *Minar E, Pokrajac B, Maca T et al.* Endovascular brachytherapy for prophylaxis of restenosis after femoropopliteal angioplasty: results of a prospective randomized study. Circulation 2000; 102: 2694 – 2699
2 *Heuser L, Arnold CN, Morhard D et al.* DeGIR-Qualitätsreport 2011-Bericht über die Behandlungsqualität minimalinvasiver Methoden. Fortschr Röntgenstr 2012; 184: 570 – 576
3 *Iakovou I, Schmidt T, Bonizzoni E et al.* Incidence, predictors, and outcome of thrombosis after successful implantation of drug-eluting stents. JAMA: the journal of the American Medical Association 2005; 293: 2126 – 2130
4 *Mauri L, Hsieh WH, Massaro JM et al.* Stent thrombosis in randomized clinical trials of drug-eluting stents. The New England journal of medicine 2007; 356: 1020 – 1029
5 *Axel DI, Kunert W, Goggelmann C et al.* Paclitaxel inhibits arterial smooth muscle cell proliferation and migration in vitro and in vivo using local drug delivery. Circulation 1997; 96: 636 – 645
6 *Scheller B, Speck U, Romeike B et al.* Contrast media as carriers for local drug delivery. Successful inhibition of neointimal proliferation in the porcine coronary stent model. European heart journal 2003; 24: 1462 – 1467
7 *Scheller B, Hehrlein C, Bocksch W et al.* Treatment of coronary in-stent restenosis with a paclitaxel-coated balloon catheter. The New England journal of medicine 2006; 355: 2113 – 2124
8 *Tepe G, Zeller T, Albrecht T et al.* Local delivery of paclitaxel to inhibit restenosis during angioplasty of the leg. The New England journal of medicine 2008; 358: 689 – 699
9 *Buecker A, Adam GB, Neuerburg JM et al.* Simultaneous real-time visualization of the catheter tip and vascular anatomy for MR-guided PTA of iliac arteries in an animal model. Journal of magnetic resonance imaging: JMRI 2002; 16: 201 – 208
10 *Dick AJ, Raman VK, Raval AN et al.* Invasive human magnetic resonance imaging: feasibility during revascularization in a combined XMR suite. Catheterization and cardiovascular interventions. official journal of the Society for Cardiac Angiography & Interventions 2005; 64: 265 – 274
11 *Manke C, Nitz WR, Djavidani B et al.* MR imaging-guided stent placement in iliac arterial stenoses: a feasibility study. Radiology 2001; 219: 527 – 534
12 *Raval AN, Karmarkar PV, Guttman MA et al.* Real-time magnetic resonance imaging-guided endovascular recanalization of chronic total arterial occlusion in a swine model. Circulation 2006; 113: 1101 – 1107
13 *Yang X, Atalar E.* Intravascular MR imaging-guided balloon angioplasty with an MR imaging guide wire: feasibility study in rabbits. Radiology 2000; 217: 501 – 506
14 *Krombach GA, Wehner M, Perez-Bouza A et al.* Magnetic resonance-guided angioplasty with delivery of contrast-media doped solutions to the vessel wall: an experimental study in swine. Investigative radiology 2008; 43: 530 – 537
15 *Scheller B, Speck U, Abramjuk C et al.* Paclitaxel balloon coating, a novel method for prevention and therapy of restenosis. Circulation 2004; 110: 810 – 814
16 *Scheller B, Speck U, Schmitt A et al.* Addition of paclitaxel to contrast media prevents restenosis after coronary stent implantation. Journal of the American College of Cardiology 2003; 42: 1415 – 1420
17 *Freyhardt P, Zeller T, Kroncke TJ et al.* Plasma levels following application of paclitaxel-coated balloon catheters in patients with stenotic or occluded femoropopliteal arteries. Fortschr Röntgenstr 2011; 183: 448 – 455
18 *Unverdorben M, Vallbracht C, Cremers B et al.* Paclitaxel-coated balloon catheter versus paclitaxel-coated stent for the treatment of coronary in-stent restenosis. Circulation 2009; 119: 2986 – 2994
19 *Saeed M, Lee R, Martin A et al.* Transendocardial delivery of extracellular myocardial markers by using combination X-ray/MR fluoroscopic guidance: feasibility study in dogs. Radiology 2004; 231: 689 – 696
20 *Lederman RJ, Guttman MA, Peters DC et al.* Catheter-based endomyocardial injection with real-time magnetic resonance imaging. Circulation 2002; 105: 1282 – 1284
21 *Herdeg C, Oberhoff M, Baumbach A et al.* Local drug delivery with porous balloons in the rabbit: assessment of vascular injury for an improvement of application parameters. Catheterization and cardiovascular diagnosis 1997; 41: 308 – 314
22 *Oberhoff M, Kunert W, Herdeg C et al.* Inhibition of smooth muscle cell proliferation after local drug delivery of the antimitotic drug paclitaxel using a porous balloon catheter. Basic research in cardiology 2001; 96: 275 – 282
23 *Kerwin WS, Zhao X, Yuan C et al.* Contrast-enhanced MRI of carotid atherosclerosis: dependence on contrast agent. Journal of magnetic resonance imaging: JMRI 2009; 30: 35 – 40
24 *Hayashi K, Mani V, Nemade A et al.* Comparison of 3D-diffusion-prepared segmented steady-state free precession and 2D fast spin echo imaging of femoral artery atherosclerosis. The international journal of cardiovascular imaging 2010; 26: 309 – 321
25 *Kramer NA, Kruger S, Schmitz S et al.* Preclinical evaluation of a novel fiber compound MR guidewire in vivo. Investigative radiology 2009; 44: 390 – 397

This document was downloaded for personal use only. Unauthorized distribution is strictly prohibited.